ILD CASEBOOK

間質性肺病 案例集

ILD CASEBOOK

Table of Content

Prologue **02**

The 2018 ATS/ERS/JRS/ALAT Clinical Practice Guideline for the Diagnosis of Idiopathic Pulmonary Fibrosis **07**

I.IPF Clinical Course and Treatment **12**

- Comprehensive and Individualized Patient Care in Idiopathic Pulmonary Fibrosis 13
- Rapidly Progressive Idiopathic Pulmonary Fibrosis Treated with Nintedanib 25
- Concomitant Pulmonary Tuberculosis in Idiopathic Pulmonary Fibrosis 35

II. Differential Diagnosis of IPF **42**

- Systemic Sclerosis-associated Interstitial Lung Disease (SSc-ILD) 43
- Rheumatoid Arthritis-associated Interstitial Lung Disease (RA-ILD) 51
- Respiratory Bronchiolitis-associated Interstitial Lung Disease (RB-ILD) 57
- Polymyositis/ Dermatomyositis-associated Interstitial Lung Disease 67
- Pulmonary Alveolar Proteinosis 73
- Lymphangioleiomyomatosis (LAM) 80
- Pulmonary Langerhans Cell Histiocytosis Associated with Severe Pulmonary Arterial Hypertension 90
- Hypersensitivity Pneumonitis/ Acute Hypersensitivity Pneumonitis 100
- Pleuroparenchymal Fibroelastosis 107

Interstitial lung diseases (ILDs) form a large and heterogeneous group of lung disorders characterized by primary involvement of the lung interstitium. Idiopathic pulmonary fibrosis (IPF) is the most common and life-threatening type of ILD.

As a groundbreaking change in the therapeutic landscape for IPF, recently introduced antifibrotic agents were found to be effective in slowing down disease progression. Accordingly, they have become the standard of care for IPF worldwide and have highlighted the importance of an early diagnosis.

In 2018, experts from four major international respiratory societies—the American Thoracic Society (ATS), the European Respiratory Society (ERS), the Japanese Respiratory Society (JRS), and the Latin American Thoracic Society (ALAT)—developed a new international guideline to help physicians to make right diagnosis of IPF. The most important refinement included the use of four diagnostic categories based on high-resolution tomography (HRCT) findings in the lungs: usual interstitial pneumonia (UIP) pattern, probable UIP pattern, indeterminate pattern, and alternative diagnosis.

In addition, the experts have suggested the importance of multidisciplinary discussion (MDD) for diagnostic decision-making in cases of newly detected ILD with an apparently unknown cause who are clinically suspected to have IPF.

The Taiwan Society of Pulmonary and Critical Care Medicine has collected and documented 12 case studies to help the members of MDD, including pulmonologists, radiologists, and rheumatologists, update their concepts regarding the differential diagnosis of IPF and other ILDs. The clinical course and management of IPF under different conditions are also described in this casebook.

I herein express my sincere thanks to all physicians from our society who made efforts in writing and composition of this book. I do believe this book will be a prestigious and valuable one.

Meng-Chih Lin，MD

President of the Taiwan Society of Pulmonary and Critical Care Medicine

Professor, Division of Pulmonary and Critical Care Medicine, Kaohsiung Chang Gung Memorial Hospital, Kaohsiung, Taiwan

Imaging techniques, including chest radiography and high-resolution computed tomography (HRCT), represent an essential component of the diagnostic process for interstitial lung disease (ILD). Imaging techniques are noninvasive and provide insights into the diagnosis as well as prognosis, with serial imaging studies having the potential to assess disease progression.

Chest radiography findings are frequently the initial indicators of ILD, and comparisons of radiographs taken at different time points can show the rate of disease progression. However, radiography provides limited specificity and sensitivity and is primarily used to rule out other diseases such as left heart failure, bronchopneumonia, etc. HRCT is a more sensitive method and crucial for the diagnosis of ILD. Abnormalities observed on HRCT can help in identifying specific ILDs.

Patients with idiopathic pulmonary fibrosis (IPF) and other fibrosing ILDs with a progressive phenotype may share a number of similar clinical features. The different radiographic and CT patterns, particularly for IPF and other ILDs with a progressive fibrosing phenotype, are described in more detail in this casebook, which will aid junior pulmonologists and radiologists in establishing an accurate diagnosis more easily.

Professor Yeun-Chung Chang

President of The Radiological Society
Republic of China

Interstitial lung disease (ILD) is a term that broadly describes a diverse collection of more than 200 lung disorders. These diseases are classified together because they all affect the tissue and space around the alveoli, known as the interstitium.

For example, idiopathic pulmonary fibrosis (IPF) is a progressive and fatal lung disease with a median survival time of 3 to 5 years after diagnosis. Novel antifibrotic agents have been shown to slow down the progression of the disease, thus highlighting the importance of an early diagnosis. However, despite best efforts to facilitate a diagnostic work-up, early identification of the disease remains an unmet goal.

Hypersensitivity pneumonitis (HP) is caused by repeated and/or intense inhalation of and subsequent sensitization to organic dusts or occupational agents in predisposed subjects. Although the prognosis of chronic HP (cHP) is generally better than that of IPF, a certain amount of disease progression has been demonstrated in these patients. Moreover, the mortality risk is not negligible.

Rheumatoid arthritis (RA) is frequently associated with ILD. Lung involvement during the course of RA (RA-ILD) is a clinical challenge because of the unpredictable clinical course and lack of an easy and widely accepted survival prediction tool. Other autoimmune-related ILD, such as systemic sclerosis-associated ILD (SSc-ILD), pulmonary alveolar proteinosis (PAP), and polymyositis/dermatomyositis (PM/DM)-related ILD, will also be described in this casebook.

We hope that this casebook summarizing different cases of fibrosing ILDs capture the interest of the readers and strengthen multidisciplinary team networking with regard to these conditions.

Professor Chi-Wei Tao

Chief Editor of the ILD casebook

The 2018 ATS/ERS/JRS/ALAT Clinical Practice Guideline for the Diagnosis of Idiopathic Pulmonary Fibrosis

The new evidence-based guidelines of 2018 provided the diagnostic criteria for idiopathic pulmonary fibrosis (IPF) on the basis of radiological and histological findings, according to revisions of the diagnostic recommendations of the 2011 guideline. This guideline is intended to help clinicians make an accurate diagnosis of IPF. Here, we list the major differences of the diagnostic recommendations between the two versions.

	2018 Guidelines		2011 Guidelines No distinction among patients with variable HRCT patterns
	HRCT Pattern for Probable UIP*, Indeterminate UIP, and Alternative Diagnosis	HRCT Pattern for UIP*	
BAL cellular analysis	We suggest performing a BAL cellular analysis (conditional)	We suggest NOT performing a BAL cellular analysis (conditional)	"BAL cellular analysis should not be performed in the diagnostic evaluation of IPF in the majority of patients, but may be appropriate in a minority of patients."
Surgical lung biopsy	We suggest performing a surgical lung biopsy (conditional)	We recommend NOT performing a surgical lung biopsy (strong)	"Surgical lung biopsy is not required for patients with an HRCT pattern consistent with UIP."
Transbronchial lung biopsy	No recommendation was made on the use transbronchial lung biopsy	We recommend NOT performing a transbronchial lung biopsy (strong)	"Transbronchial biopsy should not be used in the evaluation of IPF in the majority of patients, but may be appropriate in a minority."
Lung cryobiopsy	No recommendation was made on the use of cryobiopsy	We recommend NOT performing a cryobiopsy (strong)	Not addressed

	2018 Guidelines		2011 Guidelines No distinction among patients with variable HRCT patterns
	HRCT Pattern for Probable UIP*, Indeterminate UIP, and Alternative Diagnosis	HRCT Pattern for UIP*	
Medical history of medication use and environmental exposures	We recommend taking a detailed history of medication use and environmental exposures at home, work, and other places frequented by the patient, to exclude potential causes of ILD (motherhood statement)		"Diagnosis of IPF requires exclusion of other known causes of ILD (e.g., domestic and occupational environmental exposures, connective tissue disease, and drug toxicity)."
Serological testing to exclude connective tissue diseases	We recommend serological testing to exclude connective tissue diseases as a potential cause of the ILD (motherhood statement)		"Diagnosis of IPF requires exclusion of other known causes of ILD (e.g., domestic and occupational environmental exposures, connective tissue disease, and drug toxicity)."
Multidisciplinary discussion	We suggest the implementation of multi-disciplinary discussion for decision-making (conditional)		"We recommend that a multidisciplinary discussion should be used in the evaluation of IPF."multidisciplinary discussion should be used in the evaluation of IPF.
Serum biomarkers	We recommend NOT measuring serum biomarkers; MMP-7, SPD, CCL-18, or KL-6 for the differential diagnosis of IPF from other ILDs (strong)		Not addressed

Definition of abbreviations: ALAT= Latin American Thoracic Society; ATS =American Thoracic Society; CCL-18 = chemokine ligand 18; ERS = European Respiratory Society; HRCT = high-resolution computed tomography; ILD = interstitial lung disease; IPF= idiopathic pulmonary fibrosis; JRS = Japanese Respiratory Society; KL-6= Krebs von den Lungen-6; MMP-7 = matrix metalloproteinase 7; SPD = surfactant protein D; UIP=usual interstitial pneumonia.

The quality of evidence for all recommendations in the 2018 guideline was very low.

* The pattern of UIP in 2018 guideline has been revised. HRCT features frequently seen in UIP include honeycombing, traction bronchiectasis, and traction bronchiolectasis, concurrently occurring with ground-glass opacification and fine reticulation. The histopathological features observed in UIP include dense fibrosis with architectural distortion (i.e., destructive scarring and/or honeycombing), subpleural and/or paraseptal distribution, patchy involvement, fibroblast foci, and an absence of features to suggest an alternate diagnosis.

High-Resolution Computed Tomography Scanning Patterns

UIP	Probable UIP
Subpleural and basal predominant; distribution is often heterogeneous*	Subpleural and basal predominant; distribution is often heterogeneous*
Honeycombing with or without peripheral traction bronchiectasis or bronchiolectasis†	Reticular pattern with peripheral traction bronchiectasis or bronchiolectasis
	May have mild GGO

Definition of abbreviations: CT = computed tomography; CTD = connective tissue disease; GGO = ground-glass opacities; RA = rheumatoid arthritis;UIP = usual interstitial pneumonia.

Indeterminate UIP	Alternative diagnosis
Subpleural and basal predominant Subtle reticulation (may have mild GGO or distortion) CT features or distribution of lung fibrosis Do not suggest any specific etiology (truly indeterminate)	Findings suggestive of another diagnosis, including: • CT features ◦ Cysts ◦ Marked mosaic attenuation ◦ Predominant GGO ◦ Profuse micronodules ◦ Centrilobular nodules ◦ Nodules ◦ Consolidation • Predominant distribution ◦ Peribronchovascular ◦ Perilymphatic ◦ Upper or mid-lung • Other ◦ Pleural plaques (consider asbestosis) ◦ Dilated esophagus (consider CTD) ◦ Distal clavicular erosions (consider RA) ◦ Extensive lymph node ◦ enlargement (consider other etiologies) ◦ Pleural effusions, pleural thickening (consider CTD/drugs)

*Variants of distribution: occasionally diffuse, may be asymmetrical.
† Superimposed CT features: mild GGO, reticular pattern, pulmonary ossification.

I.IPF Clinical Course and Treatment

Comprehensive and Individualized Patient Care in Idiopathic Pulmonary Fibrosis

Long-Term Follow-Up After AntiFibrotic Therapy

Dr. Pin-Kuei Fu

Department of Critical Care Medicine,
Taichung Veterans General Hospital,
Taichung, Taiwan

Clinical pearls

- Idiopathic pulmonary fibrosis (IPF) is characterized by dyspnea on exertion due to progressive fibrotic changes in the lung parenchyma and the loss of lung function, which eventually progresses to respiratory failure[1]. The mean survival period is 2–5 years from the diagnosis[2].
- Long-term treatment for IPF includes pharmacological as well as nonpharmacological therapies. Nonpharmacological management strategies include smoking cessation, vaccination against influenza and pneumococcal infections, oxygen therapy for patients with a peripheral capillary oxygen saturation (SpO_2) of <88% on room air, or pulmonary rehabilitation[3].
- Lung transplantation can prolong survival and improve the quality of life in very selected candidates; however, only a minority of patients receive a transplant[4].
- Currently, only two medications, namely nintedanib and pirfenidone, have been approved for the treatment of IPF. They slow down the rate of decline in the forced vital capacity (FVC) by approximately 50% over the course of 1 year and lower the rates of acute exacerbations and mortality[5-8].
- An open-label extension study from the TOMORROW trial showed that long-term treatment with nintedanib in patients with IPF slowed down the decline in lung function beyond 52 weeks[9].
- In that study, the adjusted annual rate of decline in FVC was -125.4 mL/year [95% confidence interval (CI): -168.1 to -82.7]

with nintedanib treatment and -189.7 mL/year (95% CI: -229.8 to -149.6) with placebo. The proportion of patients with one or more acute exacerbations was 12.9% and 25.9% in the nintedanib and placebo groups, respectively[9].

- Common comorbidities associated with IPF include emphysema, obstructive sleep apnea, lung cancer, pulmonary hypertension, infection, and cardiovascular disease[10,11].
- Comprehensive and individualized patient care in IPF should include nonpharmacological therapy, antifibrotic therapy and management of side effects, referral for lung transplantation, and management of comorbidities.

Patient profile

Case presentation

- 67-year-old man
- A factory worker living in central Taiwan
- Progressive dyspnea on exertion since 3 years

Medical history

- Hepatitis C, with regular follow-up
- Gastroesophageal reflux disease treated with a proton pump inhibitor
- Allergic rhinitis
- Smoked one pack per day for more than 30 years, quit since more than 10 years
- No pets
- No alcohol consumption
- Unremarkable family history

Physical examination

- Heart rate: 76 bpm, regular heart beats
- SpO_2: 96% under ambient air
- Bibasilar crackles on auscultation
- Local tenderness over the left maxillary sinus
- No edema in the legs

Laboratory panels

- Normal CBC and biochemistry
- Autoimmune profiles:
  - ANA = Negative (Positive: ≥ 1:160),
  - SSA = Negative (0.5 EliA U/ml, Positive: >10 EliA U/ml)
  - SSB = Negative (0.3 EliA U/ml, Positive: >10 EliA U/ml)
  - Scl-70 Ab = Negative (<0.6 EliA U/ml, Positive: >10 EliA U/ml)
  - Jo-1 Ab = Negative (<0.3 EliA U/ml, Positive: >10 EliA U/ml)
  - RF (blood) = Negative (<14 IU/ml)
- Negative results in bacterial, mycobacterial, and fungal cultures

Pulmonary function test findings (April 11, 2016)

Parameter	Value
FVC	2.18 L (67% of predicted)
FEV_1	1.82 L (70% of predicted)
FEV_1/FVC	84%
$FEV_{25\%-75\%}$	82% predicted
TLC	55% predicted
D_{LCO}	74% predicted

***Conclusion*:** Moderate decrease in TLC and mild decrease in D_{LCO}

Radiological imaging studies

Figure 1: Chest radiography findings

Diffuse cystic lesions and a reticular pattern over the bilateral lung fields

Figure 2a-2c: High-resolution computed tomography

Honeycomb-like cysts and traction bronchiectasis over the bilateral posterior basal lung fields

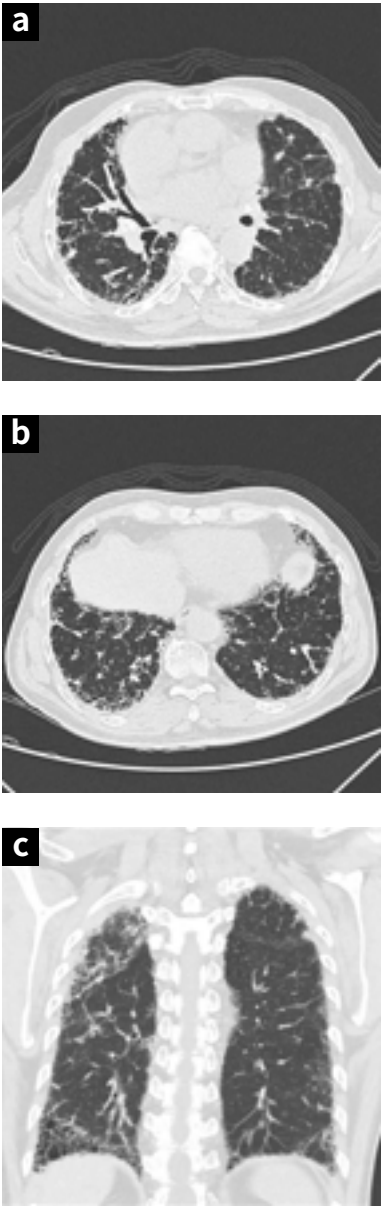

Figure 3a-3b: CT of the paranasal sinuses

The images show left maxillary sinusitis.

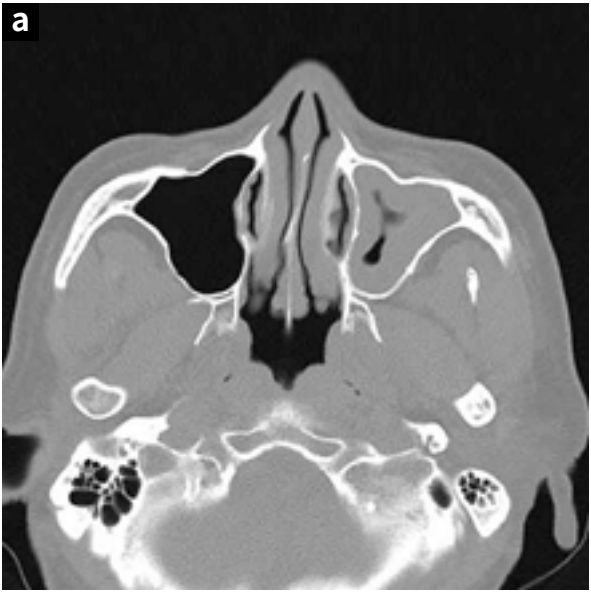

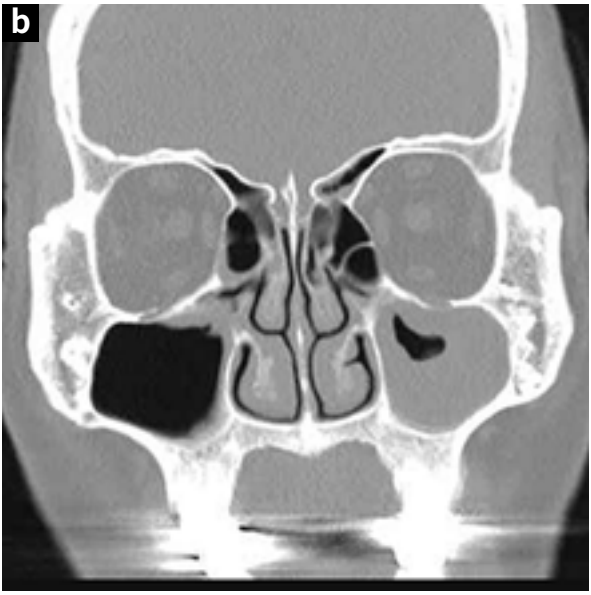

Figure 4 Lung function decline after nintedanib treatment in a patient with idiopathic pulmonary fibrosis

The annual forced vital capacity (FVC) decline after nintedanib treatment for 2.5 years is 124 mL/year.

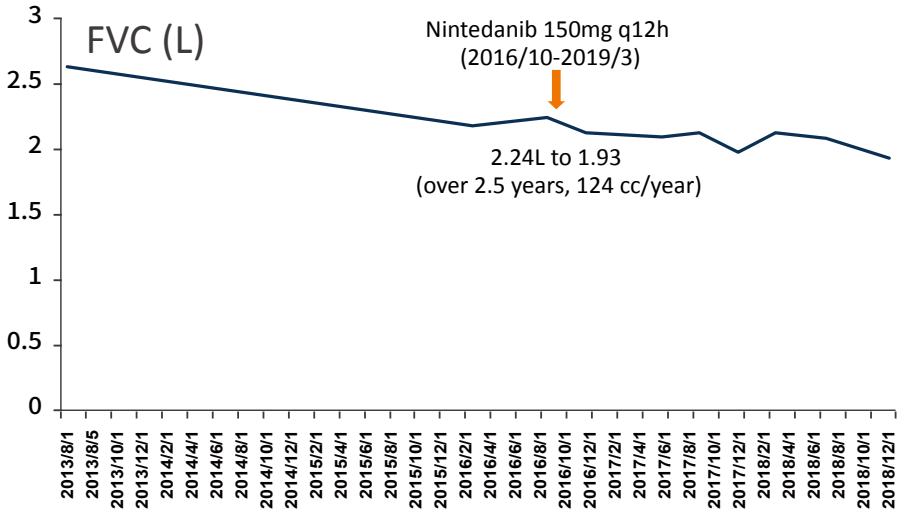

Figure 5. Long-term follow-up strategy according to the severity and stage of idiopathic pulmonary fibrosis

(Richeldi L, Collard HR, Jones MG; Lancet. 2017[2])

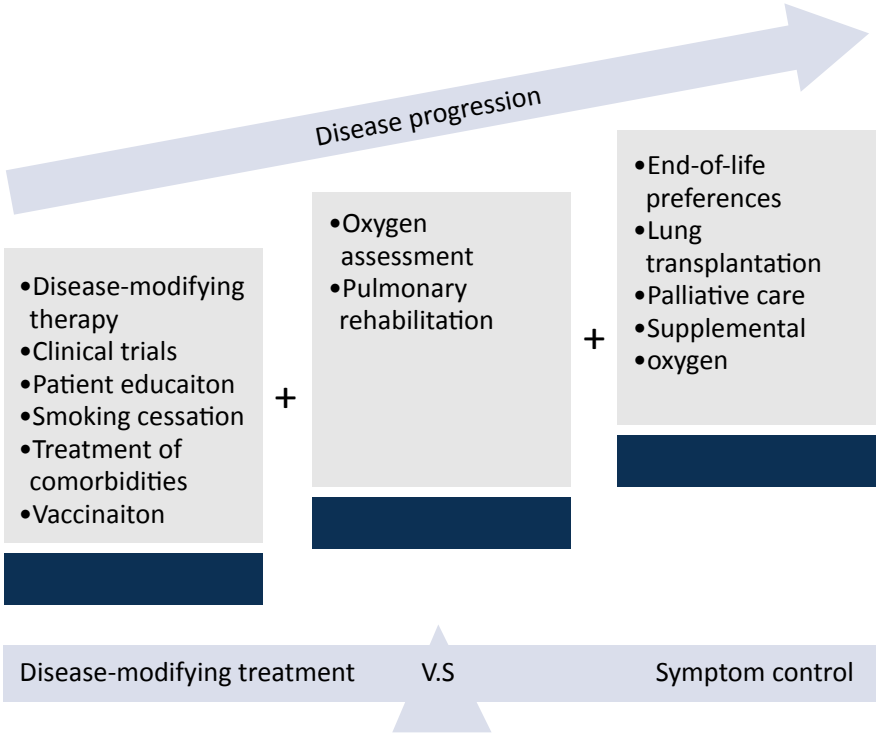

Pulmonary function test findings and care plan (serial follow-up)

Date	FVC (L)	FVC (%)	FEV_1 (L)	FEV_1 (%)	D_{LCO} (%)
2013.08	2.63	77	2.25	82	n/a
· Progressive dyspnea					
2016.04	2.18	67	1.82	70	74
· Vaccination against Pneumococcus (PCV-13) · Dual bronchodilator therapy					
2016.10	2.24	68	1.94	72	68
Initiation of nintedanib treatment (150 mg q12h) in October 2016					
2017.01	2.12	64	1.82	69	76
· Management of side effects, namely diarrhea and liver function impairment					
2017.07	2.09	65	1.90	74	n/a
2017.10	2.12	67	2.00	74	80
· Surgery for left maxillary sinusitis					
2018.01	1.98	62	1.72	68	58
· Pulmonary rehabilitation					
2018.04	2.12	67	1.76	70	n/a
2018.08	2.08	66	1.75	70	72
2019.01	1.93	62	1.73	69	n/a
· Influenza infection with mild decline in lung function					

Abbreviations

ILD, interstitial lung disease; IPF, idiopathic pulmonary fibrosis; FVC, forced vital capacity; CI, confidence interval; SpO_2, peripheral capillary oxygen saturation

References

1. *Lederer DJ, Martinez FJ. Idiopathic Pulmonary Fibrosis. N Engl J Med 2018; 378:1811-23.*
2. *Richeldi L, Collard HR, Jones MG. Idiopathic pulmonary fibrosis. Lancet 2017; 389:1941-1952.*
3. *Raghu G, Remy-Jardin M, Myers JL, et al. Diagnosis of Idiopathic Pulmonary Fibrosis. An Official ATS/ERS/JRS/ALAT Clinical Practice Guideline. Am J Respir Crit Care Med 2018; 198:e44-68.*
4. *Singer JP, Katz PP, Soong A, et al. Effect of Lung Transplantation on Health-Related Quality of Life in the Era of the Lung Allocation Score: A U.S. Prospective Cohort Study. Am J Transplant 2017; 17:1334-45.*
5. *Richeldi L, Cottin V, du Bois RM, et al. Nintedanib in patients with idiopathic pulmonary fibrosis: Combined evidence from the TOMORROW and INPULSIS® trials. Respir Med 2016; 113:74-9.*
6. *Costabel U, Inoue Y, Richeldi L, et al. Efficacy of Nintedanib in Idiopathic Pulmonary Fibrosis across Prespecified Subgroups in INPULSIS. Am J Respir Crit Care Med 2016; 193:178-85.*
7. *Nathan SD, Albera C, Bradford WZ, et al. Effect of pirfenidone on mortality: pooled analyses and meta-analyses of clinical trials in idiopathic pulmonary fibrosis. Lancet Respir Med 2017; 5:33-41.*
8. *Ley B, Swigris J, Day BM, et al. Pirfenidone Reduces Respiratory-related Hospitalizations in Idiopathic Pulmonary Fibrosis. Am J Respir Crit Care Med 2017; 196:756-61.*
9. *Richeldi L, Kreuter M, Selman M, et al. Long-term treatment of patients with idiopathic pulmonary fibrosis with nintedanib: results from the TOMORROW trial and its open-label extension. Thorax 2018; 73:581-3.*
10. *Buendia-Roldan I, Mejia M, Navarro C, Selman M. Idiopathic pulmonary fibrosis: Clinical behavior and aging associated comorbidities. Respir Med 2017; 129:46-52.*
11. *Kreuter M, Ehlers-Tenenbaum S, Palmowski K, et al. Impact of Comorbidities on Mortality in Patients with Idiopathic Pulmonary Fibrosis. PLoS One 2016; 11:e0151425.*

Rapidly Progressive Idiopathic Pulmonary Fibrosis Treated with Nintedanib

Management of atypical idiopathic pulmonary fibrosis with rapid progression

Dr. Yen-Kun Ko

Department of Chest Medicine & Respiratory Therapy, Sijhih Cathay General Hospital, Taiwan

Clinical pearls

- Idiopathic pulmonary fibrosis (IPF) is an unpredictable, progressive, and ultimately fatal lung disease characterized by the presence of cough and dyspnea and impaired quality of life.
- A usual interstitial pneumonia (UIP) pattern characterized by subpleural reticular abnormalities with basal predominance and honeycombing with or without traction bronchiectasis may be seen on high-resolution computed tomography.
- Surgical lung biopsy may be useful for further disease confirmation, although the risk is high in elderly patients and patients with severe IPF.
- Once the diagnosis is confirmed, treatment should be immediately initiated to slow down disease progression via a reduction in the decline in lung function. However, some patient subgroups have also shown an improvement or the absence of a decline in FVC after treatment.

Patient profile

Case presentation

- 62-year-old man
- smoking history of one packet per day for 30 years, nonsmoker since 6 months
- Progressive dry cough and dyspnea since 1 year
- Diagnosed with ILD at a regional hospital (treated for 6 months)
- Decline of 300 mL in FVC over a period of 6 months
- Lung biopsy recommended

Medical history(treated for the past 6 months)

- Prednisolone 5 mg qd–tid
- Allegra qd
- Aminophylline 100 mg tid
- Klaricid qd
- Ranitidine bid
- Regrow bid
- Seretide (250) two puffs bid

Physical examination

- SpO_2: 94% under ambient air (2017/3/9)
- Bibasilar fine crackles on auscultation
- No clubbing of fingers
- No leg edema

Laboratory panels

- Normal CBC and biochemistry results
- c-ANCA: negative, p-ANCA: negative
- ANA: 40X (NEG)
- RA: <10 IU/ml
- Anti-ENA SSA-A(R0): <0.2 AI, Anti-ENA SSA-A 52: <0.2 AI, Anti-ENA SSA-A 60: <0.2 AI, Anti-ENA SSA-B(La): <0.2 AI, Anti-ENA Sm: <0.2 AI, Anti-ENA Scl-70: <0.2 AI, Anti-ENA Jo-1: <0.2 AI
- Acid-fast staining of sputum: negative
- CRP: 0.828 (<1)
- Total IgE: 189 (<87)

Pulmonary function tests

Parameter	2016/8/1	2017/3/9
FVC (L)	2.1	1.8
FVC (% predicted)	62	53.3
FEV_1 (L)	1.83	1.61
FEV_1 (% predicted)	68.3	60.1
FEV_1/FVC ratio (%)	87	89.4
D_{LCO}	3.81	failure
D_{LCO} (% predicted)	48.4	failure
Total lung capacity (L)	3.15	failure
SpO_2 (Room air): %	96	94

Conclusion

- Rapid decline in FVC with reduced DL_{CO}
- Initiation of antifibrotic therapy recommended
- Initiation of nintedanib 150 mg q12h since 2017/4/25

Radiological imaging studies

Figure 1: Chest radiography findings

A chest radiograph reveals lung lesions r/o malignancy with peribronchial thickening, fibrotic changes, and traction bronchiectasis in both lungs, predominantly in the peripheral and lower lung fields. The findings are suggestive of idiopathic pulmonary fibrosis.

Figure 2a-2d: High-resolution computed tomography (2017/03)

Peribronchial thickening, fibrotic changes, and traction bronchiectasis can be seen in both lungs, predominantly in the peripheral and lower lung fields.

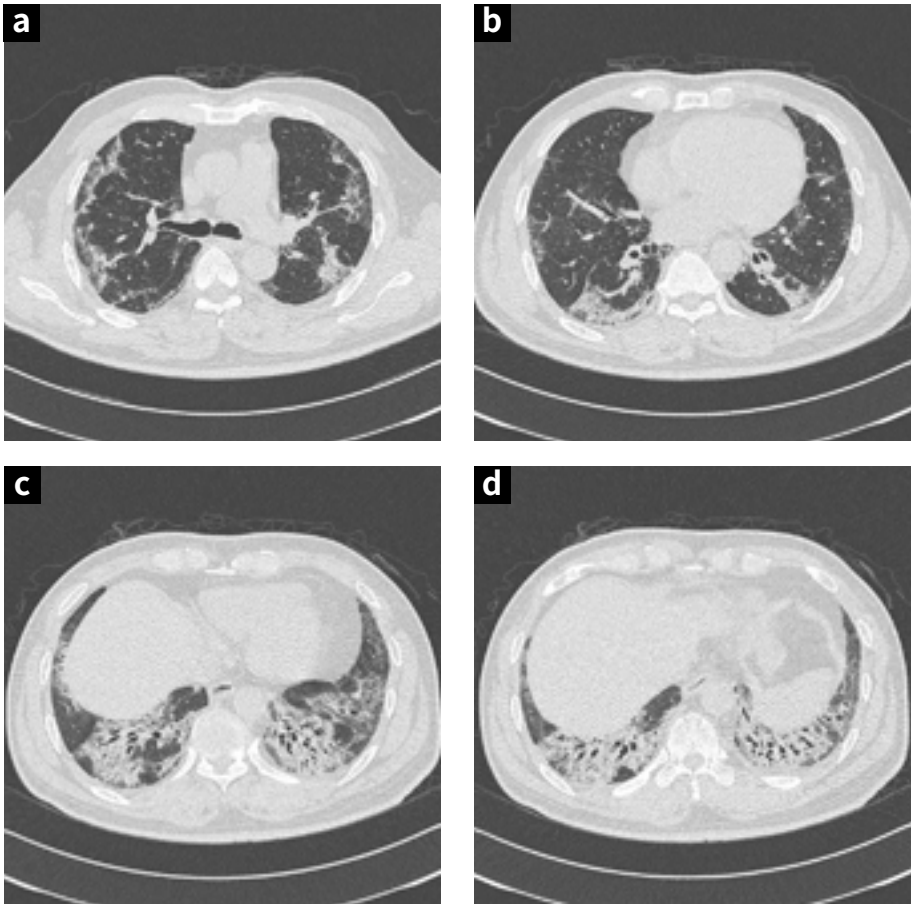

Figure 3a-3b: Pathology

- Patchy fibrosis with subpleural distribution and minimal interstitial inflammation throughout the lung.
- Spatial variegation with areas of prominent interstitial fibrosis adjacent to normal lung parenchyma, fibroblastic foci (*), and bronchiectasis are also noted.

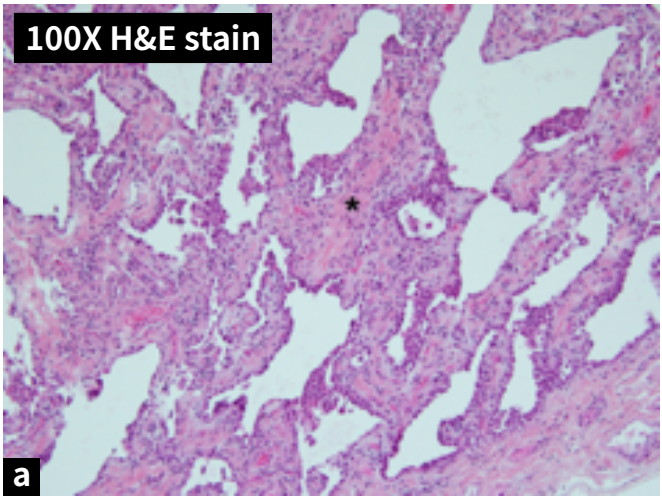

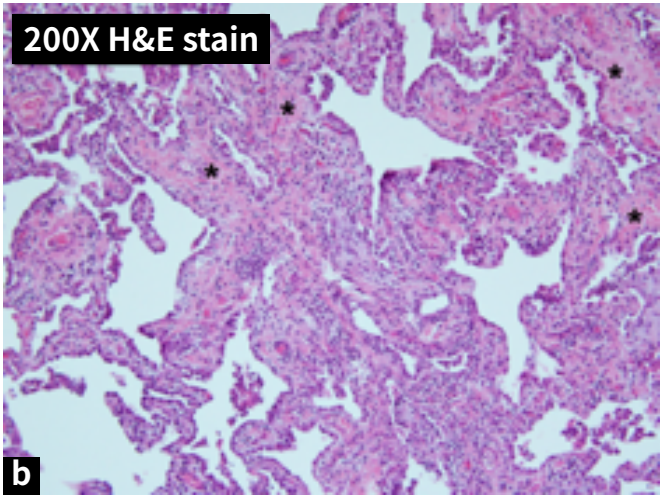

Pulmonary function tests (Serial follow-ups)

Parameter	Before nintedanib		After nintedanib	
	2016/8/1	2017/3/9	2017/9/26	2018/6/19
FVC (L)	2.1	1.8	1.98	2.34
FVC (% predicted)	62	53.3	59.9	69
FEV_1 (L)	1.83	1.61	1.91	2.0
FEV_1 (% predicted)	68.3	60.1	68.2	75
FEV1/FVC ratio (%)	87	89.4	91.4	85.8
D_{LCO}	3.81	failure	2.62	3.24
D_{LCO} (% predicted)	48.4	failure	33.5	41.2
Total lung capacity (L)	3.15	failure	3.08	3.43

Discussion

- The goal of treatment for IPF is to slow down disease progression via reduction of the decline in lung function. In the INPULSIS trials, some patients (158/638; 24.8%) who received nintedanib showed an improvement or the absence of a decline in FVC. The improvement in FVC at week 52 was 76.5 mL. However, the mechanisms underlying the improvement in FVC in patients treated with nintedanib remain unknown.
- In conclusion, we presented a case of pathologically diagnosed IPF with a rapid decline in lung function (decreased FVC: 43 mL/m) that exhibited symptom alleviation and lung function improvement (increased FVC: 39 mL/m) after nintedanib treatment.

Abbreviations

IPF: idiopathic pulmonary fibrosis, UIP: usual interstitial pneumonia, MDD: multidisciplinary discussion

References

1. *Raghu G, Richeldi L. Current approaches to the management of idiopathic pulmonary fibrosis. Respir Med 2017; 129: 24–30.*
2. *Yagihashi K, Huckleberry J, Colby TV, et al. Radiologic-pathologic discordance in biopsy-proven usual interstitial pneumonia. Eur Respir J 2016; 47: 1189–1197.*
3. *Flaherty KR, Kolb M, Vancheri C, Tang W, Conoscenti CS, Richeldi L. Stability or improvement in forced vital capacity with nintedanib in patients with idiopathic pulmonary fibrosis. Eur Respir J 2018; 52. pii: 1702593.*

Concomitant Pulmonary Tuberculosis in Idiopathic Pulmonary Fibrosis

Diagnosis and treatment of pulmonary tuberculosis in IPF patients

Jia-Yih Feng[1,2]

[1]Department of Chest Medicine, Taipei
[2]Veterans General Hospital, Taipei, Taiwan

Clinical pearls

- Infection, particularly viral infection, is one of the possible triggers in the pathogenesis of IPF
- Some observational studies have suggested the possible association between IPF and viral infection
- TGF-β, one of the key mediators in the pathogenesis of IPF, may suppress immune responses and enhance pathogenic invasion.
- It is difficult to differentiate acute exacerbation of IPF from pulmonary infection in IPF patients with rapid progression of pulmonary infiltrates
- It remains unknown if infection increases the risk of acute exacerbation of IPF

Patient profile

Case presentation

- 95-year-old male
- Occupational history: retired veteran
- Chronic cough with sputum noted in recent 2 years

Medical history

- Coronary artery disease with double vessel disease
- ST-elevation myocardial infarction, s/p percutaneous coronary intervention 4 years ago
- Chronic kidney disease, stage 3
- Ex-smoker, 1 PPD for 30 years, quit for 26 years
- Has no pets
- Unremarkable family history

Physical examination

- Heart rate: 106 bpm
- SpO_2: 92% in ambient air
- Bibasilar crackles on auscultation
- Clubbing of the fingers (-)
- No pedal edema,
- No arthralgia, no skin rashes

Laboratory panels

- Normal CBC and biochemistry
- ANA: 1:160+ (nucleolar)
- Negative RF, SSA/SSB/Scl-70/Jo-1, normal C3 and C4
- Sputum AFS: 2+, TB PCR+, TB culture: MTB complex

Pulmonary function tests

Parameter	2016/8/1
FVC	65% predicted
FEV_1	99% predicted
FEV_1/FVC	90%
FEF25–75%	78%
TLC	80% predicted
D_{LCO}	33% predicted
SpO_2 (Room air): %	96

Conclusion: Moderate reduction of FVC and severe reduction of D_{LCO}

Radiological imaging studies

Figure 1a-1b (Chest X-ray): Chest radiography findings

Chest plain film in April 2013(Figure 1a)

- Minimally increased infiltrates over bilateral basal lung fields

Chest plain film in September 2017(Figure 1b)

- Linear reticular infiltration over bilateral lung fields
- Basal and peripheral lung fields predominantly
- More severe in the right lower lung field

Figure 2a-2d: High-Resolution Computed Tomography

UIP pattern, with

- Bilateral interlobular septal thickening and honeycombing in the typical apico-postero-basal gradient
- Typical distribution with basal and subpleural predominance
- Traction bronchiectasis
- Consolidation in the superior segment of the lower lobe of the right lung

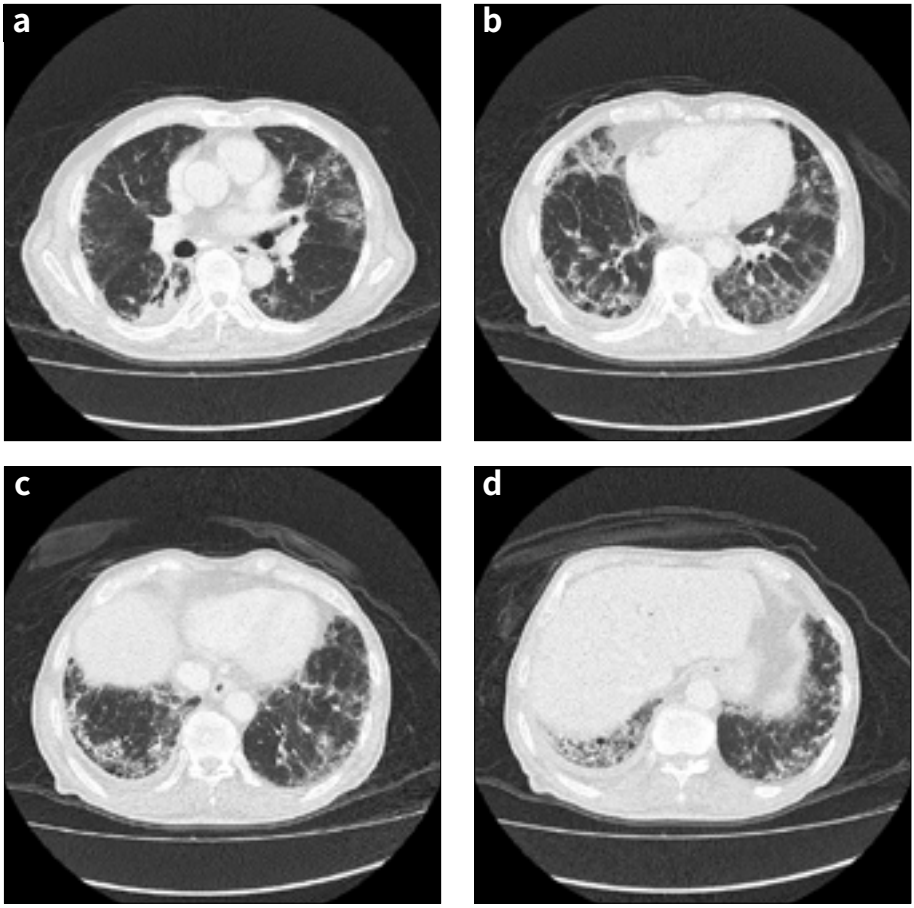

Pulmonary function test and care plan (Serial followed up)

Date	Status
2017/10	started anti-TB treatment with INH, RIF, EMB, PZ
2017/11	admission due to generalized skin rash after taking anti-TB medication • IgE: 801 • Favorable INH related, symptoms improved after holding INH
2017/11/14	initiated nintedanib treatment
2017/11/15	chest plain film showed rapid deterioration, suspicious IPF in AE or nosocomial infection
2017/11/20	sputum culture: Candida albicans, initiated micafungin treatment
2017/12	sputum TB culture conversion
2017/12	respiratory distress in progression, signed DNR, applied BiPAP
2018/01/06	Patient passed away

Abbreviations

IPF, idiopathic pulmonary fibrosis; TB, tuberculosis

References

1. *Moore BB, Moore TA. Viruses in Idiopathic Pulmonary Fibrosis. Etiology and Exacerbation. Ann Am Thorac Soc 2015;12: S186-S192.*
2. *Molyneaux PL, Cox MJ, Willis-Owen SA, et al. The role of bacteria in the pathogenesis and progression of idiopathic pulmonary fibrosis. Am J Respir Crit Care Med 2014; 190: 906–913.*
3. *Song JW, Hong SB, Lim CM, et al. Acute exacerbation of idiopathic pulmonary fibrosis: incidence, risk factors and outcome. Eur Respir J 2011; 37: 356–363.*
4. *Thomas BJ, Kan-O K, Loveland KL, et al. In the Shadow of Fibrosis: Innate Immune Suppression Mediated by Transforming Growth Factor-β. Am J Respir Cell Mol Biol 2016; 55: 759–766.*

II. Differential Diagnosis of IPF

Systemic Sclerosis-associated Interstitial Lung Disease (SSc-ILD)

Interstitial Lung Disease Associated with Systemic Sclerosis

Dr. Pin-Kuei Fu[1]; Dr. Jeng-Yuan Hsu[2]

[1]Department of Critical Care Medicine, Taichung Veterans General Hospital, Taichung, Taiwan

[2]General Clinical Research Center, Taichung Veterans General Hospital, Taichung, Taiwan

Clinical pearls

- In a study by the European Scleroderma Trials and Research group (EUSTAR), 53% and 35% of 3656 patients with systemic sclerosis (SSc) exhibited interstitial lung disease (ILD) with diffuse cutaneous SSc and limited SSc, respectively. [1]
- As many as 90% patients show interstitial abnormalities on high-resolution computed tomography (HRCT), while 40%–75% patients exhibit impairments in pulmonary function tests (PFTs). [2-3]
- Fibroblast activation can occur in response to a lung injury in patients with SSc. This results in destruction of the lung structure and abnormal functioning of the alveoli. [4]
- HRCT is mandatory for the diagnosis of ILD associated with SSc (SSc-ILD), and it is the most useful tool for the assessment of lung fibrosis in SSc. It not only determines the extent of the disease and the pattern of fibrosis but also confirms the presence or absence of extensive esophageal involvement. [5]
- The most frequent HRCT pattern is nonspecific interstitial pneumonia (NSIP); however, a usual interstitial pneumonia (UIP) pattern characterized by honeycombing and traction bronchiectasis may also be seen. Because the HRCT pattern is a good predictor of the underlying histopathology, a lung biopsy is generally not necessary.

Patient profile

Case presentation

- 60-year-old woman
- Housewife living in central Taiwan
- Intermittent dry cough and progressive dyspnea on exertion for the past 3 years

Medical history

- Scleroderma diagnosed at the age of 32
- Raynaud syndrome for more than 20 years
- Amputation of the third finger of the left hand because of gangrene (around 1996)
- Never smoker with no history of alcohol consumption or drug abuse
- No pets
- Unremarkable family history

Physical examination

- Heart rate: 96 bpm
- SpO_2: 92% under ambient air
- Bibasilar crackles on auscultation
- Left third finger s/p amputation
- Digital ulcers (+), sclerodactyly (+), telangiectasia (+)
- No leg edema
- No arthralgia
- No skin rashes

Laboratory panels

- Normal CBC and biochemistry
- Autoimmune profiles:
  - ANA = 1:160 (nucleoplasm, fine speckled)
  - Anti-RNA polymerase III Ab: Negative, <0.7 EliA U/ml
  - Anti-PM-Scl Ab: Negative, 0.9 EliA U/ml
  - anti-ENA and anti-CENP; normal C3 and C4
  - Myositis-specific Ab: TIF1 (+/-), borderline; PL-7 (+/-), borderline
- Negative bacterial, mycobacterial, and fungal culture results

Pulmonary function tests

Parameter	Value
FVC	69% predicted
FEV_1	75% predicted
FEV_1/FVC	89%
$FEV_{25\%–75\%}$	111% predicted
TLC	68% predicted
DL_{CO}	53% predicted

Conclusion: Moderate decrease in TLC and marked decrease in DL_{CO}

Radiological imaging studies

Figure 1: Chest radiography findings

Reticular infiltrates

- Equally distributed in both the lungs
- More at the lung periphery
- Predominant in the bilateral lower lung fields

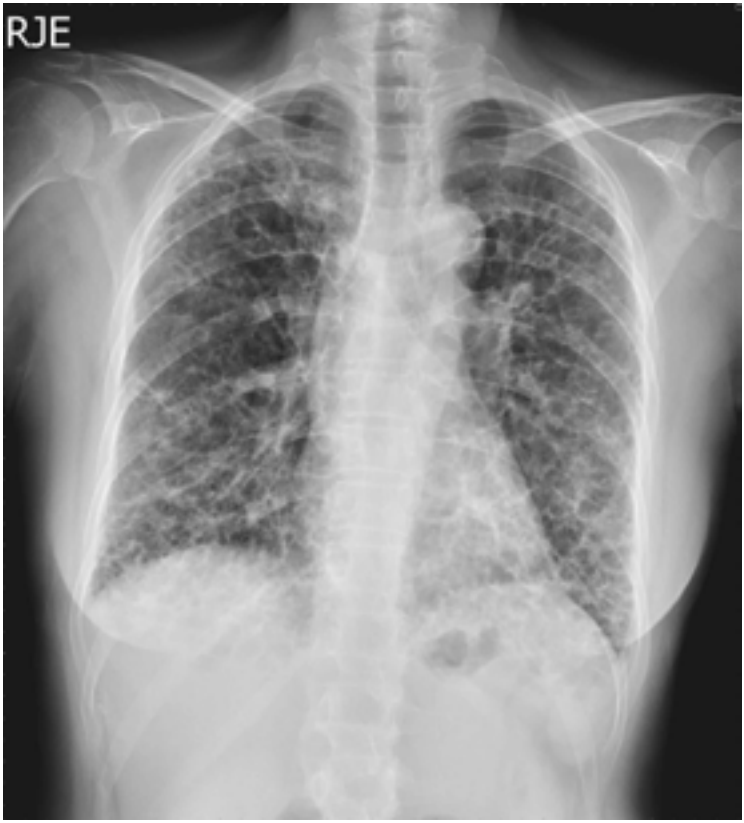

Figure 2a-2d: High-resolution computed tomography

A definitive usual interstitial pneumonia pattern with bilateral reticular thickening, traction bronchiectasis, and honeycombing in the typical apico-postero-basal gradient can be observed.

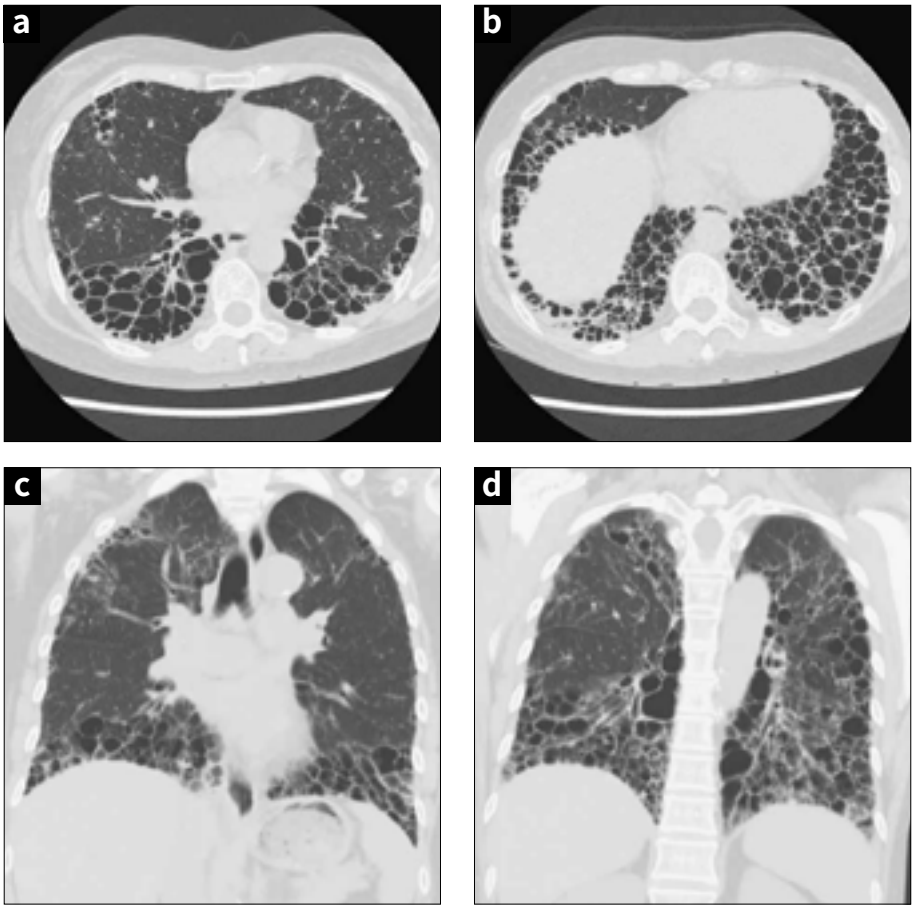

Reported pulmonary manifestations in specific connective tissue diseases[7]

	RA	SLE	SSc	SS	PM/DM
Airway involvement					
Upper airway	+	+			
Lower airway	+			+	
Pleural disease	+	+	Rare	Rare	
Vascular disease					
PH	+	+	+	Rare	Rare
Vasculitis/DAH	+	+	Rare		Rare
Thromboembolic disease		+			
Histopathological pattern					
UIP	+ (most)	+	+	+	+
NSIP	+	+ (most)	+ (most)	+ (most)	+
OP	+	+	+	+	+
DSIP	+	Rare			
DAD	+	+		+	+

Abbreviations

ILD: interstitial lung disease, SSc: systemic sclerosis, HRCT: high-resolution computed tomography, PFT: pulmonary function test, NSIP: nonspecific interstitial pneumonia, UIP: usual interstitial pneumonia,RA: rheumatoid arthritis, SLE: systemic lupus erythematosus, SSc: systemic sclerosis, SS: Sjogren's syndrome, PM/DM: polymyositis/dermatomyositis, PH: pulmonary hypertension, DAH: diffuse alveolar hemorrhage, UIP: usual interstitial pneumonia, NSIP: nonspecific interstitial pneumonia, OP: organizing pneumonia, LIP: lymphocytic interstitial pneumonia, DSIP: desquamative interstitial pneumonia, DAD: diffuse alveolar damage

References

1. *Walker UA, Tyndall A, Czirják L, et al. Clinical risk assessment of organ manifestations in systemic sclerosis: a report from the EULAR Scleroderma Trials And Research group database. Ann Rheum Dis 2007; 66: 754–763.*
2. *Mouthon L, Berezné A, Brauner M, et al. Pneumopathie infiltrante diffuse de la sclerodermie systemique. Rev Mal Respir 2007; 24: 1035–1046.*
3. *Cappelli S, Bellando Randone S, Camiciottoli G, De Paulis A, Guiducci S, Matucci-Cerinic M. Interstitial lung disease in systemic sclerosis: where do we stand? Eur Respir Rev 2015 Sep; 24: 411–419.*
4. *Wells AU, Denton CP. Interstitial lung disease in connective tissue disease--mechanisms and management. Nat Rev Rheumatol 2014 Dec; 10: 728–739.*
5. *Takei R, Arita M, Kumagai S, et al. Radiographic fibrosis score predicts survival in systemic sclerosis-associated interstitial lung disease. Respirology 2018 Apr; 23: 385–391.*
6. *Desai SR, Veeraraghavan S, Hansell DM, et al. CT features of lung disease in patients with systemic sclerosis: comparison with idiopathic pulmonary fibrosis and nonspecific interstitial pneumonia. Radiology 2004; 232: 560–567.*
7. *Olson AL,Brown KK. Connective tissue disease-associated lung disease. Eur Respir Mon 2009; 46: 225–250.*

Rheumatoid Arthritis-associated Interstitial Lung Disease (RA-ILD)

A Case of Rheumatoid Arthritis with pulmonary manifestation – focus on interstitial lung disease

Dr.Chung-Jen Wang, MD[1]; Dr.Shih-Lung Cheng, MD, PhD[1]

[1]Department of Chest Medicine, Far Eastern Memorial Hospital,
New Taipei City, Taiwan

Clinical pearls

- Rheumatoid arthritis (RA) is the most common connective tissue disease (CTD), and interstitial lung diseases (ILD) can be found in 25% of RA patients.
- Risk factors include male gender, older age, history of cigarette smoking, high titers of rheumatoid factor and anti-cyclic citrullinated peptide (anti-CCP) levels. Rheumatoid arthritis-associated lung fibrosis is twice as common in men as in women, and the mean age of onset is about 50 years.
- The pulmonary function test usually shows restrictive ventilatory defect and impaired diffusion capacity of the lungs for carbon monoxide (DLco). Hypoxemia can be found at rest or on exercise.
- Chest radiograph shows nonspecific changes consistent with interstitial disease. The abnormalities are largely symmetric and basally predominant.
- The high-resolution computed tomography (HRCT) findings of RA-ILD are bilateral subpleural reticulation and honeycombing, ground-glass opacities, centrilobular branching lines and bronchial dilatation, and patchy areas of consolidation.

Patient profile

Case presentation

- 63-year-old male
- An elementary school teacher
- Dry cough for several years

Medical history

- Hypertension, treated with amlodipine 5 mg QD
- No history of tobacco and alcohol use
- Has no pets
- Unremarkable family history

Physical examination

- Heart rate: 98 beats per minute
- SpO_2: 94% in ambient air
- Bibasilar fine crackles on auscultation
- Clubbing of the fingers (-)
- No pedal edema
- No arthralgia; no skin rashes

Laboratory panels

- Normal CBC and biochemistry
- Positive RF, ANA, and anti-CCP
- Negative bacterial, mycobacterial, and fungal culture results

Pulmonary function tests

Parameter	Value
FVC	73.0% predicted
FEV_1	88.7% predicted
FEV_1/FVC	90.77%
$FEF_{25-75\%}$	127.1%
TLC	66.6% predicted
D_{LCO}	73.6% predicted

Conclusion: Moderate restrictive ventilatory defect and mild impairment of D_{LCO}.

Radiological imaging studies

Figure 1: Chest radiography findings

CXR shows bilateral fine reticular abnormality in the lower lung zones.

Figure 2a-2d: High-Resolution Computed Tomography

HRCT shows reticular thickening with cystic appearance in the right apical-anterior field. Subpleural opacities in the mid-lung have peripheral reticulation.

The lower zones show prominent peripheral reticular pattern and focal bronchiectasis with signet ring appearance.

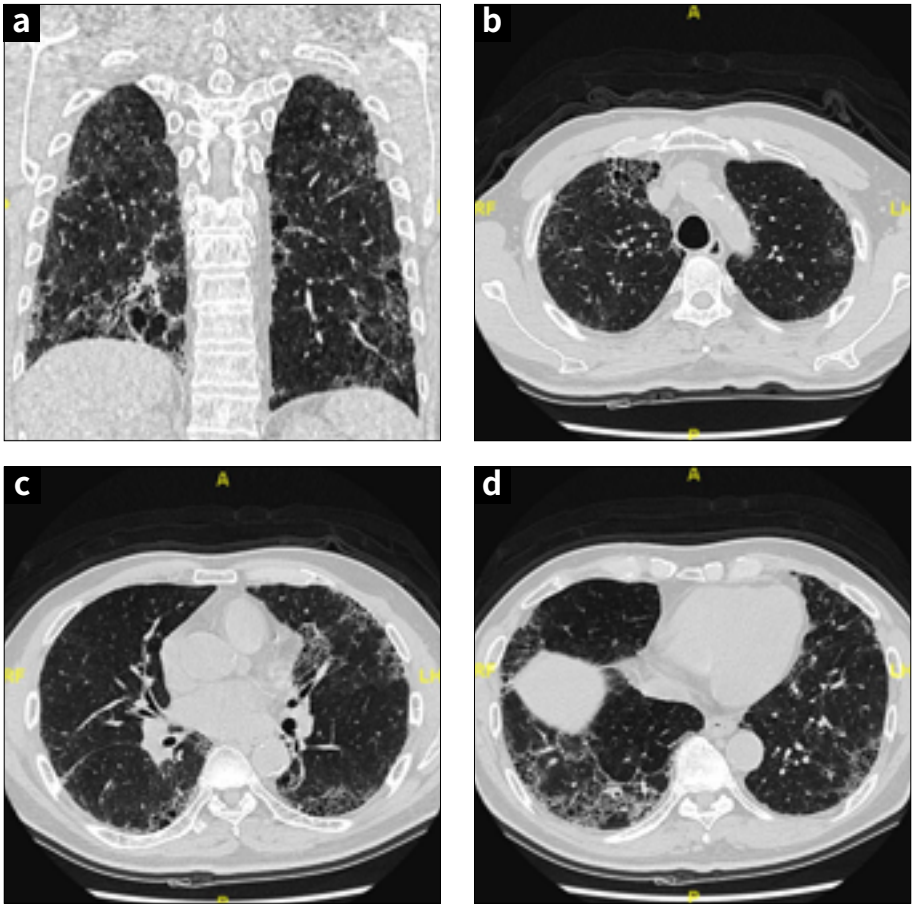

References

1. *McDonagh J, Greaves M, Wright AR, et al. High resolution computed tomography of the lungs in patients with rheumatoid arthritis and interstitial lung disease. Br J Rheumatol 1994; 33:118–122.*
2. *Kelly CA, Saravanan V, Nisar M, et al. Rheumatoid arthritis-related interstitial lung disease: associations, prognostic factors and physiological and radiological characteristics--a large multicentre UK study. Rheumatology (Oxford) 2014; 53: 1676–1682.*
3. *Kim EJ, Collard HR, King TE Jr. Rheumatoid arthritis-associated interstitial lung disease: the relevance of histopathologic and radiographic pattern. Chest 2009; 136: 1397–1405.*
4. *Locke GB. Rheumatoid lung. Clin Radiol 1963; 14: 43–53.*
5. *Tanaka N, Kim JS, Newell JD, et al. Rheumatoid arthritis-related lung diseases: CT findings. Radiology 2004; 232: 81–91.*

Respiratory Bronchiolitis-associated Interstitial Lung Disease (RB-ILD)

Dr. Mei-Yin Chen[1],Dr. Chi-Wei Tao[1], Dr. Cheng-Hsiang Hsiao[2]

[1]Department of Internal Medicine,
Cheng-Hsin General Hospital,
Taipei, Taiwan

[2]Department of Surgery,
Cheng-Hsin General Hospital,
Taipei, Taiwan

Clinical pearls

- Respiratory bronchiolitis-associated interstitial lung disease (RB-ILD) is a syndrome involving small airway inflammation in addition to interstitial lung disease and occurs in smokers.
- The clinical symptoms, including cough, dyspnea, presence of coarse rales on physical examination, are similar to those of other interstitial lung diseases. Fine, diffuse, interstitial reticulonodular opacities, with normal lung volumes, are found on chest radiograph. High-resolution computed tomography (HRCT) shows the presence of diffuse, fine, nodular ground-glass opacities and air trapping.
- Results of pulmonary function tests may appear normal but usually demonstrate mild to moderate restriction and normal to mild reduction in the diffusion capacity of the lungs for carbon monoxide (DLco). The manifestation of a mixed obstructive-restrictive pattern is common.
- Histologically, RB-ILD is characterized by the presence of patchy, non-uniform accumulation of finely pigmented, tan-brown macrophages within the membranous, terminal and respiratory bronchioles; in the surrounding alveoli; and occasionally, in the interstitial tissues. The histology is associated with mild interstitial fibrosis, which restricts itself to the peribronchiolar tissues.
- The management of RB-ILD involves smoking cessation and supportive care including supplemental oxygen, pulmonary rehabilitation, and administration of influenza and pneumococcal vaccines. Long-term prognosis is good following cessation of smoking, with or without adjunct corticosteroid therapy.

Patient profile

Case presentation

- 57-year-old man
- A government officer
- Productive cough, progressive dyspnea, weight loss, and generalized weakness since 1 month

Medical history

- Cigarette smoking: 1 pack per day (PPD) for 30 years, no alcohol or drug use
- Has no pets
- Unremarkable family history

Physical examination

- Heart rate: 98 bpm
- SpO_2: 92% under ambient air
- Bibasilar crackles on auscultation
- Presence of finger clubbing
- No edema of legs
- No arthralgia or skin rashes

Laboratory panels

- Normal CBC and biochemistry
- No autoantibodies against RF, ANA, anti-ENA, anti-ds DNA, anti-Ro, anti-La, anti-Sm, anti-RNP, and anti-Scl-70; normal C3 and C4 levels
- Negative results for bacterial, mycobacterial, and fungal culture

Pulmonary function tests

Parameter	Value
FVC	70% predicted
FEV_1	78% predicted
FEV_1/FVC	84%
$FEF_{25\%-75\%}$	98%
TLC	77% predicted
D_{LCO}	30% predicted

Conclusion

Mild restrictive ventilatory defect with severe reduction of D_{LCO}

Radiological imaging studies

Figure 1: Chest radiography findings

Reticular infiltrates

- Distributed equally at both lungs
- More at the lung periphery
- Without obvious discrepancy at the upper and lower lungs

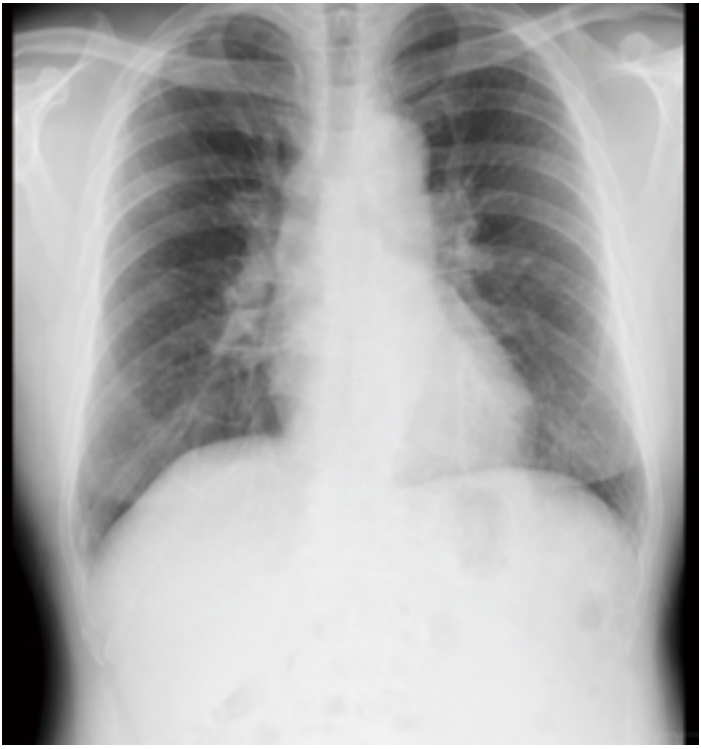

Figure 2a-2e: High-resolution computed tomography

Interlobular and interstitial thickening, bronchial wall thickening, and small reticular opacities were seen in the peripheral zone of both lungs. Patchy, ground glass opacities were seen in the peripheral zone of the lower lobes. The distribution in the upper and lower zones seems unaffected.

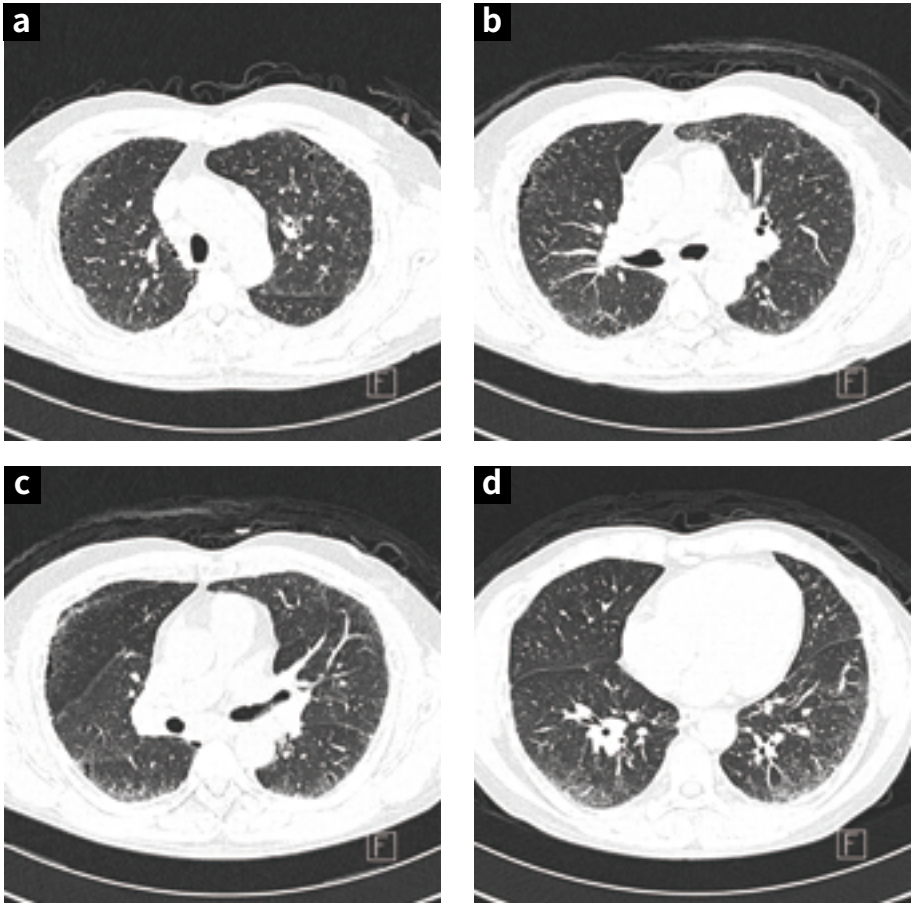

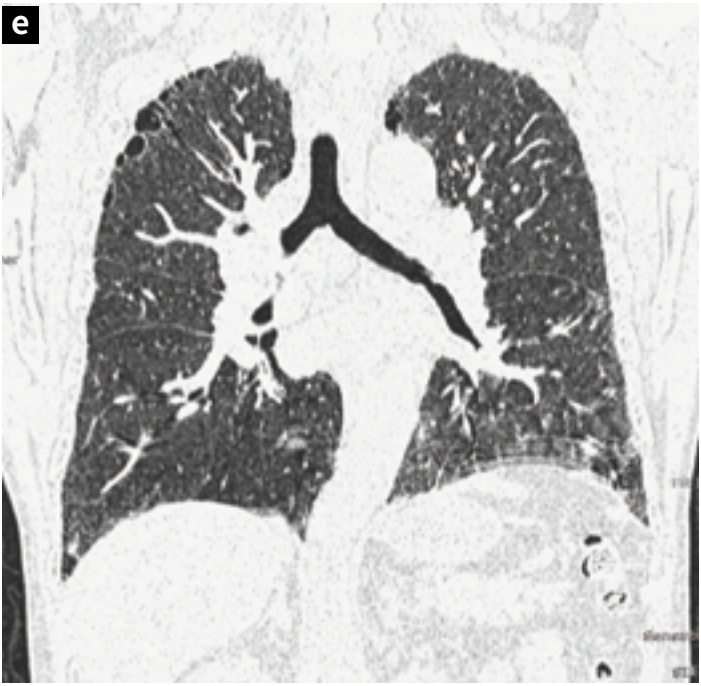

Diagnostic Procedure: Video-assisted thoracic surgery: right upper lobe (RUL) wedge resections

Figure 3a-3c: Pathology

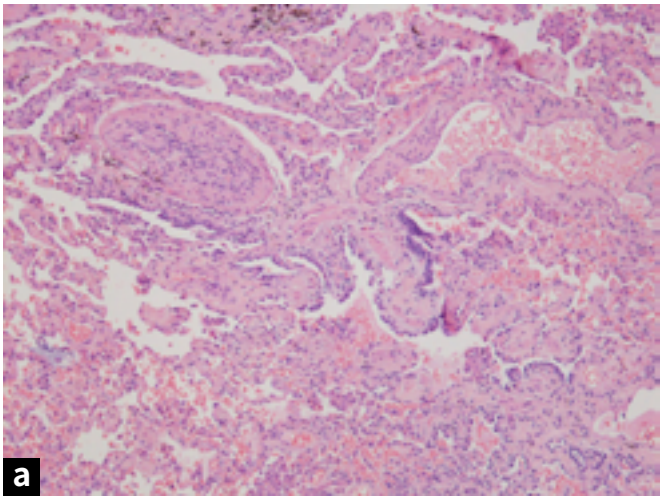

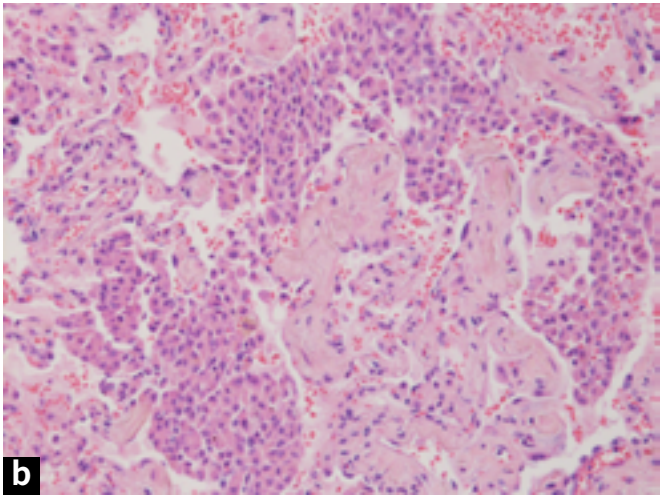

(a)Cuboidal cell metaplasia along the alveolar ducts and alveoli adjacent to the bronchioles.(b)Collections of pigmented macrophages in the alveolar spaces.

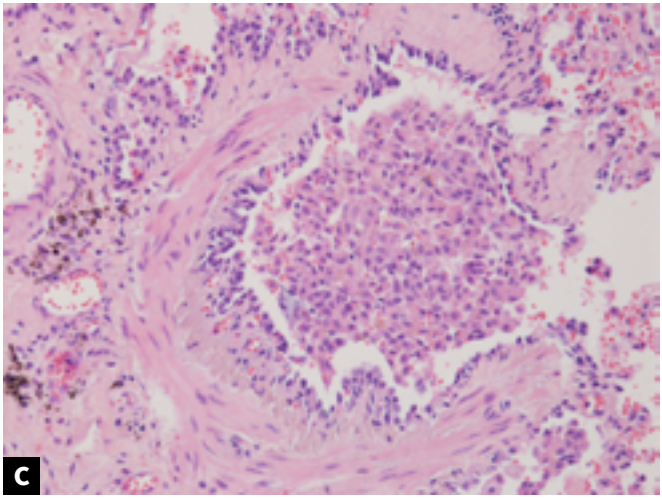

(c)Numerous pigmented macrophages in the lumen of the respiratory bronchiole.

Abbreviations

RB-ILD, respiratory bronchiolitis-associated interstitial lung disease; HRCT, high resolution computed tomography; DLco, diffusion capacity of the lungs for carbon monoxide

References

1. *Sieminska A, Kuziemski K. Respiratory bronchiolitis-interstitial lung disease. Orphanet J Rare Dis 2014; 9:106.*
2. *Nebor AE, Morris Z. Respiratory bronchiolitis-associated interstitial lung disease (rbild)/desquamative interstitial pneumonia (dip)- Presenting as cystic lung disease. Am J Respir Crit Care Med 2017; 195:A1528.*
3. *Churg A, Muller NL, Wright JL. Respiratory bronchiolitis/interstitial lung disease- fibrosis, pulmonary function, and evolving concepts. Arch Pathol Lab Med 2010; 134:27-32.*

Polymyositis/ Dermatomyositis-associated Interstitial Lung Disease

Dr. Ching-Min Tseng, Dr. Chi-Wei Tao

Division of Respiratory Therapy, Department of Internal Medicine, Cheng-Hsin General Hospital,
Taipei, Taiwan

Clinical pearls

- Patients with polymyositis/dermatomyositis (PM/DM) tend to develop interstitial lung disease (ILD), the primary cause of morbidity and mortality.
- Physical examination may reveal Gottron's sign, the characteristic feature of the disease.
- Imaging by high-resolution computed tomography (HRCT) commonly demonstrates bilateral, irregular, linear opacities involving the base of the lungs, with occasional presence of consolidation.
- Anti-Jo-1 antibody positivity is infrequent in the cases of DM with ILD (~38%).
- Synchronous malignancy is present in about 5.7% of the cases.

Patient profile

Case presentation

- 57-year-old woman
- A housewife
- Chronic productive cough since 3 years
- A worsening dyspnea in the recent half of the year

Medical history

- No known medical history
- No history of tobacco use or alcohol consumption
- Has no pets
- Unremarkable family history

Physical examination

- SpO_2: 95% under ambient air
- Bibasilar crackles on auscultation
- Presence of Gottron's sign, shawl sign, mechanic's hand, and periungual erythema.

Laboratory panels

- Normal CBC and biochemistry
- CPK 1254 IU/L, AST 142 IU/L
- Negative for anti-dsDNA, anti-SSA/SSB, anti-Scl-70 and RF autoantibodies

Pulmonary function tests

Parameter	Value
FVC	74% predicted
FEV_1	79% predicted
FEV_1/FVC	88%
TLC	65% predicted
D_{LCO}	52% predicted

Conclusion: Moderate restrictive ventilatory defect; moderate impairment of D_{LCO}

Radiological imaging studies

Figure 1: Chest radiography findings

CXR shows bilateral reticular abnormality at the bibasilar lung fields. Lower lung volume loss noted.

Figure 2a-2f: High-resolution computed tomography

HRCT shows bronchovascular consolidation and opacity spreading over both the lung fields. There is symmetrical thickening of the interlobular and the intralobular septa, at the subpleural regions of the bilateral lower lung, near the diaphragm, with traction bronchiectasis.

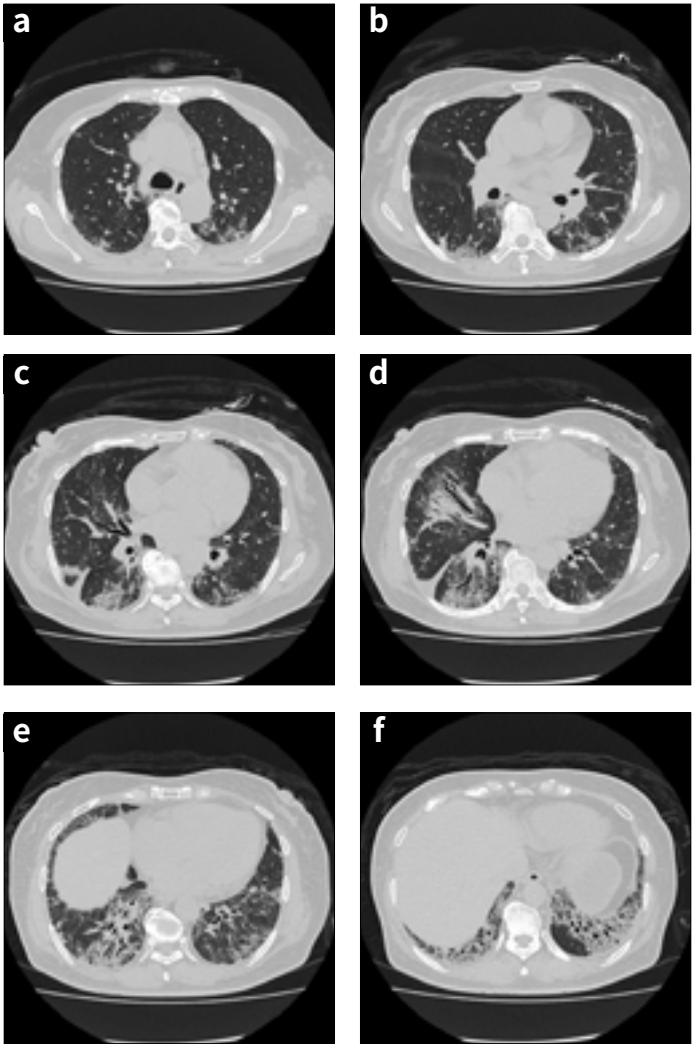

Abbreviations

PM, polymyositis; DM, dermatomyositis; ILD, interstitial lung disease; HRCT, high-resolution computed tomography

References

1. *Lundberg IE, Tjärlund A, Bottai M, et al. European League Against Rheumatism/American College of Rheumatology classification criteria for adult and juvenile idiopathic inflammatory myopathies and their major subgroups. Arthritis and Rheumatology 2017; 76:1955-64.*
2. *Takato H, Waseda Y, Watanabe S, et al. Pulmonary manifestations of anti-ARS antibody positive interstitial pneumonia with or without PM/DM. Respiratory Medicine 2013; 107:128-33*
3. *Fathi M, Lundberg IE, Tornling G. Pulmonary complications of polymyositis and dermatomyositis. Semin Respir Crit Care Med 2007; 28(4):451-8.*

Pulmonary Alveolar Proteinosis

Current therapy in pulmonary alveolar proteinosis

Dr. Chi-Tai Lee

Pulmonary Division, Internal Medicine, Far Eastern Memorial Hospital,
New Taipei City, Taiwan

Clinical pearls

- Pulmonary alveolar proteinosis (PAP) is a rare syndrome characterized by the accumulation of surfactant in alveolar macrophages and alveoli resulting in hypoxemic respiratory failure.
- PAP is caused by a spectrum of disorders that negatively affect the production and clearance of surfactant. Three main categories of PAP are recognized: (1) disruption of granulocyte-macrophage colony-stimulating factor (GM-CSF) signaling (autoimmune and hereditary PAP), (2) disorders of surfactant production (congenital PAP), and (3) underlying disorder secondarily affecting alveolar macrophages (secondary PAP).
- Common symptoms of PAP include exertional dyspnea, cough, fatigue, and weight loss.
- High resolution computed tomography (HRCT) shows ground-glass opacities (GGOs) in autoimmune, hereditary and secondary PAP.
- GGO presents as a patchy geographic pattern that is distributed in the lower lung fields in autoimmune PAP, whereas GGO typically presents as a diffuse pattern in secondary PAP. A "crazy-paving" appearance (GGO superimposed on septal thickening) and subpleural sparing are frequently seen in autoimmune PAP, but are less frequently apparent in secondary PAP.
- For patients with minimal or no symptoms, supportive care with supplemental oxygen, as needed, over more invasive therapy is preferred.

- For patients with moderate-to-severe dyspnea and hypoxemia due to autoimmune PAP, whole lung lavage (WLL) has been the standard first-line therapy.
- Recombinant GM-CSF inhalation therapy or subcutaneous injection may be an option for patients who cannot tolerate or have no response to whole lung lavage.
- Glucocorticoids are not indicated for autoimmune PAP.
- The roles of the anti-CD20 monoclonal antibody, rituximab and therapeutic plasma exchange have been investigated without a definite conclusion.
- Lung transplantation is reserved for patients with severe and refractory PAP.

Patient profile

Case presentation

- 68-year-old woman
- A retired operator of an electronics factory
- Intermittent dry cough and progressive dyspnea on exertion during the last three years
- Lost five kilograms of body weight concomitantly

Medical history(treated for the past 6 months)

- Asthma controlled with Symbicort
- HBV carrier managed with Baraclude and Luckyhepa
- Behçet's disease controlled with prednisolone
- Denied cigarette smoking history
- Denied occupational history of high-level dust exposure

Physical examination

- Body height: 146 cm, body weight: 43.6 kg
- BP: 142/89 mmHg
- BT: 36.5° C, PR: 75/min, RR: 18/min
- SpO_2: 95% in ambient air
- Bilateral lower lung fine crackles on auscultation
- No pedal edema

Laboratory panels

- Normal CBC and biochemistry
- Negative RF, ANA, Anti-Ro Ab or Anti-La Ab
- Negative bronchial lavage sputum culture (bacteria/TB/fungus)
- Total IgE: 189 (<87)

Radiological imaging studies

Figure 1: Chest radiography findings

- Bilateral symmetric alveolar opacities
- Located centrally in mid and lower lung zones
- Asymmetric, unilateral, or nodular patterns may be present

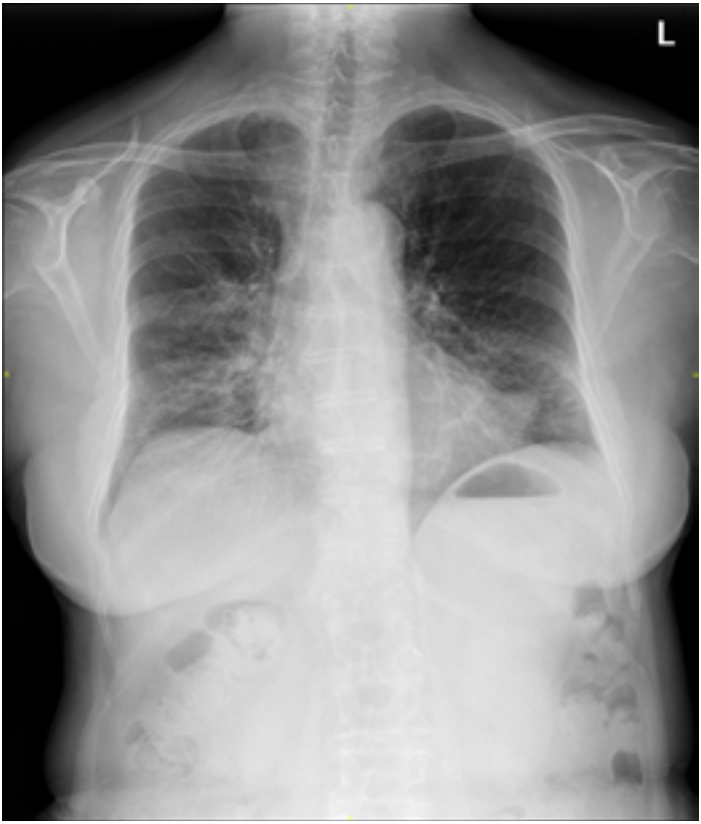

Figure 2a-2d: High-resolution computed tomography

PAP pattern, with

- Ground-glass opacities present as a patchy geographic pattern that is distributed in the mid and lower lung fields
- "Crazy paving"appearance (ground-glass opacities superimposed on septal thickening)

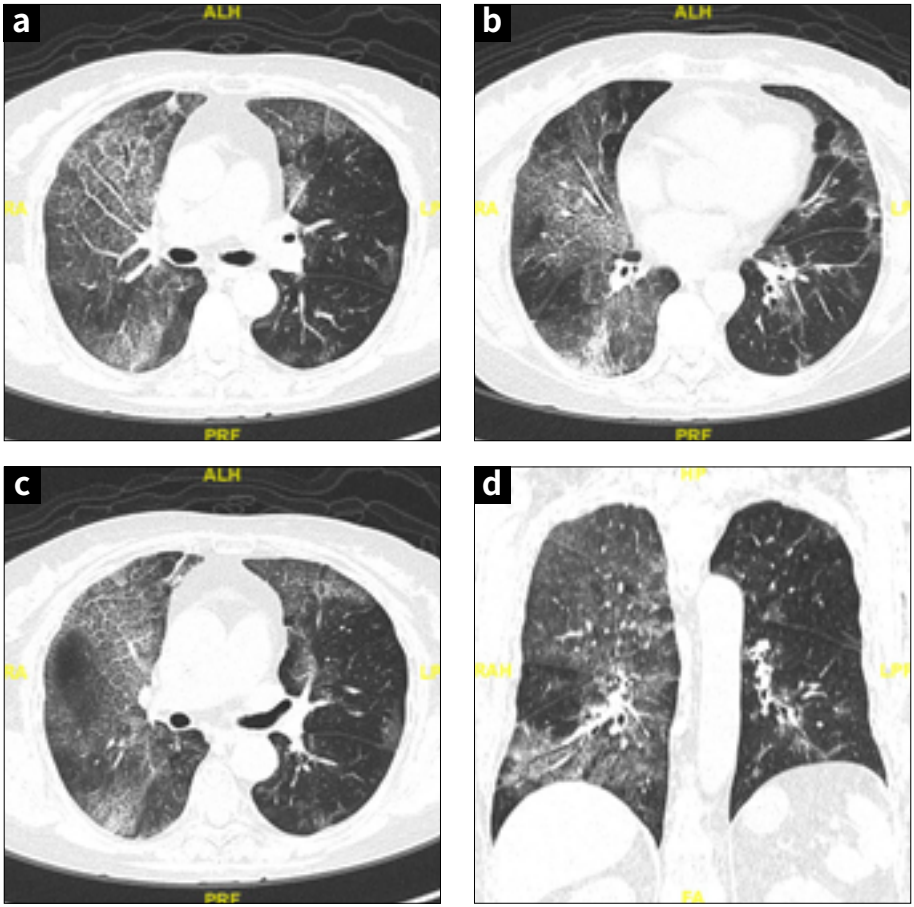

References

1. *Malur A, Kavuru MS, Marshall I, et al. Rituximab therapy in pulmonary alveolar proteinosis improves alveolar macrophage lipid homeostasis. Respir Res 2012; 13: 46.*
2. *Miyazaki T, Tagawa T, Yamasaki N, Tsuchiya T, Matsumoto K, Nagayasu T. Two case reports of successful withdrawal of mycofenolate mofetil after living donor lobar lung transplantation. Transplant Proc 2013; 45: 356–359.*
3. *Garber B, Albores J, Wang T, et al. A plasmapheresis protocol for refractory pulmonary alveolar proteinosis. Lung 2015; 193: 209–211.*
4. *Suzuki T, Trapnell BC. Pulmonary Alveolar Proteinosis Syndrome. Clin Chest Med 2016; 37: 431–440.*
5. *Griese M. Pulmonary Alveolar Proteinosis: A Comprehensive Clinical Perspective. Pediatrics 2017; 140: e20170610.*
6. *Raju S, Ghosh S, Mehta AC. Chest CT Signs in Pulmonary Disease: A Pictorial Review. Chest 2017; 151: 1356–1374.*

Lymphangioleio-myomatosis (LAM)

Dr. Hui Wang, Dr. Shih-Lung Cheng

Department of Internal Medicine, Far Eastern Memorial Hospital,
Taipei,Taiwan

Clinical pearls

- Lymphangioleiomyomatosis (LAM) is a rare, multi-system, slowly progressive disease that can occur sporadically or in association with tuberous sclerosis. The estimated incidence of this disease is 1:400,000.
- LAM almost exclusively affects women of child-bearing age, with the mean age at the onset of symptoms being in the early to mid-30s.
- Patients usually present with chest pain, exertional dyspnea, and recurrent episodes of pneumothorax; however, chylothorax, hemoptysis, or incidentally detected pulmonary cysts may also be found.
- Transbronchial biopsy, pleural fluid cytology, and surgical tissue pathology may aid in the diagnosis of LAM. These examinations reveal proliferation of abnormal smooth muscle-like cells (LAM cells) that leads to the formation of lung cysts, fluid-filled cystic structures in the axial lymphatics, and angiomyolipomas.
- The differential diagnoses of LAM include pulmonary Langerhans' histiocytosis (PLCH), Birt-Hogg-Dubé syndrome (BHD), lymphoid interstitial pneumonia (LIP), and amyloidosis.
- Although the clinical course of LAM is highly variable, it is generally progresses slowly. The 10-year survival rate is 80% to 90% and the median survival time is 30 years after the onset of symptoms.
- Sirolimus can be considered for patients with abnormal lung function, rapid decline in FEV_1 or DL_{CO}, recurrence after lung transplant, or chylous complications. Patients who require oxygen therapy have worse outcomes.

Patient profile

Case presentation

- 37-year-old woman
- Occupation: secretary
- Backache in progression in the morning of Sep 18, 2014
- Sent for MER therapy, presented with tachycardia, acute respiratory distress, and then asystole status post cardiopulmonary resuscitation (CPR)

Medical history(treated for the past 6 months)

- Denied major systemic disease,
- No smoking history
- Unremarkable family history of inheritable disease

Physical examination

- Height: 15 8cm; weight: 45 kg (body mass index (BMI): 18kg/m^2)
- SpO_2: 99% under ventilator support
- Bilateral coarse breathing sound under bilateral chest tubes
- Skin: No rash. Presented with bilateral subcutaneous emphysema

Laboratory panels

- Normal complete blood count (CBC) and biochemistry data
- Negative bacterial and mycobacterial culture

Treatment Course

- Surgical intervention with pleurodesis and video assisted thoracic surgery (VATS) for wedge resection of the lungs was performed.
- Pathology report:
  - Bullae formation and chronic inflammation microscopically.
  - Proliferation of plump eosinophilic spindle cells in fascicles along the septa and perivascular spaces were noted.
  - Immunohistochemical staining was positive for HMB-45, ER, and actin (focal).
  - Pathological impression: Lymphangioleiomyomatosis.
- The patient was extubated after initial treatment, and then discharged after 14 hospital days without any respiratory distress or complications.

Radiological imaging studies

Figure 1: Chest radiography in 2014

The anteroposterior (AP) chest radiograph after return of spontaneous circulation (ROSC) shows bilateral significant pneumothorax. The lung parenchyma shows interstitial infiltrate

Figure 2a-2d: Chest CT findings

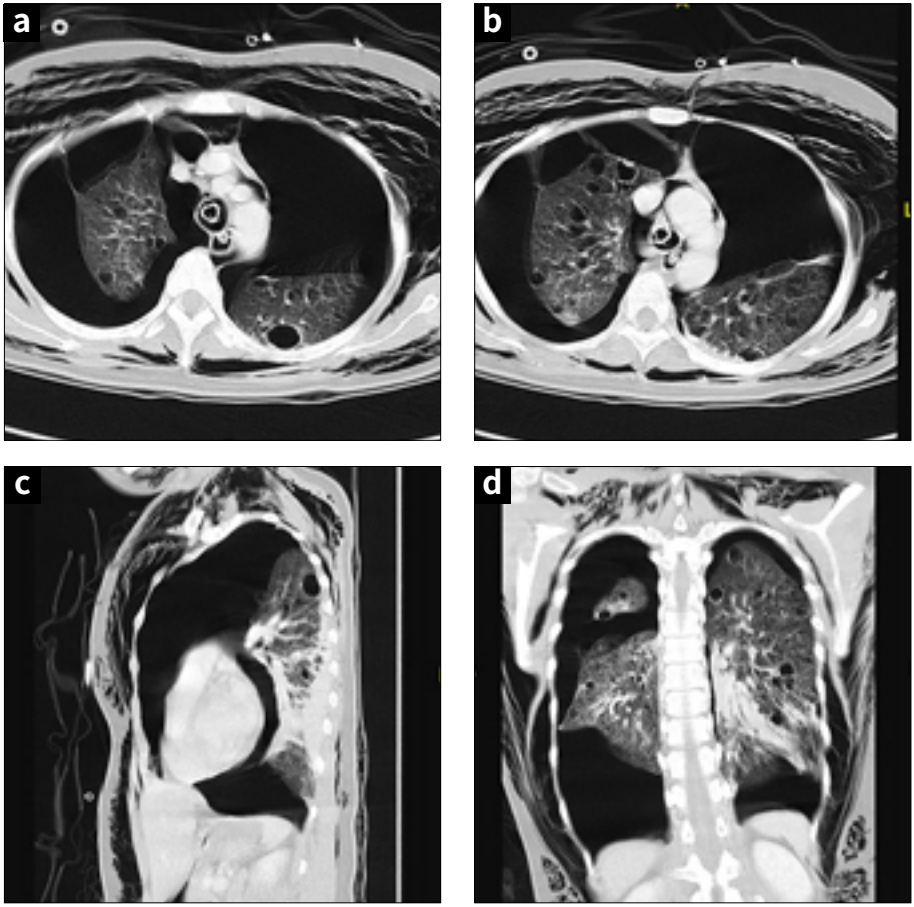

Follow up

- After discharged, she was routine followed at OPD
- In 2018 she was admitted due to shortness of breath and left shoulder and left chest pain. After supportive care, the short of breath improved.

The chest CT horizontal view (Figure 2a & Fig 2b), sagittal view (Figure 2c) , coronal view(Figure 2d) shows bilateral significant pneumothorax. Lung parenchyma shows bilateral diffuse multiple thin-walled cysts formation.

Figure 3: 2018 Chest radiograph findings

The PA chest radiography shows bilateral interstitial infiltrate. Localized emphysema and pneumothorax is also present in bilateral lung field.

Figure 4a-4d: 2018 Chest CT findings

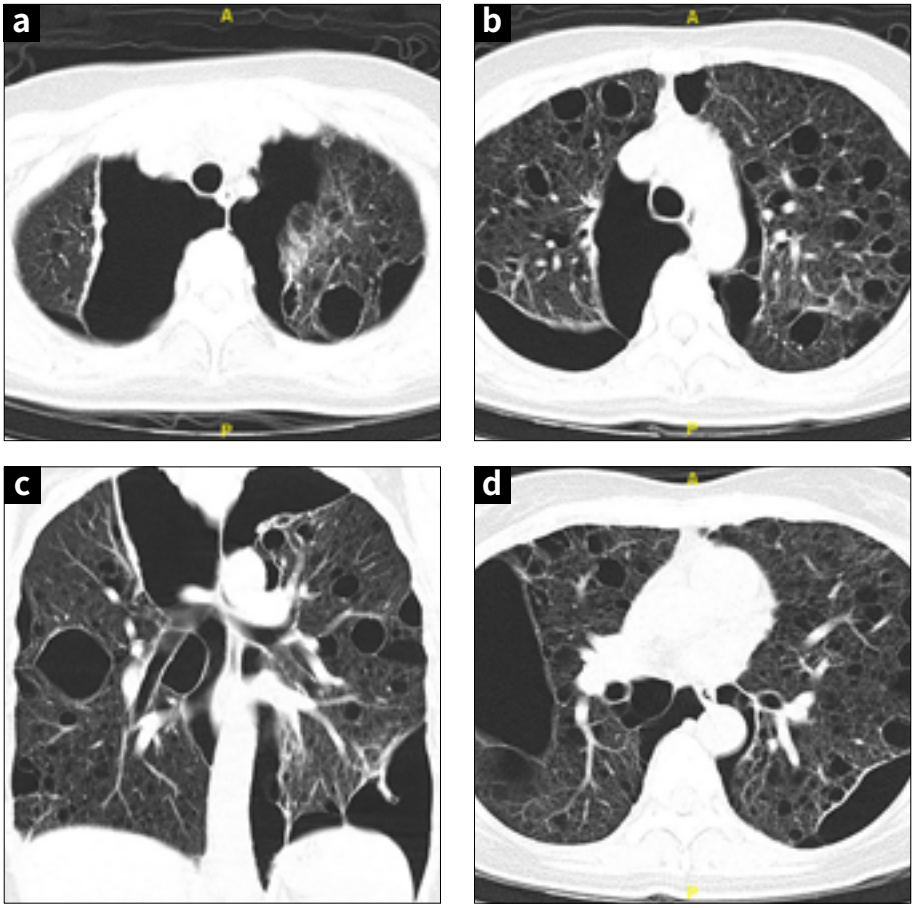

The Chest CT horizontal view (apical in Fig 4a, mid lung field in Fig 4b, basal lung field in Fig 4c) and coronal view (Fig 4d) shows multiple diffuse bilateral lung thin-walled cysts with variable sizes replacing normal parenchyma. Localized bullae and pneumothorax at bilateral lung field is also present.

Abbreviations

Lymphangioleiomyomatosis: (LAM); pulmonary Langerhans' histiocytosis: (PLCH); Birt-Hogg-Dubé syndrome: (BHD); lymphoid interstitial pneumonia: (LIP)

References

1. *Gupta N, Finlay GA, Kotloff RM et al. Lymphangioleiomyomatosis Diagnosis and Management: High-Resolution Chest Computed Tomography, Transbronchial Lung Biopsy, and Pleural Disease Management. An Official American Thoracic Society/Japanese Respiratory Society Clinical Practice Guideline. Am J Respir Crit Care Med. 2017 Nov 15;196(10):1337-1348.*
2. *Johnson SR, Cordier JF, Lazor R et-al. European Respiratory Society guidelines for the diagnosis and management of lymphangioleiomyomatosis. Eur. Respir. J. 2010;35(1): 14-26.*
3. *Oh YM, Mo EK, Jang SH et-al. Pulmonary lymphangioleiomyomatosis in Korea. Thorax. 1999;54(7): 618-21*
4. *McCormack FX: Lymphangioleiomyomatosis: a clinical update. Chest 133:507–516, 2008.*
5. *Taveira-DaSilva AM, Pacheco-Rodriguez G, Moss J. The natural history of lymphangioleiomyomatosis: markers of severity, rate of progression and prognosis. Lymphat Res Biol. 2010 Mar;8(1):9-19*
6. *Oprescu N, McCormack FX, Byrnes S, Kinder BW. Clinical predictors of mortality and cause of death in lymphangioleiomyomatosis: a population-based registry. Lung. 2013 Feb;191(1):35-42.*
7. *Murray and Nadel's Textbook of Respiratory Medicine Sixth edition, p1243-p1259.*

Pulmonary Langerhans Cell Histiocytosis Associated with Severe Pulmonary Arterial Hypertension

Dr. Yueh-Feng Wen[1],
Dr. Ping-Hung Kuo[2]

[1]Department of Internal Medicine, National Taiwan University Hospital Hsinchu Branch, Hsinchu, Taiwan

[2]Department of Internal Medicine, National Taiwan University Hospital, Taipei, Taiwan

Clinical pearls

- Pulmonary Langerhans cell histiocytosis (PLCH) is a smoking-related interstitial lung disease that tends to occur in young adults.
- The high-resolution computed tomography (HRCT) of patients with PLCH typically shows focal, nodulocystic lesions, which are distributed predominantly in the upper and middle lung fields and randomly in the central or peripheral parts of lungs and appear to relatively spare the costophrenic angles.
- PLCH may be complicated with recurrent spontaneous pneumothorax (10~20% prevalence), which often requires pleurodesis with video-assisted thoracoscopic surgery (VATS) and facilitates the diagnosis of PLCH with a concomitant biopsy.
- Vinblastine and cladribine are the current mainstay chemotherapeutic agents used in patients with progressive PLCH despite smoking cessation.
- Remarkable fibrosis may develop at the advanced stage of PLCH, suggesting the potential benefits of novel anti-fibrotic agents such as nintedanib and pirfenidone.
- Pulmonary arterial hypertension (PAH) is a rare complication of PLCH [WHO pulmonary hypertension (PH) group 5] and optimal management strategies remain unknown.
- Our experience from this case suggests that concurrent use of chemotherapy, PAH-specific drugs, and novel anti-fibrotic agents may assist in preventing disease progression in patients with advanced PLCH and severe PAH.

Patient profile

Case presentation

- 47-year-old man
- Chief complaints: progressive dyspnea on exertion for 2 years (after the age of 45) MRC breathlessness scale (WHO functional class 3-4, mMRC dyspnea score 3)
- Two episodes of spontaneous pneumothorax (at the age of 32 and 37 years, respectively)
- PLCH was diagnosed after VATS lung biopsy at the age of 32, and he stopped smoking thereafter.

Personal history

- Prednisolone 5 mg qd–tid
- Smoking history: 36 pack-year from the age of 15 to 32 years
- Occupation: an office worker
- Unremarkable family history
- No known exposure history

Physical examination

- Heart rate: 108 beats/min, respiratory rate: 24/min
- Heart: Graham Steell murmur
- Lungs: fine crackles over the bilateral lower lung fields
- No nail clubbing
- Pitting edema over the bilateral lower extremities (4+)
- Resting SpO_2: 90% with nasal O_2 delivered at 2-3 L/min.

Laboratory panels

Parameter	Value	Parameter	Value
Hct (%)	52.0 (↑)	CRP (mg/dL)	0.47
Hgb (g/dL)	17.6 (↑)	RF (IU/mL)	<10.40
WBC (k/μL)	6.99	ANA (1:N)	1:40 (-)
Neutrophil (%)	78.2 (↑)	Anti-ENA (screen)	Negative
Eosinophil (%)	1.0	P-ANCA (IFA)(1:N)	Negative
Albumin (g/dL)	2.7 (↓)	C-ANCA (IFA)(1:N)	Negative
BUN (mg/dL)	28.2 (↑)	C3 quantification (mg/dL)	128.00
Creatinine (mg/dL)	1.0	C4 quantification (mg/dL)	17.90
Sodium (mmol/L)	134 (↓)	D-Dimer (μg/mL FEU)	4.24 (↑)
Potassium (mmol/L)	3.5	HIV Ag/Ab (screen)	Negative
T-BIL (mg/dL)	1.85 (↑)		
ALT (IU/L)	25		
LDH (U/L)	365 (↓)		
NT-proBNP (pg/mL)	5880 (↓)		

Radiological imaging studies

Figure 1: Chest radiography findings

- Cardiomegaly; bilateral engorged pulmonary trunks
- Bilateral reticulo-nodular shadows
- Right costophrenic angle blunting

Figure 2a-2d: High-resolution computed tomography

- Diffuse reticular opacities over bilateral lungs
- Scattered nodules over bilateral lungs (white triangle)
- Scattered cystic lesions over bilateral lungs, some confluent together forming bizarre shape cysts (white arrow)
- Honeycomb-like cysts (black arrow) and traction bronchiectasis over bilateral posterior basal lungs.

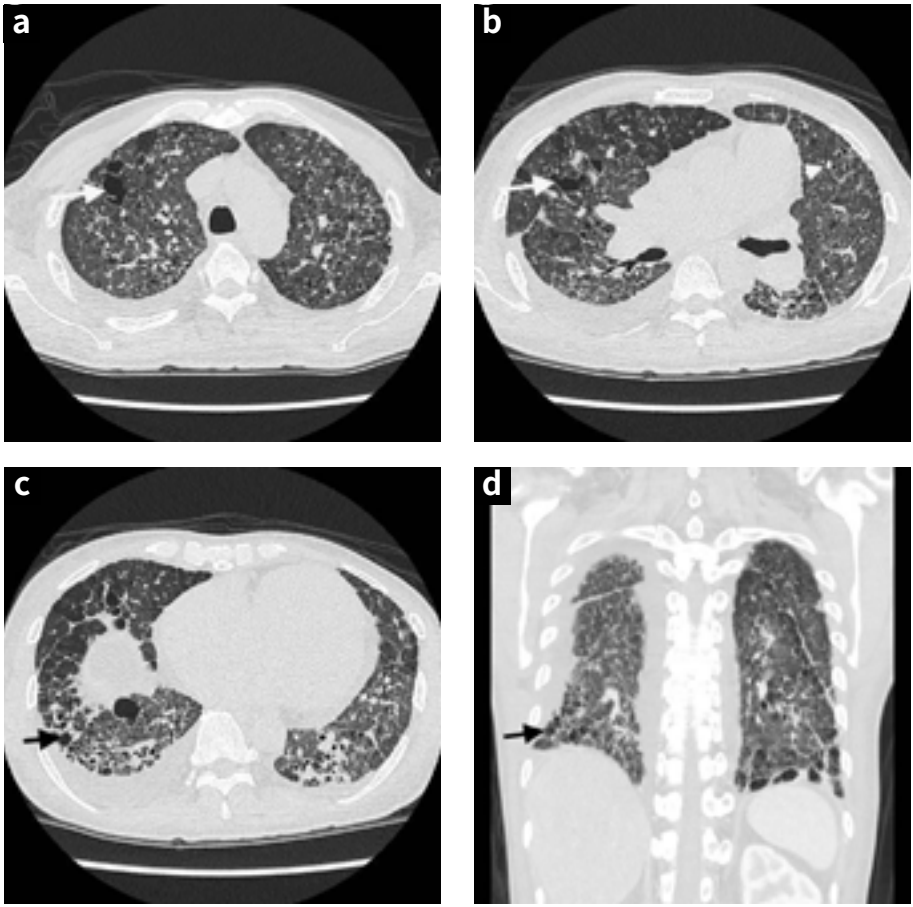

Pulmonary function, hemodynamics, and treatment course (Table 1)

- The multi-modality treatment and response of PLCH and its complicaiotns during a 13-month follow-up period

[a]Inhaled;[b]intravenous;[c]subcutaneous

			Time(Month)						
			1	2		3	4	5	6
treatment target	PLCH		Vinblastine				Cladribine		
			Prednisolone						
	PF		Pirfenidone						
	PAH	Maintenance	Sildenafil						
		Rescue		[a]Iloprost	[b]Epoprostenol				
measurement	WHO Fc		IV	IV		III-IV	III-IV	III	III
	FVC (L; % predicted)		1.37: 39.1						
	D_{LCO} (% predicted)		18.1						
	TR max vel. (m/sec)		4.194			3.801			
	mPAP (mmHg)		61						
	PAWP (mmHg)		7						
	PVR (Wood unit)		23						

Time(Month)							
7	8	9	10	11	12	13	
	Cladribine						
Prednisolone							
Pirfenidone				Nintedanib			
Sildenafil and macitentan							Sildenafil, macitentan, and [c]treprostinil
						[b]Epoprostenol	
III-IV	III-IV	III	III	III-IV	III-IV	III-IV	
			1.57;44.8				
			23.7				
	3.638					5.245	
						51	
						7	
						14	

PET/CT

The PET/CT did not reveal extra-pulmonary involvement.

Abbreviations

FEV_1, forced expiratory volume in one second; FVC, forced vital capacity; HRCT, high-resolution computed tomography; LCH, Langerhans cell histiocytosis; PH, pulmonary hypertension; PAH, pulmonary arterial hypertension; PET/CT, positron emission tomography/computed tomography; PFT, pulmonary function test; PLCH, pulmonary Langerhans cell histiocytosis; VATS, video-assisted thoracic surgery; WHO, World Health Organization

References

1. Gupta N, et al. Am J Respir Crit Care Med. 2015;192(1):17-29.
2. Vassallo R, et al. Thorax. 2017; 72(10):937-945.
3. Lorillon G, et al. Eur Respir Rev. 2017;26(145). pii: 170070.
4. Galiè N, et al. Eur Heart J. 2016; 37(1):67-119.
5. Le Pavec J, et al. Chest. 2012;142(5):1150-1157.
6. Grobost V et al. Orphanet Journal of Rare Diseases. 2014 9:191.
7. Hyman DM et al. N Engl J Med. 2015;373(8):726-736.

Hypersensitivity Pneumonitis/ Acute Hypersensitivity Pneumonitis

Dr. Ching-Min Tseng, Dr. Chi-Wei Tao

Division of Respiratory Therapy, Department of Internal Medicine,
Cheng-Hsin General Hospital,
Taipei, Taiwan

Clinical pearls

- Hypersensitivity pneumonitis (HP) is a complex syndrome resulting from repeated exposure to a variety of organic dusts. Clinically, it may present as acute, subacute, or chronic forms or present as overlapping forms. The symptom duration of acute HP usually develops within a few weeks/months (<6 months) after exposure to the causative agent.
- The typical high-resolution computed tomography (HRCT) findings that suggest acute HP include upper- and middle-lobe predominant ground-glass opacities, poorly defined centrilobular nodules, mosaic attenuation, air trapping, and/or rarely, consolidation.
- The HRCT findings in chronic HP specifically are reticulation, architectural distortion, and traction bronchiectasis with or without honeycomb change.
- The median bronchoalveolar lavage (BAL) fluid lymphocyte count is above normal values by more than 20% in HP.

Patient profile

Case presentation

- 81-year-old male
- A herbal tea store owner
- Progressed dyspnea with chest pain for weeks

Medical history

- History of asthma, coronary artery disease, hypertension, old pulmonary tuberculosis
- Medication including betaloc, aspirin, sevikar, tonsaric, vytorin, actein
- No history of alcohol or tobacco usage
- Has no pets
- Exposure to herb dust
- Unremarkable family history

Physical examination

- Heart rate: 94 BPM
- SpO_2: 80% while breathing ambient air
- Bibasilar rales on auscultation
- No finger clubbing
- No leg edema
- No arthralgia
- No skin rashes

Laboratory panels

- White blood cell count 10,200/cumm. Normal biochemistry
- Negative autoimmune profile including RF, ANA, and anti-SSA/SSB
- Bronchoalveolar lavage fluid collection via RB2 showed red blood cell count 6750/ul, white blood cell count 210/ul, neutrophil 19%, lymphocyte 37%, eosinophil 0%, histocyte 44%
- Bronchoalveolar lavage fluid culture: Escherichia coli >1000 CHF/ml; Cryptococcus neoformans 100 CFU/ml

Treatment and outcome

- Fluconazole 400mg IV every 12 hours started for 2 weeks
- His saturation recovered from 92 to 98%, even without oxygen support after treatment

Pathology panels

- Transbronchial biopsy was done via RB9. The histology reported edema in the submucosa

Pulmonary function tests

Parameter	Value
FVC	69% predicted
FEV_1	86% predicted
FEV_1/FVC	79%
TLC	67% predicted
D_{LCO}	25% predicted

***Conclusion*:** Mild restrictive ventilatory defect and severe impairment of D_{LCO}.

Radiological imaging studies

Figure 1: Chest radiography findings

CXR shows reticular pattern and ill-defined ground-glass opacity at both lung fields. Blunted right lateral costophrenic angle is also noted.

Figure 2a-2d: High-resolution computed tomography

HRCT shows mosaic air-trapping, asymmetric patchy ground-glass opacity, subpleural reticulation, mild fibrotic change and traction bronchiectasis at bilateral lungs.

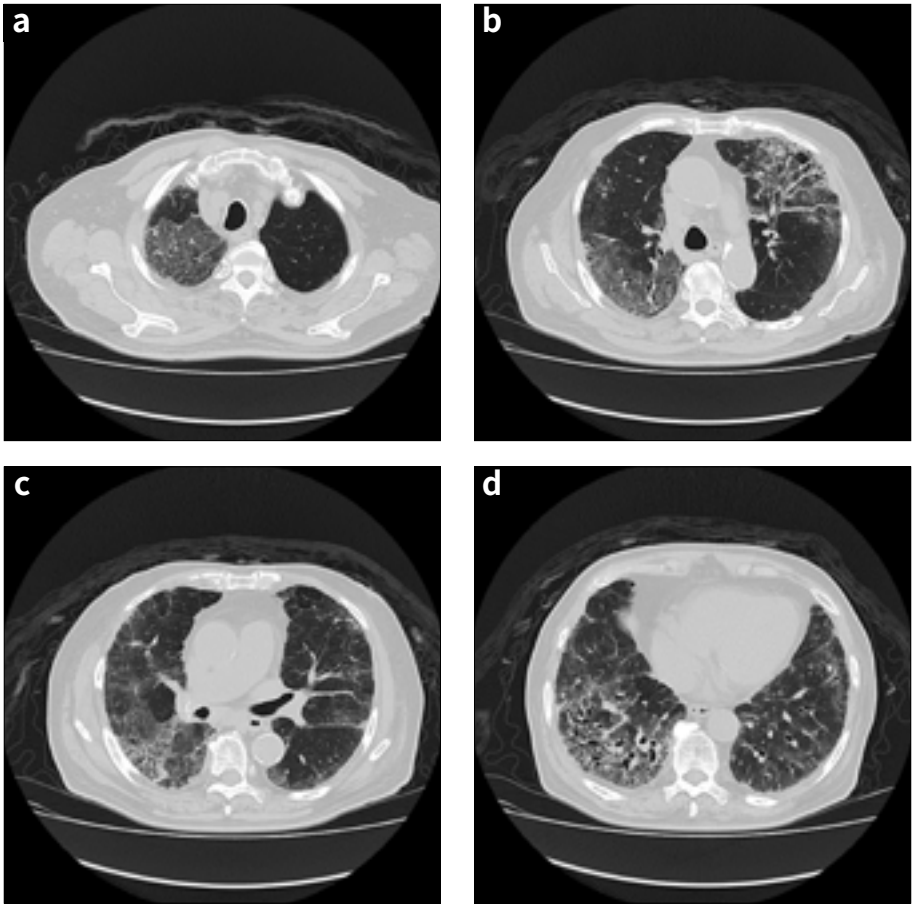

Abbreviations

HP, hypersensitivity pneumonitis; ILD, interstitial lung diseases; HRCT, high-resolution computed tomography; BAL, bronchoalveolar lavage

References

1. *Vasakova M, Morell F. Hypersensitivity Pneumonitis: Perspectives in Diagnosis and Managemen Am J Respir Crit Care Med 2017;196(6):680–89.*
2. *Silva CA, Andrew C. Hypersensitivity Pneumonitis: Spectrum of High-Resolution*
3. *CT and Pathologic Findings. AJR 2007;188:334–44.*
4. *Adams TN, Newton CA. Utility of Bronchoalveolar Lavage and Transbronchial Biopsy in Patients with Hypersensitivity Pneumonitis. Lung 2018;196(5):617–22.*
5. *William T, Ulrich C. An Official American Thoracic Society/European Respiratory Society Statement: Update of the International Multidisciplinary Classification of the Idiopathic Interstitial Pneumonias. Am J Respir Crit Care Med 2013;188(6):733–48*

Pleuroparenchymal Fibroelastosis

Diagnosis and overview of pleuroparenchymal fibroelastosis

Dr. Yao-Wen Kuo, Dr. Hao-Chien Wang

Department of Internal Medicine & Integrated Diagnostics & Therapeutics, National Taiwan University Hospital,
Taipei, Taiwan

Clinical pearls

- Pleuroparenchymal fibroelastosis (PPFE) is a distinct pattern of pulmonary fibrosis with elastosis. Epidemiology studies show that two peaks occur in the 3rd and 6th decade of life and that 45% of the patients are male[1,2].
- The most common presenting complaints are breathlessness, cough, weight loss, pneumothorax, and chest pain. Physically, patients with PPFE are often slender, with a "flattened thoracic cage". However, clubbed fingers and crackles are unusual[1].
- The diagnosis of PPFE is still based on multidisciplinary discussion (MDD; by clinical/radiological /pathological criteria).
- The typical radiological findings are pleural thickening with associated subpleural fibrosis concentrated in the upper lobes. The typical pathological findings are upper zone pleural fibrosis with subjacent intra-alveolar fibrosis accompanied by alveolar septal elastosis[1,4].
- Typical pulmonary function tests show restrictive ventilatory defect, and an increased ratio of RV/TLC due to the fibrotic collapse of upper lobes and compensatory over-inflation of lower lobes. D_{LCO} is usually normal or minimally reduced[5,6].
- Its pathogenesis is still unclear. It is usually preceded by an acute lung injury or interstitial inflammation, e.g. after a lung transplant [1,3,4].
- Once PPFE is diagnosed, the disease progresses rapidly in the absence of effective medical therapy. Lung transplantation is the only effective treatment for PPFE[7].

Patient profile

Case presentation

- 66-year-old female
- Worked at a morgue for 30 years
- Dry cough for more than 5 years
- Light yellowish sputum noted for 3 months
- Exertional dyspnea with worsening symptoms for 4 months and nonresponsive to medication

Medical history

- No smoking history
- Previous diagnosis with old tuberculosis 6 years ago in 2010
- Denied having a family history of lung disease

Physical examination

- Body height (BH) 156 cm, body weight (BW) 30.6 kg, body mass index (BMI) 12.5
- Decreased anteroposterior diameter of the chest
- No Velcro crackles
- No cyanosis or clubbing of the fingers

Laboratory panels

Hb (g/dl)	MCV (fl)	MCH (pg)	Hct (%)	PLT (k/ul)	WBC (k/ul)	Seg (%)	Band (%)	Eos (%)	Mono (%)	Lym (%)
12.8	95.2	32.2	37.8	328	9.99	78.7	0	0.9	5.8	14.1

Na (mmol/L)	K (mmol/L)	Cre (mg/dl)	ALT (U/l)
141	4.4	0.6	10

pH	$PaCO_2$ (mmHg)	PaO_2 (mmHg)	HCO_3 (mmol/L)	BE (mmol/L)
7.412	37.6	95.8	24.2	-0.7

Parameters	Value	Unit	Reference value
RA Factor (Nephelometry)	<11.40	IU/mL	<15.9
C3 Quantitation	111.00	mg/dL	90~180
C4 Quantitation	29.30	mg/dL	10~40
Anti-DNA(FA)	1:5 (-)	1:N	1:5 (-)
Anti-ds DNA	146.00	IU/mL	Negative：<200 Positive：>301
Anti-ENA	Positive (1.17)	ratio	Negative：<0.7 Positive：>1.0
IgE	106.00	IU/mL	< 100

- Sputum acid-fast stain: Acid fast-bacilli- negative X 3

Pulmonary function test

- Flow-Volume-Test (Body Temperature and Pressure Saturated (BTPS), Sitting-Position)

Parameters	Observed	Predicted	% Predicted
FVC(L)	0.57	2.22	25.7
FEV1(L)	0.54	1.77	30.5
FEV1/FVC(%)	94.7	81.4	
FEF25-75%(L/S)	0.64	2.2	29.1
PEFR(L/S)	1.27	5.22	24.3
FEF25%(L/S)	0.86	4.76	18.1
FEF50%(L/S)	0.78	2.68	29.1
FEF75%(L/S)	0.34	0.51	66.6

Severe restrictive ventilatory defect; Inadequate tracing for D_{LCO} for small vital capacity (VC)

Radiological imaging studies

Figure 1a-1b: Chest radiography findings

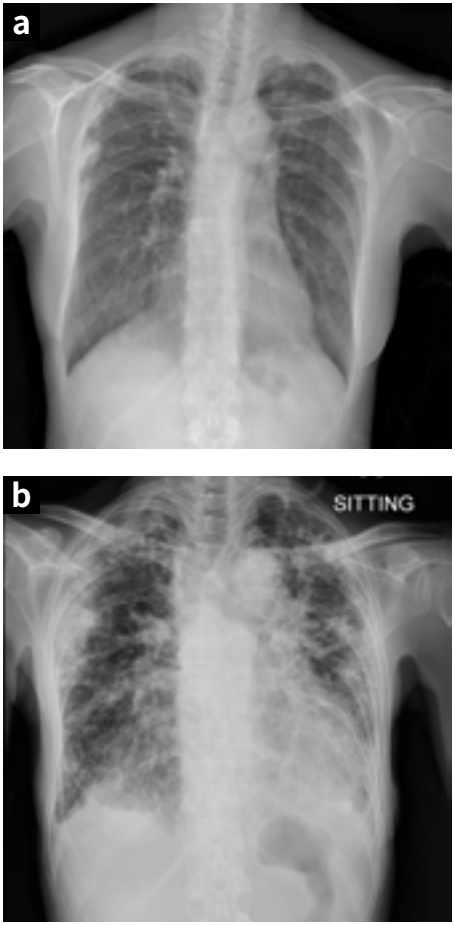

(a)Baseline CXR in 2010 reveals mild fibrotic change and pleural thickening at bilateral upper lung fields.(b)Follow-up CXR 6 years later in 2016 shows progressive fibrotic change and pleural thickening involving not only the upper lung fields but the whole bilateral lungs, with blunted bilateral costophrenic angles.

Figure 2a-2b: High-resolution computed tomography

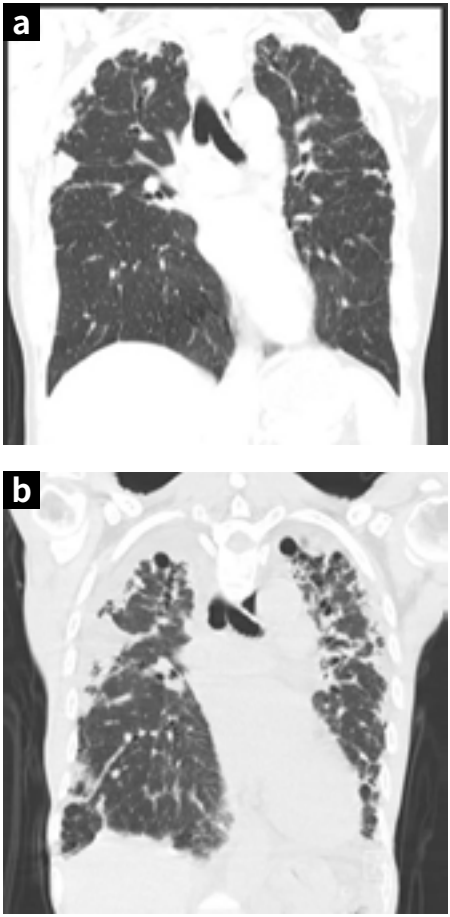

(a)Baseline HRCT in 2010 reveals mild fibrotic change and pleural thickening at bilateral upper lobes.(b)Follow-up HRCT 6 years later in 2016 shows more prominent fibrotic change, pleural thickening, subpleural atelectasis and traction bronchiectasis involving the whole lung, but still more dominant in bilateral upper lobs.

Figure 3a-3c: High-resolution computed tomography

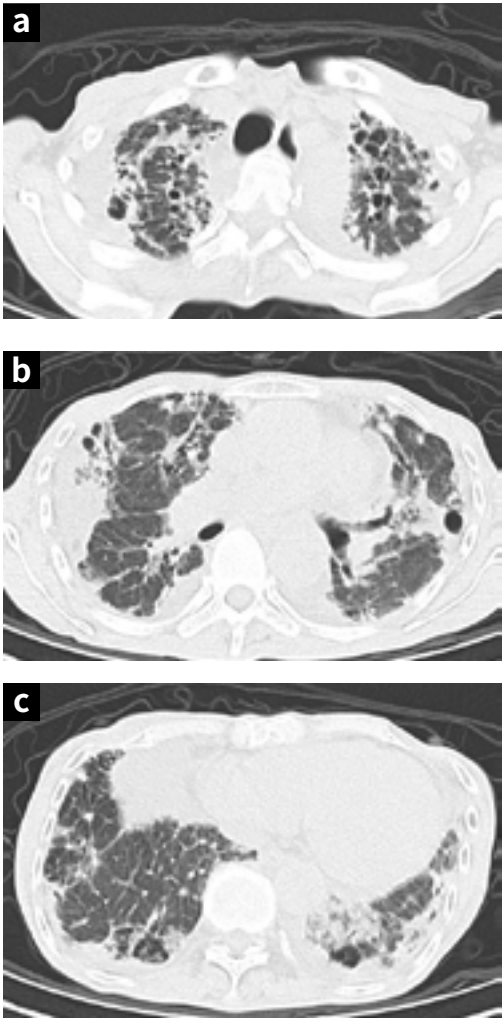

Follow-up HRCT 6 years later in 2016 shows more prominent fibrotic change, pleural thickening, subpleural atelectasis and traction bronchiectasis involving the whole lung, but still more dominant in bilateral upper lobs.

Clinical course

- 2016/7: admission due to pneumonia, discharged after the administration of antibiotics
- 2016/10: admission due to right pneumothorax status post tube thoracostomy with low pressure suction
- 2016/11: due to persistent air leakage and disease diagnosis, the patient received thoracoscopic pleurodesis and wedge resection (RUL, RLL) + pleura biopsy
- 2016/11~2017/04: ventilator dependent status due to low lung compliance (less than 15 ml/cmH_2O); recurrent pulmonary infections
- 2017/04: patient passed away

- Figure 4a-4b:Pathology of upper lung: Hematoxylin-eosin stain and Elastic Van Gieson stain

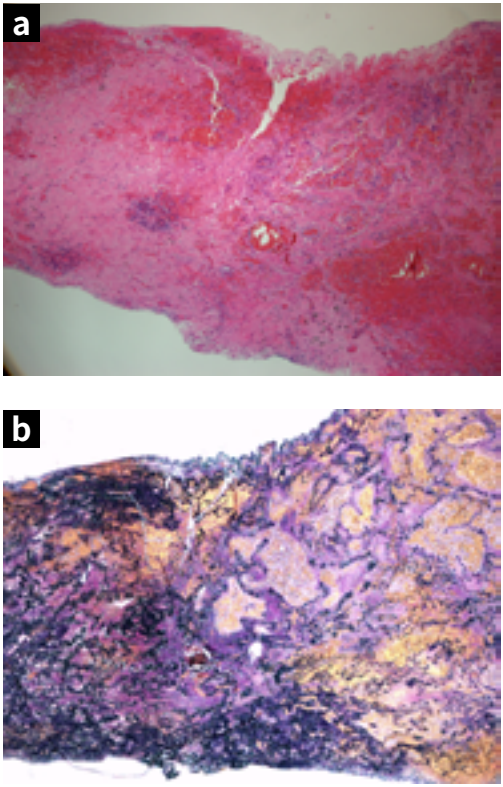

(a)The right upper lobe fragment shows pleural fibrosis with smooth muscle metaplasia into the interalveolar wall. Lymphocytic infiltrate and irregularly-dilated alveolar spaces with reactive pneumocyte hyperplasia and collection of histiocyte within the alveolar spaces are also present. (b) Through special staining, Orcein and EVG stains demonstrate that the fibrosis is intraalveolar, with elastosis marking the residue of the alveolar walls.

Abbreviations

PPFE, pleuroparenchymal fibroelastosis; D_{LCO}, diffusing capacity of the lung for carbon monoxide; MDD, multidisciplinary discussion; RV, residual volume; TLC, total lung capacity.

References

1. *Cheng SK, Chuah KL. Pleuroparenchymal Fibroelastosis of the Lung: A Review. Arch Pathol Lab Med 2016; 140:849-853*
2. *Travis WD, Costabel U, Hansell DM, et al. An official American Thoracic Society/European Respiratory Society statement: Update of the international multidisciplinary classification of the idiopathic interstitial pneumonias. Am J Respir Crit Care Med 2013; 188:733-748*
3. *Portillo K, Guasch I, Becker C, et al. Pleuroparenchymal Fibroelastosis: A New Entity within the Spectrum of Rare Idiopathic Interstitial Pneumonias. Case Rep Pulmonol 2015; 2015*
4. *Reddy TL, Tominaga M, Hansell DM, et al. Pleuroparenchymal fibroelastosis: a spectrum of histopathological and imaging phenotypes. Eur Respir J 2012; 40:377-385*
5. *Watanabe K, Nagata N, Kitasato Y, et al. Rapid decrease in forced vital capacity in patients with idiopathic pulmonary upper lobe fibrosis. Respir Investig 2012; 50:88-97*
6. *Oda T, Ogura T, Kitamura H, et al. Distinct characteristics of pleuroparenchymal fibroelastosis with usual interstitial pneumonia compared with idiopathic pulmonary fibrosis. Chest 2014; 146:1248-1255*
7. *Nakatani T, Arai T, Kitaichi M, et al. Pleuroparenchymal fibroelastosis from a consecutive database: a rare disease entity? Eur Respir J 2015; 45:1183-1186*

ILD CASEBOOK

間質性肺病案例集

發行單位：台灣胸腔暨重症加護醫學會
地址：10045 台北市中正區重慶南路 1 段 57 號 6 樓之 3
電話：02-2314-4089
傳真：02-2314-1289
網址：www.tspccm.org.tw

發行人：林孟志
總編輯：陶啟偉　　顧問：王鶴健
編輯委員：柯信國、 郭炳宏、 鄭世隆（依姓氏筆畫排列）
執行編輯秘書：傅彬貴、曾敬閔、 溫岳峰（依姓氏筆畫排列）
醫學影像總編修：張允中
醫學影像編輯
小組：黃昱森、陳若瑀、簡寧 (依姓氏筆畫排列）
撰稿人：曾敬閔、傅彬貴、柯延昆、馮嘉毅、王崇任、陳美音、李吉泰、王旭暉、溫岳峰、郭耀文 (依案例順序排列）

出版社：臻呈文化行銷有限公司
地址：10654 台北市大安區忠孝東路三段 249-1 號 10 樓
電話：02-2778-7711
傳真：02-2778-7755
網址： www.crossroad.com.tw
出版日期：西元 2019 年 4 月　初版 (精裝)
ISBN 978-986-95806-6-3

電子版下載點

台灣胸腔暨重症加護醫學會

Taiwan Society of Pulmonary and Critical Care Medicine

Boehringer Ingelheim 台灣百靈佳殷格翰股份有限公司 助印

ISBN 978-986-95806-6-3