# FabryBook

# 法布瑞氏症案例集

A case based learning module

中華民國心臟學會
TAIWAN SOCIETY OF CARDIOLOGY

# Prologue

Fabry disease is a rare genetic lysosomal storage disorder resulting from deficient activity of the enzyme alpha-galactosidase A, leading to progressive lysosomal deposition of globotriaosylceramide and its derivatives in cells throughout the body.

The classic form often has childhood or adolescence onset with periodic crises of severe pain in the extremities called acroparesthesia; the appearance of vascular cutaneous lesions, such as angiokeratomas; sweating abnormalities, such as anhidrosis, hypohidrosis, and rare hyperhidrosis; characteristic corneal and lenticular opacities; and proteinuria.

In contrast, late-onset forms often present in the fifth to eighth decade with left ventricular hypertrophy, cardiomyopathy, arrhythmia, and proteinuria; ESRD-associated renal failure without skin lesions and pain and cerebrovascular disease presenting as stroke or transient ischemic attack.

In Taiwan, the late-onset mutation, GLA IVS4+919G>A (designated GLA IVS4), is prevalent in patients with hypertrophic cardiomyopathy compared with patients in the rest of the world. Hence, the Taiwan Society of Cardiology collected 20 case studies to help cardiologists update the concepts of Fabry disease diagnostic and clinical management.

Professor Wen-Jone Chen
President, Taiwan Society of Cardiology

# Preface

Fabry disease is an X-linked lysosomal storage disorder, resulting from mutations in the α-galactosidase A gene (GLA) causing deficient α-galactosidase A (α-Gal A) activity, and a progressive systematic accumulation of globotriaosylceramides (Gb3) and related glycosphingolipids, particularly in the lysosomes of the heart, kidneys, skin, and brain.

A large-scale, newborn screening program of Fabry disease in Taiwan has revealed an unexpectedly more prevalent IVS4+919G>A (IVS4) c mutation, which is considered a late-onset cardiac variant of Fabry disease. Although patients less than 40 years of age rarely exhibit any specific symptoms, left ventricular hypertrophy (LVH) developed in approximately one-third of women, and two-thirds of men, with this mutation. Moreover, progressive cardiac involvement, the primary presentation, leads to hypertrophic cardiomyopathy and eventual heart failure in later life. Taiwanese cardiologists have accordingly turned their attention to this issue. What raises concern is that a significant cardiomyocyte substrate accumulation in patients with IVS4 may lead to severe and irreversible cardiac fibrosis before the development of LVH or other significant cardiac manifestations. Furthermore, it may be too late to start enzyme replacement therapy after the occurrence of LVH or other significant cardiac manifestations in patients with later-onset-type Fabry disease.

Fabrybook is a case-based, learning module delivering a concise review of our current understanding of the disease. It may assist our members to not only treat patients with classic type Fabry disease, but also to care for adult patients with late-onset, Fabry disease, especially that resulting from IV mutations. Such care spans diagnosis, family screening, genetic consultations, the regular monitoring of biomarkers, annual strain echocardiography, periodic cardiac magnetic resonance

imaging, and the management of general and specific interventions such as enzyme replacement therapy.

Editor-in-Chief
Yen-Wen Wu, MD. PhD
Director of Cardiovascular Medical Center, Far Eastern Memorial Hospital, New Taipei, Taiwan.
Chair, Cross-Discipline Committee in Taiwan Society of Cardiology

# 目錄


| | | |
|---|---|---|
| Update of Fabry Disease in Taiwan | | 06 |
| Case 1 - | Late-onset Fabry Disease with left ventricle hypertrophy and chronic kidney disease with proteinuria | 20 |
| Case 2 - | An unexplained case of left ventricular hypertrophy ultimately diagnosed as classic-type Fabry disease | 33 |
| Case 3 - | Fabry disease with complete atrioventricular block | 40 |
| Case 4 - | A patient with classic Fabry disease due to anti-drug antibodies formed during enzyme-replacement therapy | 51 |
| Case 5 - | A patient of classic Fabry disease with hypertrophic obstructive cardiomyopathy | 61 |
| Case 6 - | Early-detected Fabry disease | 68 |
| Case 7 - | A male patient with classic Fabry disease misdiagnosed for 28 years | 80 |
| Case 8 - | Syncope in a patient with left ventricular hypertrophy | 92 |
| Case 9 - | A case of Fabry disease with apical aneurysm | 101 |
| Case 10 - | A case of the cardiac variant of Fabry disease with intermittent chest pain | 120 |
| Case 11 - | A patient with chest tightness | 135 |
| Case 12 - | A patient of Fabry disease with atrial fibrillation and recurrent stroke | 153 |
| Case 13 - | A patient of cardiac variant Fabry disease with complete AV block | 167 |
| Case 14 - | A patient of cardiac variant Fabry disease with allergic reactions to ERT | 179 |
| Case 15 - | A patient of cardiac variant Fabry disease with ventricular arrhythmias | 190 |
| Case 16 - | A patient of IVS4 variant Fabry disease with chest pain | 201 |

| | | |
|---|---|---|
| Case 17 - | Classic Fabry disease coexisting with systemic lupus erythematosus | 210 |
| Case 18 - | A patient with Fabry disease experienced sudden cardiac cardiac death | 223 |
| Case 19 - | A patient with Fabry disease with poor treatment adherence | 255 |
| Case 20 - | A patient with arrhythmia | 266 |

Chapter 1

# Update on Fabry Disease in Taiwan

**Wen-Chung Yu, M.D.**

Taipei Veterans General Hospital
and National Yang Ming Chiao Tung University

In Taiwan, there is no consensus on the prevalence of Fabry disease. In the early era, the reported incidence of Fabry disease was thought to be relatively low, ranging from 1 in 476,000 to 1 in 117,000 of the general population. However, owing to results from several large screening studies worldwide, 1 in 3,100 males are reportedly affected in northwestern Italy, 1 in 3,000 males in Austria, 1 in 2,900 males in Missouri (USA), and 1 in 1,500 males in Taiwan, indicating the relatively high prevalence of Fabry disease than that expected previously. The latest statistical report of rare disease confirmed cases in Taiwan published by the Health Promotion Administration identified 478 confirmed patients with Fabry disease and 48 related deaths. Enzyme replacement therapy (ERT) including agalsidase alfa and beta were both approved by the Taiwan Food and Drug Administration in April 2004 and reimbursed by National Health Insurance Administration in the same year. Approximately 414 patients with Fabry disease are currently under ERT management.

Fabry disease is primarily diagnosed using newborn screening programs and based on the presence of adult idiopathic hypertrophic cardiomyopathy (HCM). Due to the absence of a nationwide screening program, as a reference, the Taipei Veterans General Hospital newborn screening project, which is the largest database reflecting the epidemiology of Fabry disease in Taiwan, was used. A total of 916,383 newborns were screened, and more than 1,200 individuals with the common and late-onset IVS4+919G>A (IVS4) mutation were identified. Until 2016, 189 patients with cardiac variant ----(IVS4) were diagnosed and followed up at the Division of Cardiology of Taipei Veterans General Hospital. The majority of these patients (>80%) were diagnosed using pedigree evaluation of newborn screening results; 12% were diagnosed through genetic screening for HCM, and less than 10% were diagnosed based on clinical suspicion (Figure 1). Among them, the 75 patients who met the criteria for ERT, were older, and demonstrated a male predominance owing to the disease's X-linked characteristics. However, not every potential ERT candidate consented to treatment.

## Figure 1.

Methods used to diagnose patients with the cardiac variant of Fabry disease (IVS4 mutation) at the Department of Cardiology, Taipei Veterans General Hospital, in 2016

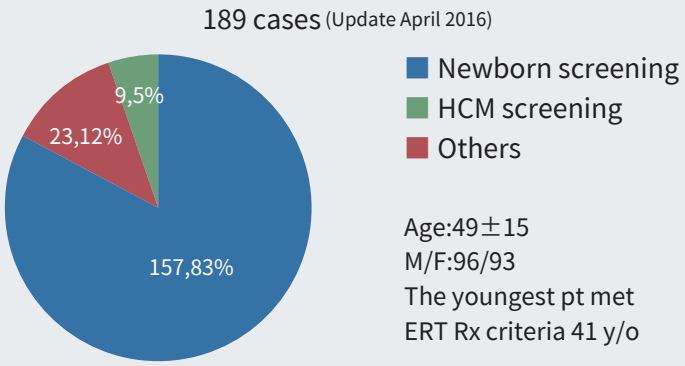


## Figure 2.

Methods used to diagnose patients with the cardiac variant of Fabry disease (IVS4 mutation) who were eligible for ERT at the Department of Cardiology, Taipei Veterans General Hospital, in 2016

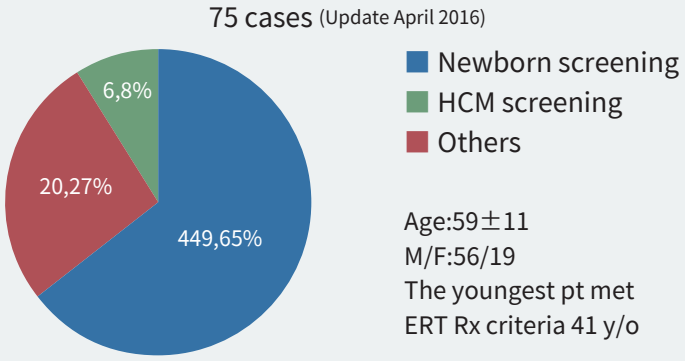


In the clinical setting, although newborn screening for Fabry disease is an optional test, parents are highly willing to participate in the program because of the low testing cost; thus, test coverage exceeds 90%. From 2006 to 2008, the National Taiwan University Hospital's

newborn screening method utilized the dry blood spot test to assess enzymatic activity and confirmed abnormal activity in 1 in 1,250 male infants. Further testing revealed that 86% of these neonates harbored the IVS4+919G>A mutation (Figure 3).[1] The Taipei Veterans General Hospital and National Taiwan University Hospital had similar results, with an overall prevalence of 1 in 1,368 male infants; moreover, 82% of the affected infants carried the IVS4+919G>A mutation. In a study of pedigree screening based on neonatal cases, Professor Niu Dau-Ming（牛道明）successfully investigated a large cohort of patients with the cardiac variant of Fabry disease at Taipei Veterans General Hospital.[2]

## Figure 3.

Results of newborn screening for Fabry disease at National Taiwan University Hospital from 2006 to 2008

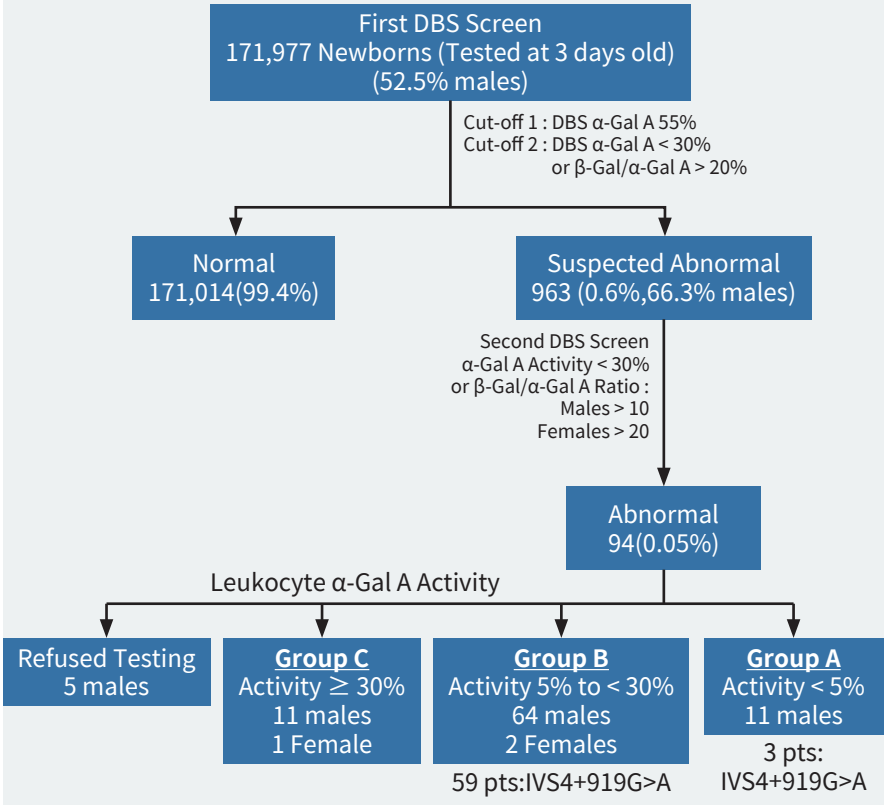

In IVS4 carriers, left ventricular hypertrophy (LVH) develops with age and usually is clinically detectable around age 40[3]. Theoretically, Fabry disease follows an X-linked inheritance pattern, females with only one mutation-carrying X chromosome (heterozygous) would not be affected. However, clinical observations contradict this theoretical inference, and this may be due to a skewed X inactivation whereby disease progression is more unpredictable in female, compared with male, patients (Figure 4).[3]

## Figure 4.

Age-related changes in the incidence of Fabry disease among male and female carriers of the IVS4 mutation

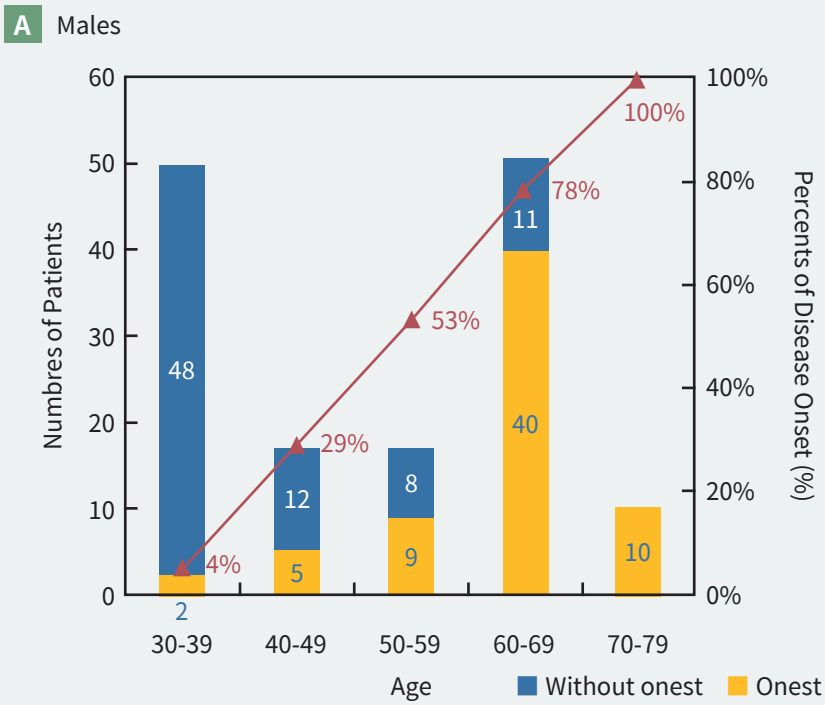

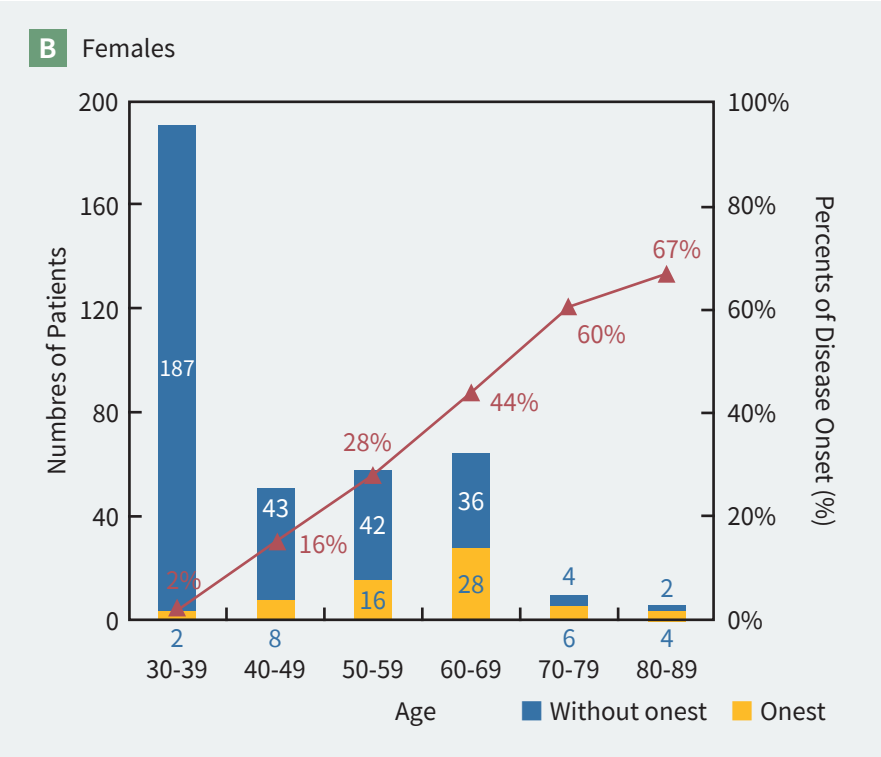


With the significantly higher likelihood of detecting cardiac pathology among individuals with Fabry disease gene mutations after age 40, regular echocardiography and electrocardiography (EKG) are recommended for this population group.3 The relatively high incidence of Fabry disease and high ERT cost have generated a special issue associated with ERT reimbursement in Taiwan. The Taiwan Society of Cardiology undertook a concerted effort for consensus on the diagnosis and clinical management of the cardiac manifestations of Fabry disease by 2021 (Figure 5). The consensus statement offers detailed recommendations for management and monitoring methods4 and serves as an important clinical reference.

## Figure 5.

Recommendations from the 2021 Taiwan Society of Cardiology Expert Consensus for the Clinical Features, Diagnosis, and Clinical Management of Cardiac Manifestations of Fabry Disease

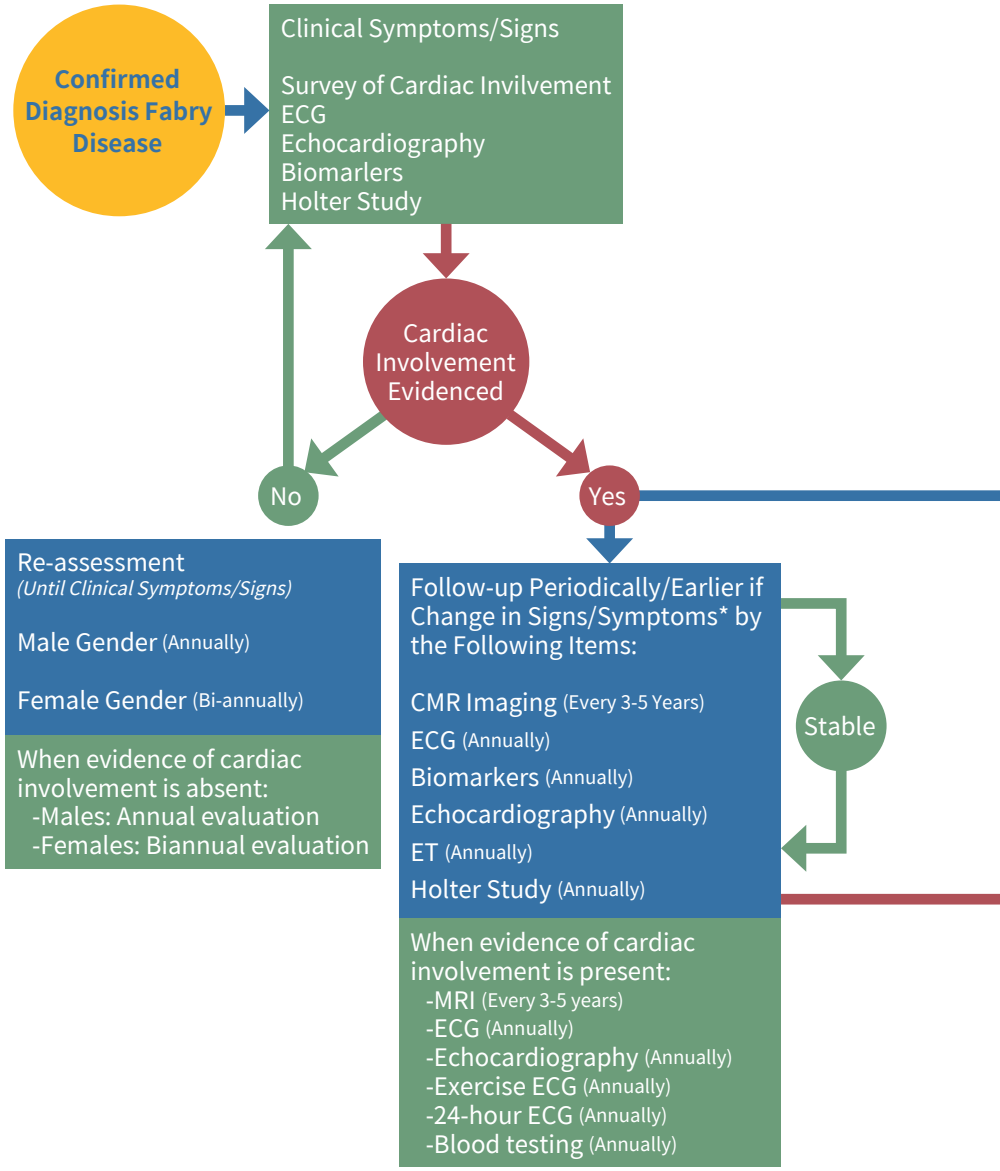

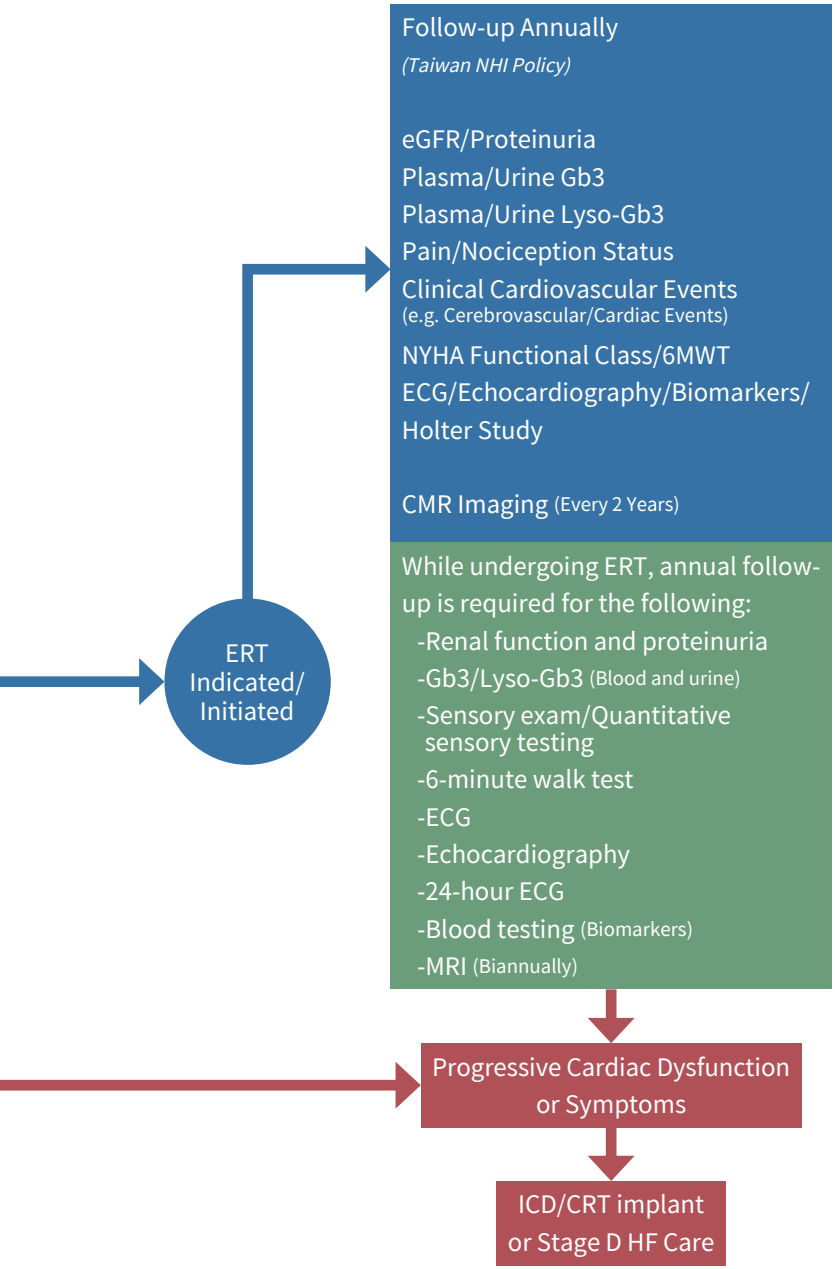


(*referred to Conduction Disorders, Ventricular Arrhythmias, Syncope, Coronary,Insufficiency, Elevated HF Markers, LV Contractile Function, LVOT Obstruction)

The greatest challenge in clarifying the progression of Fabry disease is its late and gradual onset, particularly in patients afflicted with the cardiac subtype of Fabry disease. As individuals in whom a genetic mutation is detected during newborn screening often present with Fabry disease approximately 40 years later, it is nearly impossible for the same physician to be responsible for the follow-up. Therefore, inter-hospital cooperation and long-term monitoring of a large-scale cohort are indispensable for obtaining a clear understanding of Fabry disease. As of 2020, at the Taipei Veterans General Hospital, 268 patients (82.9%) harbored an IVS4 mutation. Only 70% of patients with LVH received treatment. Compared to 2016, a lower proportion of patients were diagnosed with Fabry disease through newborn screening (Figure 6). Thus, efforts in recent years have gradually increased our awareness and enhanced our understanding of this disease.

## Figure 6.

Distribution of the methods used to diagnose the cardiac variant of Fabry disease (IVS4 mutation) at the Department of Cardiology, Taipei Veterans General Hospital, in 2016

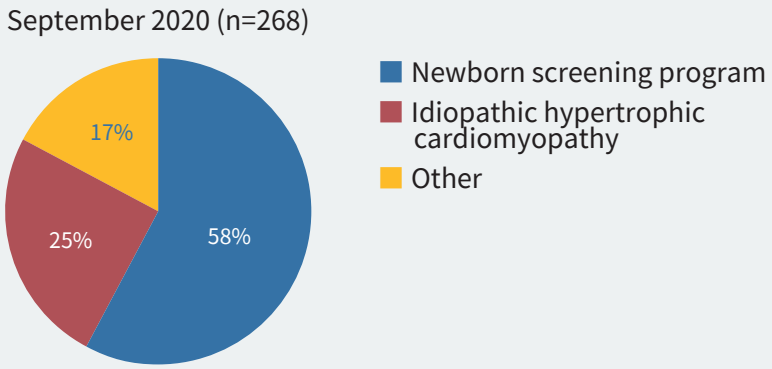


Cardiac-subtype Fabry disease is usually considered a mild form of classic Fabry disease because the former has high residual enzymatic activity without the involvement of other organs. Interestingly, the cardiovascular score, as measured by the Mainz Severity Score Index (MSSI), was similar in patients with the IVS4 cardiac subtype and those

with classic Fabry disease in a cohort study at the Taipei Veterans General Hospital.[5] From a cardiovascular viewpoint, the IVS4 cardiac subtype might not be a mild form of classic Fabry disease. However, large-scale multicenter studies are required. Therefore, the Taiwan Society of Cardiology started the Taiwan Registry of Hypertrophic Cardiomyopathy (THIC) Research in November 2022, aiming to systematically evaluate the clinical, genetic, and biochemical features; prevalence; possible natural course; and treatment outcomes of HCM and relevant rare diseases such as Fabry disease in Taiwan. Meanwhile, this registry may also generate the specific "red flag" signs of Fabry disease in Taiwan.

With regard to prognosis and prognostic factors, patients who have yet to progress to LVH exhibit worse global longitudinal strain (GLS) in the left ventricle (LV) than those in the control group. Although the strength of the association is insufficient to support the use of echocardiography alone to determine whether the patient has cardiac variant-Fabry disease, GLS may serve as a marker for follow-up (Figure 7).[6] Furthermore, the right ventricular (RV) and left atrial (RA) functions of patients with Fabry disease are worse than those of healthy controls. This presents a promising avenue for predicting the risk of developing Af and atrial arrhythmias although precise clinical utilization requires further investigation. In summary, reductions in LV, RV, and left atrial (LA) function constitute the natural history of Fabry disease; however, we are still unable to draw a clear association between these phenomena and cardiac outcomes.

## Figure 7.

Association between left ventricular GLS and LVH in patients diagnosed with Fabry disease at Taipei Veterans General Hospital

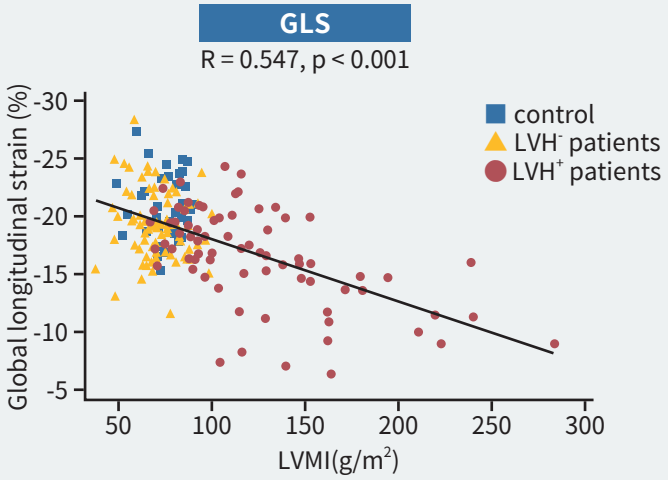


## Figure 8.

Comparison of the right ventricular (A) and left atrial (B) functions of healthy adults and patients diagnosed with Fabry disease at Taipei Veterans General Hospital

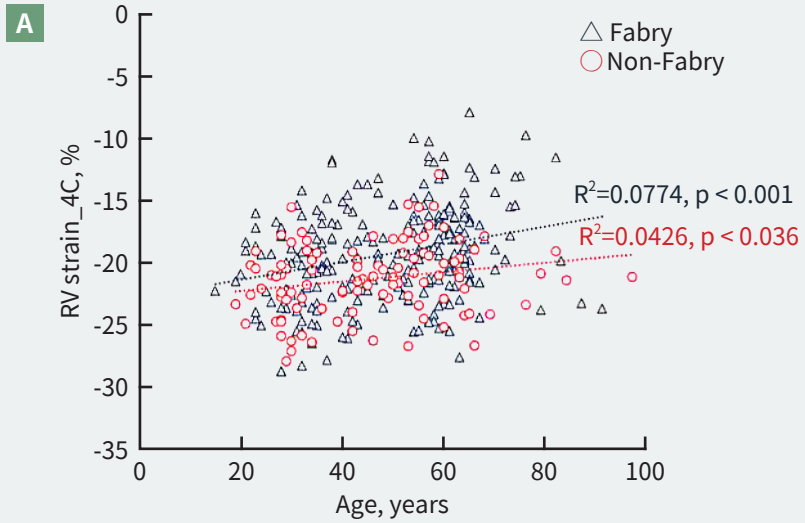

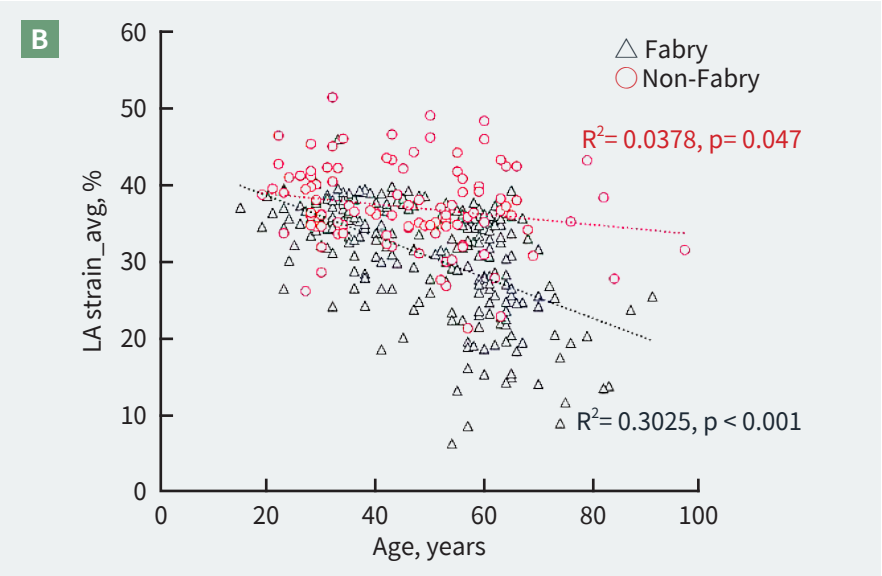


Additionally, we analyzed the association between the presence or absence of LVH and the incidence of adverse cardiovascular events [cerebrovascular accidents, heart failure, and death, ventricular tachycardia (VT), and ventricular fibrillation (VF)] in a cohort of patients with Fabry disease in the past ten years. After correcting for age, sex, and other factors, we found that LVH increased the risk of adverse cardiovascular events nearly 16 times (Figure 9). The pathogenesis of LVH development following the onset of Fabry disease is an important marker. Left ventricular apical aneurysm (LVAA) is a marker of poor prognosis in patients with HCM7 and there is limited data on LVAA in Fabry disease. In our cohort, approximately 10% of the patients with LVH presented with LVAA. Moreover, our data revealed a significantly increased risk of cardiovascular events in patients with Fabry disease and LVAA (Figure 10).[8]

## Figure 9.

Comparison of the cardiovascular prognoses of patients with and without LVH

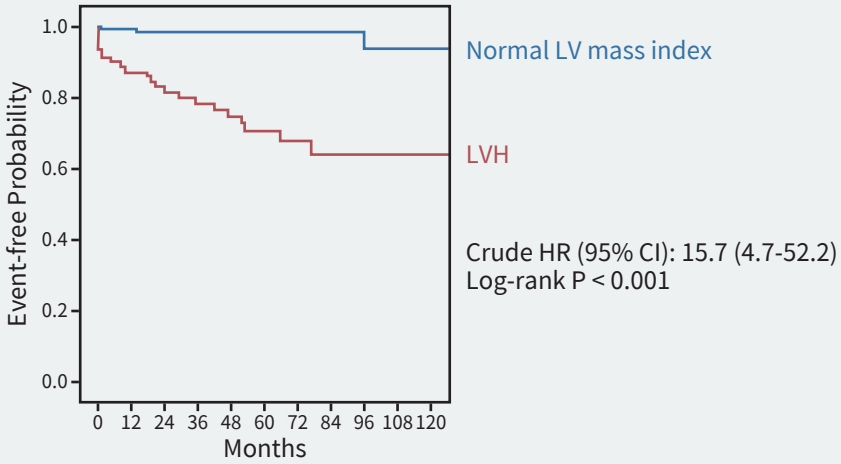


## Figure 10.

Comparison of the cardiovascular prognoses of patients with and without LVAA

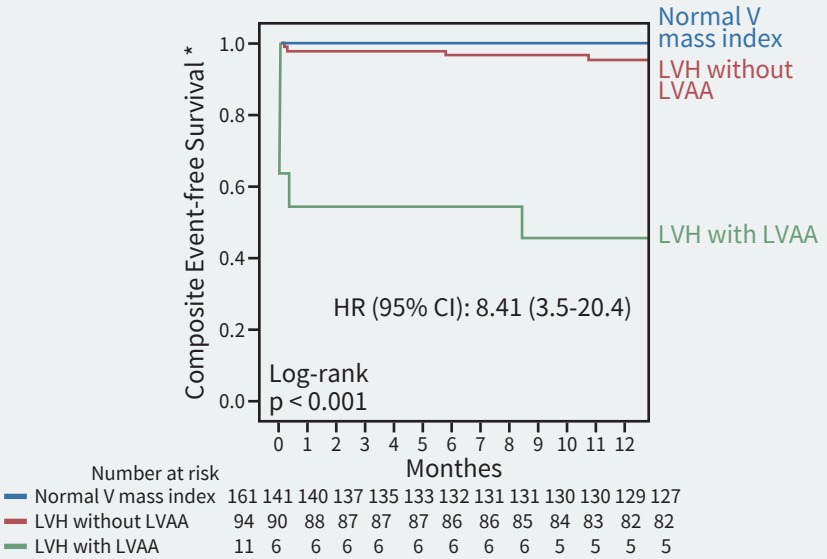

Prior to engaging in research and care of patients with Fabry disease, I had hardly ever encountered such patients. However, I have gained experience and maturity in the past 10 years and now realize that such patients are not uncommon. Taiwan has a high IVS4 mutation rate that has received international attention in the field of Fabry disease research. Previously, an inadequate understanding of this disease and the high heterogeneity of each patient's symptom manifestations led to delayed diagnosis, which resulted in progression to irrevocable cardiovascular events. Therefore, our hope for the future is to combine our efforts, gather more information, and share it freely with our medical peers to ensure widespread awareness of Fabry disease in order to facilitate timely diagnosis that can help save more patients.


References

01. Hwu WL, Chien YH, Lee NC, Chiang SC, Dobrovolny R, Huang AC, Yeh HY, Chao MC, Lin SJ, Kitagawa T, Desnick RJ, Hsu LW. Newborn screening for Fabry disease in Taiwan reveals a high incidence of the later-onset GLA mutation c.936+919G>A (IVS4+919G>A). Hum Mutat 2009;30:1397-1405.
02. Lin HY, Chong KW, Hsu JH, Yu HC, Shih CC, Huang CH, Lin SJ, Chen CH, Chiang CC, Ho HJ, Lee PC, Kao CH, Cheng KH, Hsueh C, Niu DM. High incidence of the cardiac variant of Fabry disease revealed by newborn screening in the Taiwan Chinese population. Circ Cardiovasc Genet 2009;2:450-456.
03. Hsu TR, Hung SC, Chang FP, Yu WC, Sung SH, Hsu CL, Dzhagalov I, Yang CF, Chu TH, Lee HJ, Lu YH, Chang SK, Liao HC, Lin HY, Liao TC, Lee PC, Li HY, Yang AH, Ho HC, Chiang CC, Lin CY, Desnick RJ, Niu DM. Later onset Fabry disease, cardiac damage progress in silence: experience with a highly prevalent mutation. J Am Coll Cardiol 2016;68:2554-2563.
04. Hung CL, Wu YW, Lin CC, Lai CH, Jyh-Ming Juang J, Chao TH, Kuo L, Sung KT, Wang CY, Wang CL, Chu CY, Yu WC, Hou CJ. 2021 TSOC Expert Consensus on the Clinical Features, Diagnosis, and Clinical Management of Cardiac Manifestations of Fabry Disease. Acta Cardiol Sin 2021;37:337-354.
05. Wang WT, Sung SH, Liao JN, Hsu TR, Niu DM, Yu WC. Cardiac manifestations in patients with classical or cardiac subtype of Fabry disease. J Chin Med Assoc 2020;83:825-829.
06. Lu DY, Huang WM, Wang WT, Hung SC, Sung SH, Chen CH, Yang YJ, Niu DM, Yu WC. Reduced global longitudinal strain as a marker for early detection of Fabry cardiomyopathy. Eur Heart J Cardiovasc Imaging 2022;23:487-495.
07. Ommen SR, Mital S, Burke MA, Day SM, Deswal A, Elliott P, Evanovich LL, Hung J, Joglar JA, Kantor P, Kimmelstiel C, Kittleson M, Link MS, Maron MS, Martinez MW, Miyake CY, Schaff HV, Semsarian C, Sorajja P. 2020 AHA/ACC Guideline for the Diagnosis and Treatment of Patients With Hypertrophic Cardiomyopathy: A Report of the American College of Cardiology/American Heart Association Joint Committee on Clinical Practice Guidelines. Circulation 2020;142:e558-e631.
08. Chang HC, Kuo L, Sung SH, Weng CY, Chen CK, Niu DM, Chen SA, Yu WC. Left ventricular apical aneurysm in Fabry disease: implications for clinical significance and risk stratification. J Am Heart Assoc 2023;12:e027041.

# Fabry Disease Case Book

## Case 1:

Late-onset Fabry Disease with left ventricle hypertrophy and chronic kidney disease with proteinuria

賴志泓醫師

## *Clinical pearls*

- Fabry disease may not be rare in Taiwan, especially the late-onset type.
- The diagnosis of Fabry disease is often delayed because of the heterogeneity of clinical manifestations and multiorgan involvement.
- Structural and functional abnormalities of the heart can be detected earlier than clinical symptoms.
- Routine monitoring of electrocardiograms in patients with CKD may be helpful for early detection of cardiovascular diseases.
- Complete systemic evaluation is necessary for the diagnosis and treatment of Fabry disease.

## *Patient profile*

Case presentation

- 55-year-old male, initially visited the nephrology clinic because abnormal renal function was noted in 2015
- Patient refused renal biopsy, started the use of losartan and pentoxifylline
- Initial diagnosis: chronic kidney disease, with a creatinine level of 1.63 mg/dL (eGFR: 48.23 mL/min/1.73 m2), UPCR level of 0.26 mg/g
- Proteinuria and renal function continued to deteriorate despite treatment
- The patient joined the Taiwan Precision Medicine Initiative project in 2020, and genetic diagnosis of Fabry disease was made using Biobank genome-wide genotyping in 2022.
- Referred to cardiology clinic for further evaluation; no significant symptom complaint but mild chest tightness present at times during intensive exercise, creatinine level was 2.69 mg/dL, UPCR level was 657.38 mg/g.
- The final diagnosis was late-onset Fabry disease with concentric non-obstructive LVH and CKD with overt proteinuria.
- Receiving enzyme replacement therapy (agalsidase beta 70 mg biweekly) after diagnosis

## Past history

- HBV carrier without any specific treatment
- Extracorporeal shock wave lithotripsy for renal stone removal

## Physical examination

- No angiokeratoma
- No peripheral neuropathy symptoms or neuropathic pain
- No visual or hearing defects

## *Laboratory panels*

### Figure 1

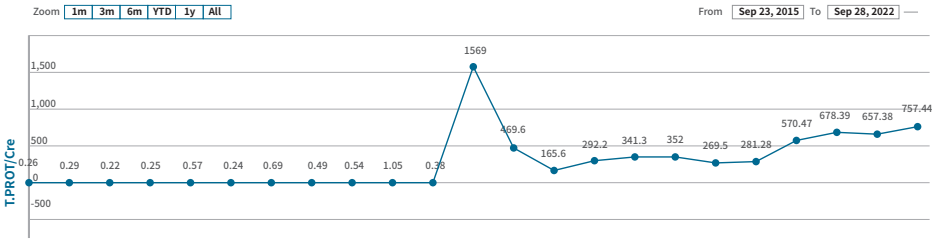


### Figure 2

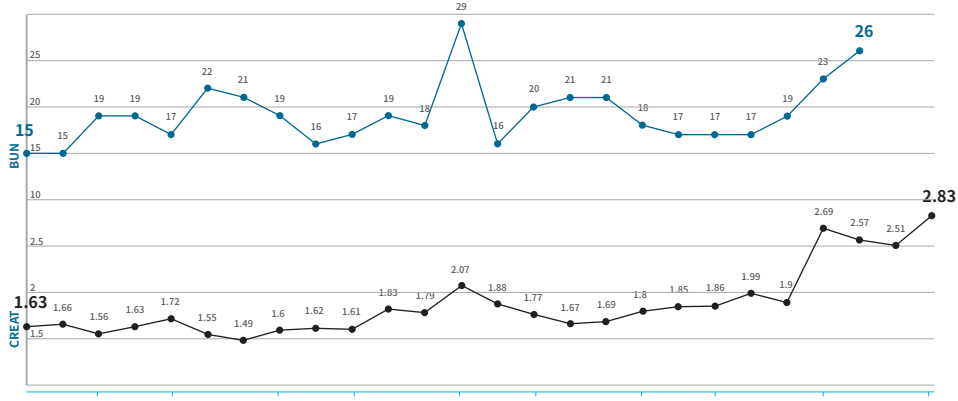


- Persistent abnormal urine protein/creatinine ratio (UPCR) level since 2015, with one flare-up episode in 2017, followed by gradual progression
- BUN and creatinine level changed along with UPCR level

## Figure 3

| Systemic : | Reference | Date 1(baseline) | Date2 |
|---|---|---|---|
| Hb | 12-17 g/dL | 13 | |
| DBS Lyso-Gb3 | <0.31 ng/ml | 10.26 ↑ | |
| GAL-a enzyme activity | >15.3 µmol/L/h | 0.16 ↓ | |
| GLA mutation | -- | *GLA:* c.902G>A | N/A |

- High dried blood spot lysosome globotriaosylsphingosine level and low α-galactosidase A enzyme activity, consistent with Fabry disease
- GLA: c.902G>A mutation

## Figure 4

| Cardiac | Reference | Date 1(baseline) | Date2 |
|---|---|---|---|
| Troponin T | <14 ng/dl | 23.79 ng/l ↑ | |
| NT pro-BNP | | 3226 pg/ml ↑ | |
| 6MWT (if any) | | 458 m | |

- High cardiac enzyme level indicating cardiac involvement

## *Chest radiograph*

## Figure 5

- No significant heart volume enlargement

## *Electrocardiography*

### Figure 6

- Sinus rhythm with left ventricular hypertrophy and strain pattern

## *Pure tone audiometry*

- High frequency hearing impairment

## *Cardiac echography*

Figure 7–12

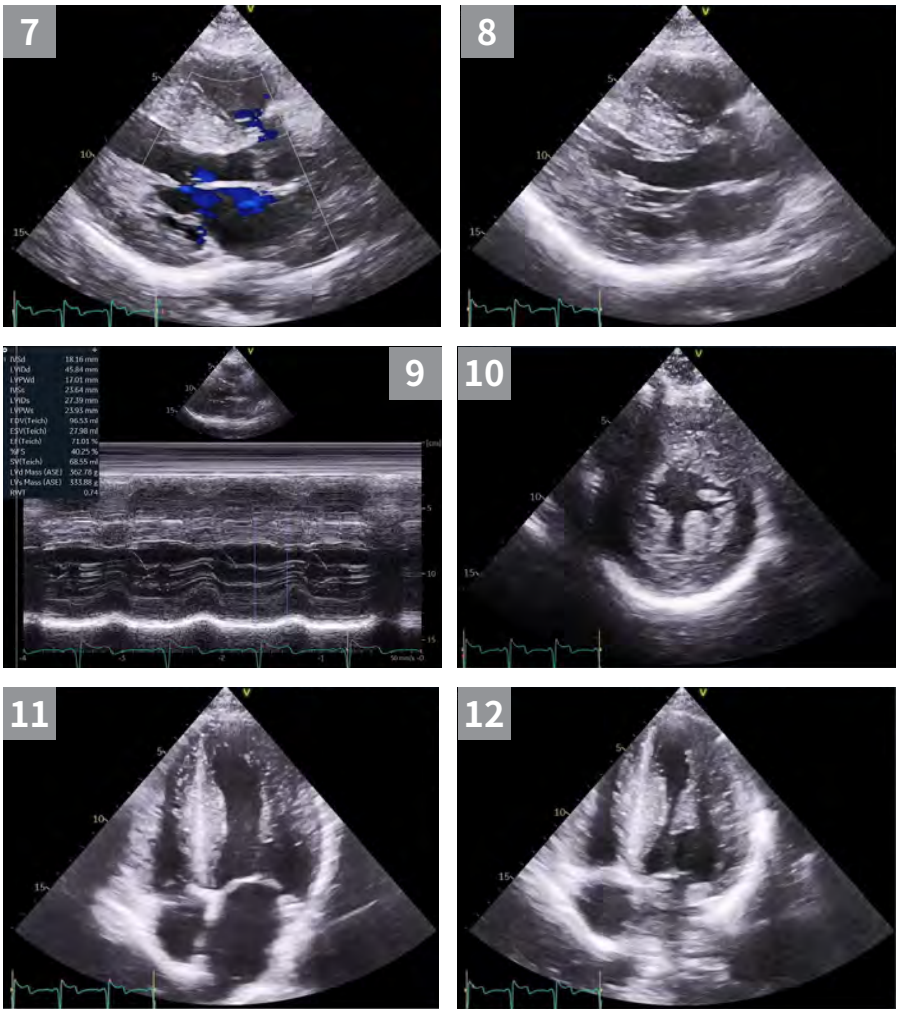


- Concentric left ventricular hypertrophy, with papillary muscle, right ventricle hypertrophy, and left atrium enlargement
- E/E' ratio average: 11.630; left ventricular ejection fraction: 60%

## Figure 13–16

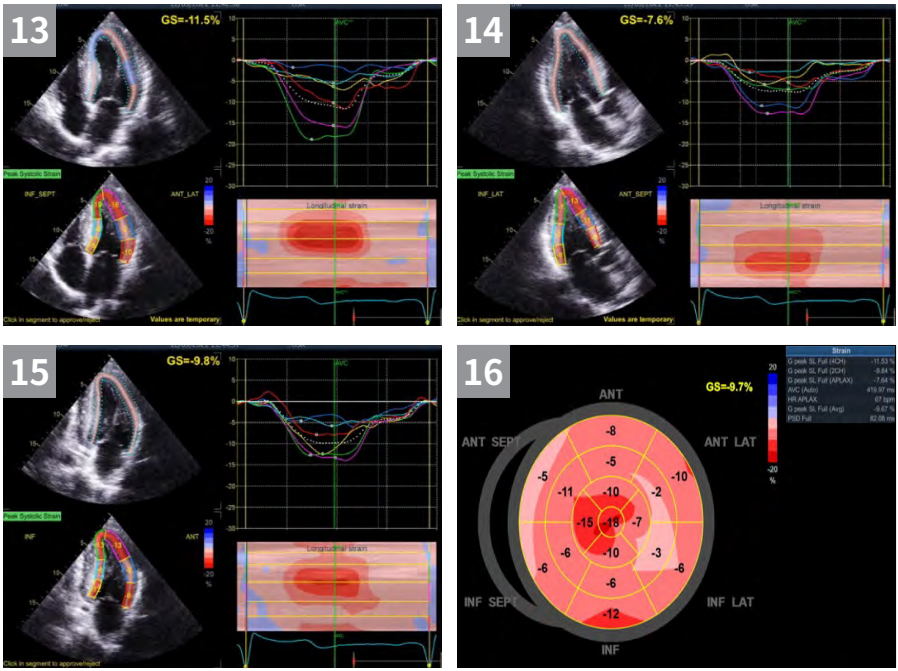


- Diffusely reduced global longitudinal strain, especially in the posterior lateral wall and septum

## *Cardiac magnetic resonance imaging*

Figure 17–19

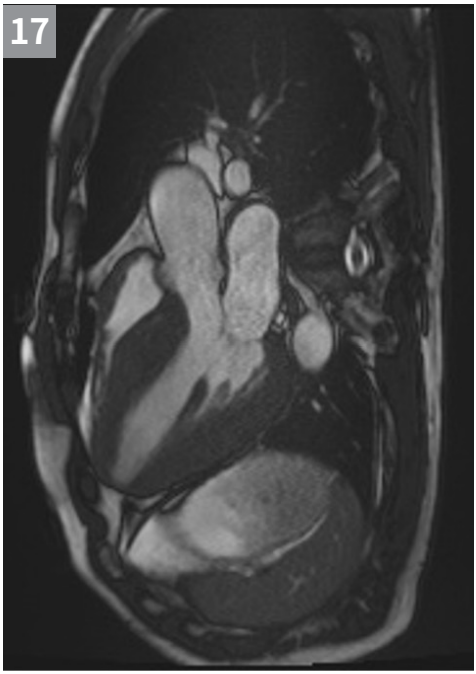


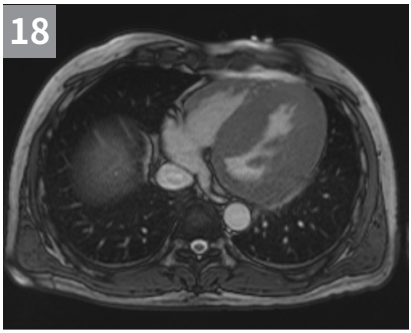


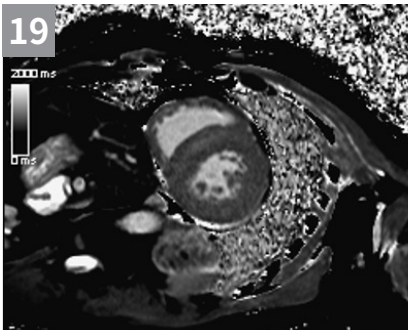


- Concentric left ventricular hypertrophy

## Figure 20–24

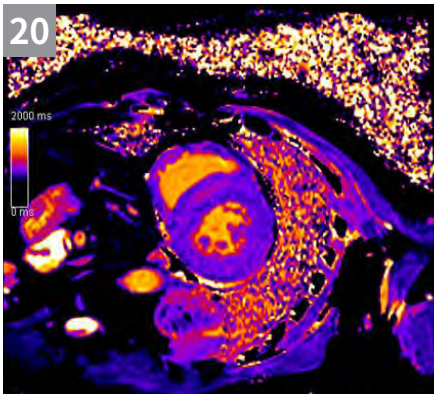


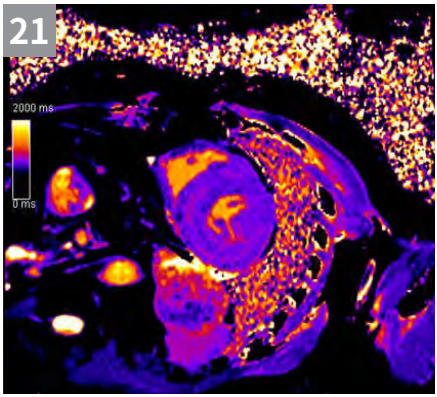


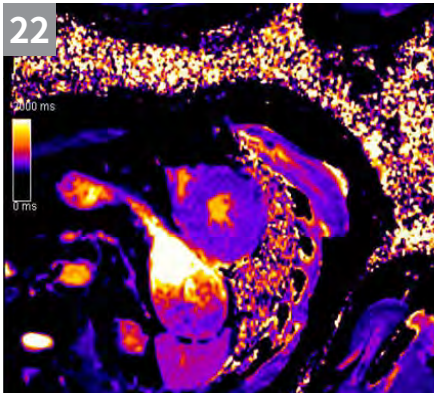


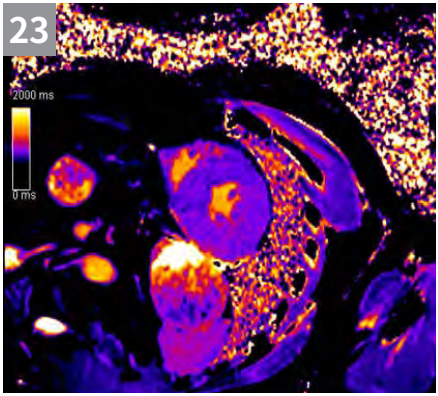


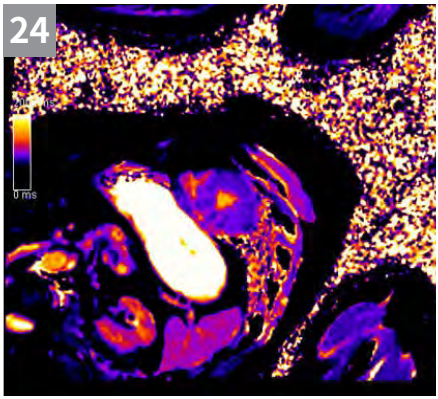


- Diffuse hypertrophy with higher T1 signal in the septal wall

## *Renal biopsy*

Figure 25–26

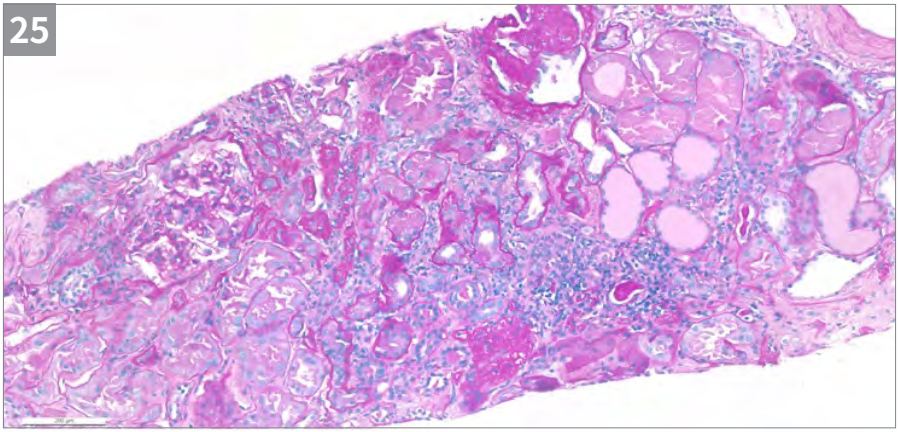


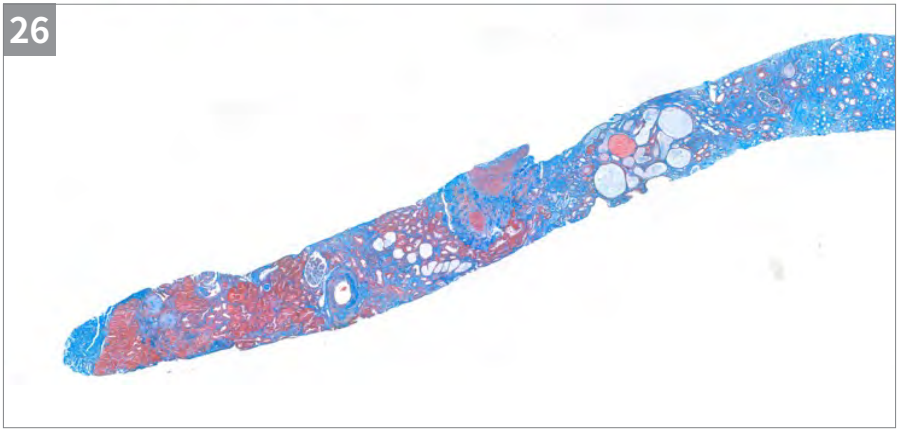


- Tubular atrophy with interstitial fibrosis and inflammation

## Figure 27–28

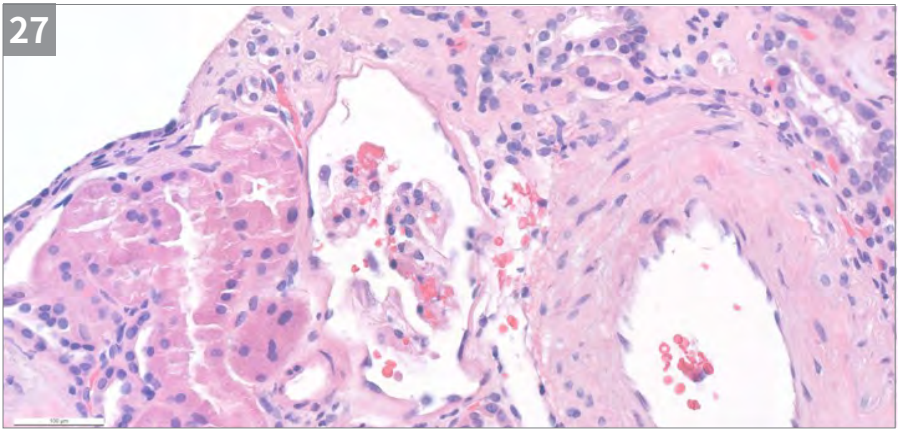


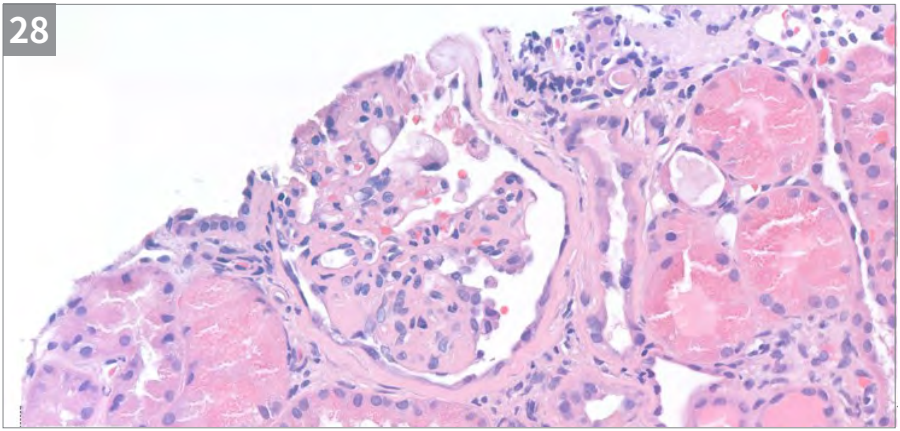


- Focal segmental glomerulosclerosis and foamy podocytes

Figure 29–30

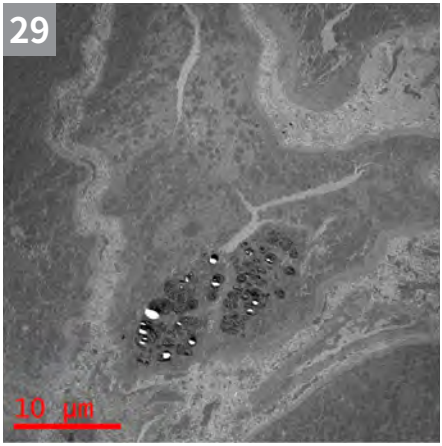


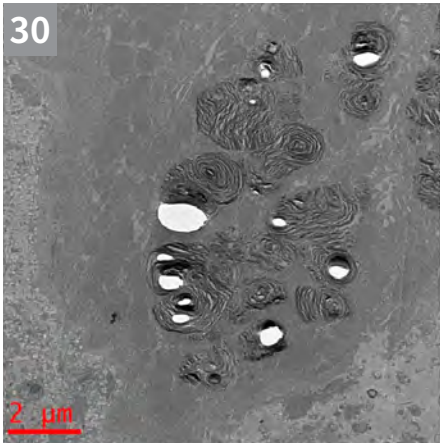


- Diffused “zebra bodies” in the tubular area

## *Discussion*

- Prevalence of Fabry disease varies in Taiwan. Newborn screening showed a 0.08% prevalence with 82% prevalence of the IVS4 cardiac subtype, whereas our hospital-based study found a 0.2% prevalence rate with 93% prevalence of the IVS4 cardiac subtype. In high-risk screening, the prevalence was as high as 2% in the LVH population, with an 81% prevalence of the IVS4 cardiac subtype.
- Because of the relatively high prevalence of Fabry disease in Taiwan, it should be considered as one of the differential diagnoses for patients with hypertrophic cardiomyopathy, regardless of whether other organs are involved.
- Owing to the heterogeneity of clinical manifestations, the diagnosis of Fabry disease is often delayed, which means that clinicians should be familiar with and aware of both cardiac and extra-cardiac manifestations to improve the diagnosis of Fabry disease.
- Fabry disease is characterized by chronic renal dysfunction and proteinuria. However, in this case, proteinuria was not initially significant and did not progress rapidly. "Therefore", the sudden deterioration of renal function may suggest other causes of kidney damage accompanying Fabry disease.

- Pathological findings revealed more prominent tubular fibrosis and inflammation than in foamy podocytes, suggesting advanced Fabry nephropathy.
- bOrgan damage would progress if Fabry disease is mis-diagnosed and untreated.
- Considering cardiovascular risk in patients with CKD, routine electrocardiography and/or echocardiography is recommended.
- Early cardiac or renal involvement symptoms of Fabry disease may be subtle; however, structural and functional abnormalities can be detected by certain examinations such as electrocardiography and echocardiography.
- Decreased GLS on echocardiography could occur earlier than wall motion abnormalities and reduced left ventricular systolic function.
- As Fabry disease affects multiple organs, complete evaluation is necessary for diagnosis and treatment.

## *References*


1. Acta Cardiol Sin (2021) 37:337–354.
2. Journal of Echocardiography (2021) 19:71–79.

# Fabry Disease Case Book

## Case 2:

An Unexplained left ventricular hypertrophy case finally diagnosed as Classic type Fabry disease

林圀宏醫師

## *Clinical pearls*

- Early diagnosis of Fabry disease and early treatment are the key points of efficacy of enzyme replacement therapy.
- Awareness of Fabry disease is crucial for early diagnosis, thus, we should pay more attention to patients with unexplained LVH.
- Finding out extra-cardiac symptoms as possible could be helpful for diagnosis of Fabry disease.
- Fabry disease is a genetic family disease. Well educating and encouraging the patients' family members to receive screening could be helpful for early diagnosis.

## *Patient profile*

### Case presentation

- 53-year-old female, working in Hsinchu Science Park
- Chief complaint: ECG showing LVH found by health examination
- Confirmed LVH and hypertension (around 140/90 mmHg) without other significant abnormality while 1st visit to cardiovascular clinic in 2019
- Blood pressure improved after titrating ARB dose (losartan 25 mg to 100 mg), however, ECG still showed LVH next year (2020)
- Patient also visited nephrology clinic due to proteinuria on and off
- Confirmed diagnosis of Fabry Disease in 2021/5
- Started agalsidase alfa*3/biweekly (0.2 mg/kg biweekly) treatment in 2021/8
- No adverse event reported and none of prophylactic antihistamine/hydrocortisone needed since 8th treatment infusion
- Started sweating, hands pain and foamy urine improved after treatment

### Past history

- Unexplained LVH and well-controlled hypertension for several years
- Once hearing loss episode 5-6 years ago
- Unexplained neuropathic pain (hands) since teenage
- Hypohidrosis

## Physical examination

- No angiokeratoma

## *Laboratory panels*

### Figure 1.

| Systemic: | Reference | Jun., 2021 | May., 2022 | Reference |
|---|---|---|---|---|
| Hb | 12-17 g/dL | 15.1 | | |
| Plasma Lyso-Gb3 | <1.8 ng/ml | **4.9** | **5.3** ng/ml | <2.6 ng/ml |
| GALa enzyme activity | >15.3 μmol/L/h | **3.5** | | |
| GLA mutation | -- | c. 539 T> G | C. 539 T> G | |

- Before treatment (2021/6): high lysosome Gb3 level and low α-GAL A enzyme activity, consistent with Fabry disease
- Confirmed c.539T>G mutation, considered as classic type Fabry disease

### Figure 2.

| Renal | Reference | Jun., 2021 | 2022/2/8 | 2022/5/18 |
|---|---|---|---|---|
| eGFR | >90 mL/min/1.73m | **72** | **81** | |
| ACR | | | 235.44 ug/mg | 182.04 ug/mg |
| Proteinuria: Protein/(Creatinine/1000) | | **336.37** mg/dL | 217.31 mg/g | |
| UA | Negative | **100** mg/dL | Negative | |

- Before treatment (2021/6): decreased eGFR and prominent urine protein
- Renal function improved after treatment

### Figure 3.

| Cardiac | Reference | Jun., 2021 | 2022/5 |
|---|---|---|---|
| Troponin I or T | 0-0.0175 ng/mL | NA | **0.0388** ng/mL |
| NT pro-BNP | <125 pg/mL | NA | 71 pg/mL |

- No available baseline data of cardiac enzymes, but mild troponin I elevation found after treatment

## *Electrocardiography*

### Figure 4.

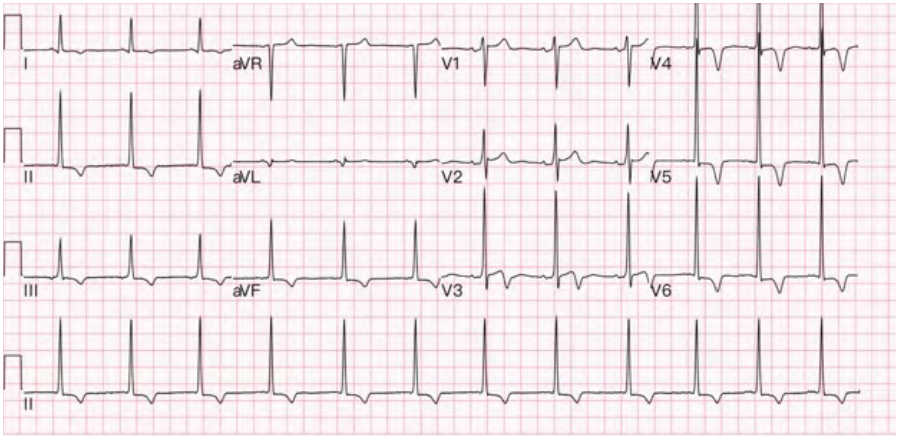


- Before treatment (2019): LVH with inverted T wave, PR interval: 120 ms.

### Figure 5.

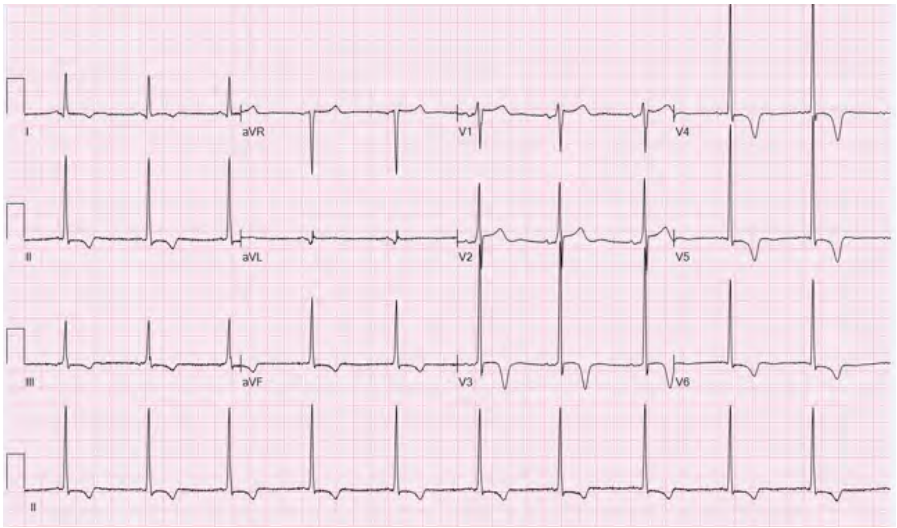


- LVH with inverted T wave, PR interval: 134 ms.
- No significant change after treatment

## *Cardiac echography*

### Figure 6.

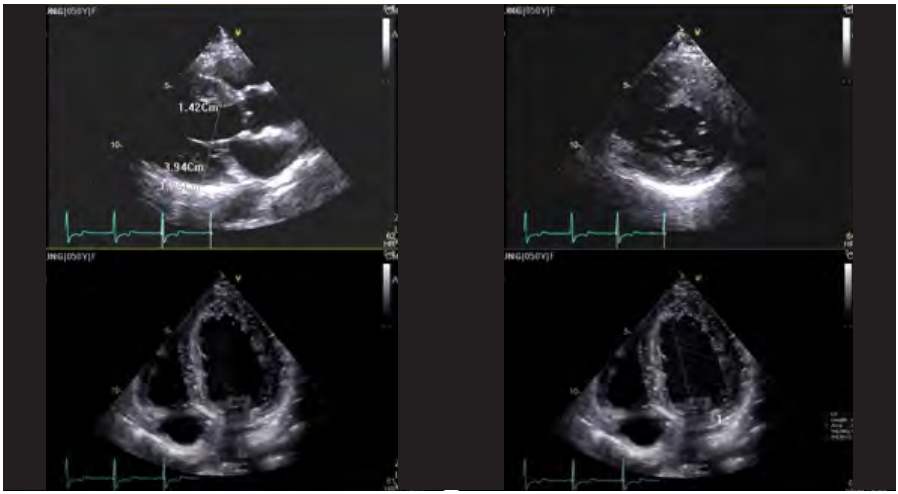


- Before treatment (2019): septal hypertrophy, 1.4 cm in thickness

### Figure 7.

- Septal wall thickness decreased to 1.3 cm after treatment (2022)
- No significant change in EF

## *Pedigree*

### Figure 8.

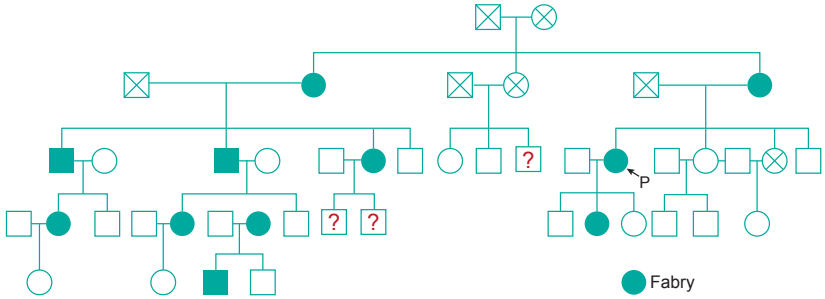


- Patient's mother, aunt, three cousins, and some other family members were diagnosed as Fabry disease through screening

### Figure 9.

| | Enzyme | | Lyso-Gb3 | | Gene |
|---|---|---|---|---|---|
| M1(61yr) | <2.8 μmol/L/h | Rf:>15.3 μmol/L/h | 24.2ng/ml | Rf:<1.8 ng/ml | c. 539 T>G |
| F1(77yr) | 9.7μmol/L/h | | 4.0ng/ml | | |
| F2(54yr) | 3.8μmol/L/h | | 7.7ng/ml | | |
| F3(53yr) | 3.5μmol/L/h | | 4.9ng/ml | | |
| F4(32yr) | <2.8μmol/L/h | | 5.6ng/ml | | |
| F5(31yr) | 10.9μmol/L/h | | 3.5ng/ml | | |
| F6(29yr) | 17.8μmol/L/h | | 2.0ng/ml | | |
| M2(59yr) | -- | -- | 34.24ng/ml | Rf:<0.31 ng/ml | |

- All family members have the same genetic mutation
- However, each family member of different gender and age has varied enzyme activity and clinical symptoms

## Discussion

- In this patient, the major complaint is unexplained LVH without associated symptoms for several years, even under well hypertension control, which means we should be aware of the cause of LVH, trying to exclude Fabry disease.
- We may see Fabry disease patients with typical LVH pattern on ECG, however, the specificity of this ECG abnormality is not enough to diagnose Fabry disease.
- For classic Fabry disease, there are always multiple system organ involved. Finding out extra-cardiac symptoms and signs (for example, proteinuria, neuropathic pain or hypohidrosis) is important for early diagnosis of Fabry disease.
- Each Fabry disease patient means a group of underdiagnosed family member. If the patient is willing to convince other family members to receive Fabry disease screening, we can recognize many patients earlier.
- Although the whole family shares the same genetic mutation, they could still have different phenotype. In this patient' s family, two male members have more severe clinical presentation, especially renal insufficiency.
- Considering the cost-effectiveness of ERT, close follow-up the efficacy and safety of the treatment for each patient is necessary.

## References


1. Catana CS, et al. Revista Romana de Medicina de Laborator. 2011;19(4):367-372.
2. Chien YH, et al. Orphanet J Rare Dis. 2020;15(1):38.

# Fabry Disease Case Book

## Case 3:

Fabry disease with complete atrioventricular block

莊文博醫師

## *Clinical pearls*

- For patients with complete AV block when unexplained left ventricular hypertrophy is present, further screenings for Fabry disease may be warranted, .
- Gb3 accumulation was observed in all types of cardiac cell , including cardiac conduction system cells.
- Enzyme replacement therapy play pivotal role in alleviating Fabry disease progression.
- Whether Fabry disease is associated with pacemaker-induced cardiomyopathy, and if physiological pacing may prevent pacemaker-induced cardiomyopathy, remains to be explored.

## *Patient profile*

Case presentation

- 57-year-old male
- Chief complaints: chest tightness with exertional dyspnea since three weeks; syncope after climbing up-staris three days prior.
- At presentation, EKG showed complete AV block and LVH.
- Considering the patient with LVH but had no history of hypertension, a Dry-blood spot (DBS) test was performed; Fabry disease with cardiac variant was diagnosed in December 2021 with c.640-801 G>A mutation undisclosed.
- During this hospitalization, permanent pacemaker (dual-chamber rate-modulated mode with right ventricular septal lead position) was implanted for complete AV block, and the patient' s clinical symptoms were greatly relieved.
- Due to the lack of electron microscopy equipment at the Far East Memorial Hospital, the patient was referred to the National Taiwan University Hospital for further Fabry survey which included endomyocardial biopsy and tissue pathology evaluation.
- However, due to the COVID-19 pandemic, his endomyocardial biopsy and cardiac MRI were not completed until October 2022.
- His physical exmaination showed no ophthalmic disorders, however bilateral mild sensorineural hearing loss was found during ENT consultation
- RT with agalsidase alfa was started after application was approved.
- After initiation of ERT, He receivedregular clinic-visit for ERT every two weeks; in addition, cardiac biomarkers,GLA enzyme activity, echocardiography, and cardiac MRI were followed as needed.

## Past history

- Poliomyelitis with left lower limb atrophy
- Herniation of intervertebral disc of C6-7, status post-operation
- Hepatitis B carrier

## Physical examination

- Normal blood pressure (blood pressure 115/75 mmHg)

## *Laboratory panels*

### Figure 1-3.

| Systemic: | Reference | Nov., 2021 | Aug., 2022 |
|---|---|---|---|
| Hb | 13-17 g/dL | 16.6 | 13.4 |
| Plasma Lyso-Gb3 | <1.8 ng/ml | **4** | **4.9** |
| GAL-a enzyme activity | >15.3 μmol/L/h | **<2.8** | **<2.8** |
| GLA mutation | -- | **c. 640-801 G>A** | |
| **Renal** | **Reference** | **Nov., 2021** | **Nov., 2022** |
| Creatinine | 0.7~1.3 mg/dl | 0.74 | 0.72 |
| eGFR | >60 mL/min/1.73m | 109 | 112 |
| proteinuria | <15 | - | 6.1 |
| microalbumin | 0.00-3.00 | - | 0.53 |
| **Cardiac** | **Reference** | **Nov., 2022** | **Nov., 2022** |
| Troponin T | <14.0 ng/L | **18.3** | **14.7** |
| NT pro-BNP | <125 | 64 | 93 |
| 6MWT | | | 272M |

- High plasma lysosome Gb3 level and low GAL-a enzyme activity, compatible with Fabry disease
- Confirmed Fabry diagnosis gene test
- Normal renal function without proteinuria
- Slightly higher Troponin T level, with no significant NT-proBNP elevation after one year of diagnosis

## *Six-minute walk test*

Figure 4.

Predicted 6 MWT in middle-age and elderly patient: 700.62 M
Supplemental oxygen during the test: nil.
Gait aid: nil.
Predicted HR: 162 bpm

| Time | Blood pressure | SpO2 | Heart rate | Dyspnea/Fatique |
|---|---|---|---|---|
| Rest | 124/88mmHg | 98% | 63 | 0/0 |
| 1 | | 99% | 87 | 0/0 |
| 2 | | 98% | 94 | 0/0 |
| 3 | | 98% | 91 | 0/0 |
| 4 | | 97% | 91 | 2/2 |
| 5 | | 98% | 93 | 2/2 |
| 6 | | 98% | 101 | 2/2 |
| Recovery | 142/87mmHg | 98% | 74 | 2/2 |

Total distance: 272 M
Percent predicted: 38.8%

- Short total distance but no prominent heart rate change during walk test (2022-11)

## *Chest radiograph*

Figure 5.

- Baseline, before symptoms appeared (2016): No significant heart volume enlargement

Figure 6.

- Obtained after pacemaker implantation (2021): Heart volume slightly enlarged compared with baseline (2016)

## *Electrocardiography*

### Figure 7.

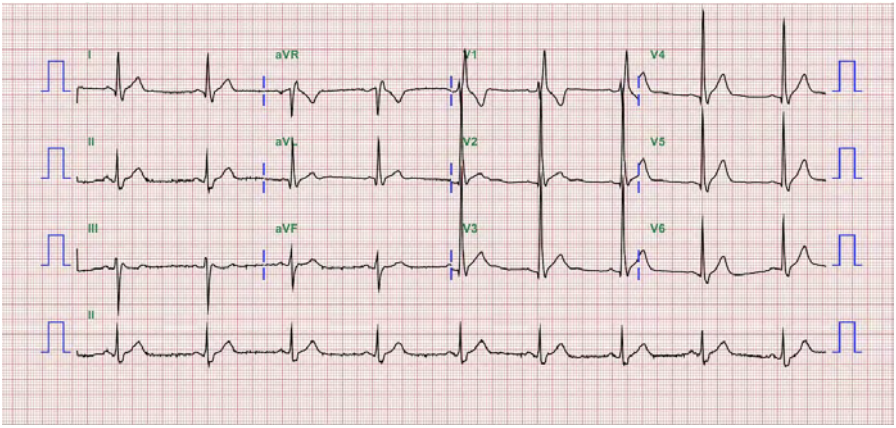


- Baseline, before symptoms appeared (2016)
- Sinus bradycardia, heart rate 54 beats per minute
- Left ventricular hypertrophy
- Right bundle branch block
- PR interval within normal range

### Figure 8.

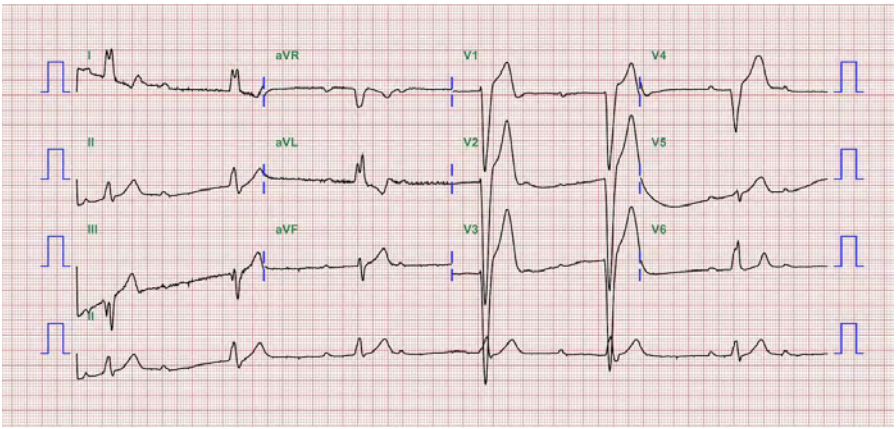


- (2021.11)
- Complete AV block
- Escape rhythm with left bundle branch block morphology

## Figure 9.

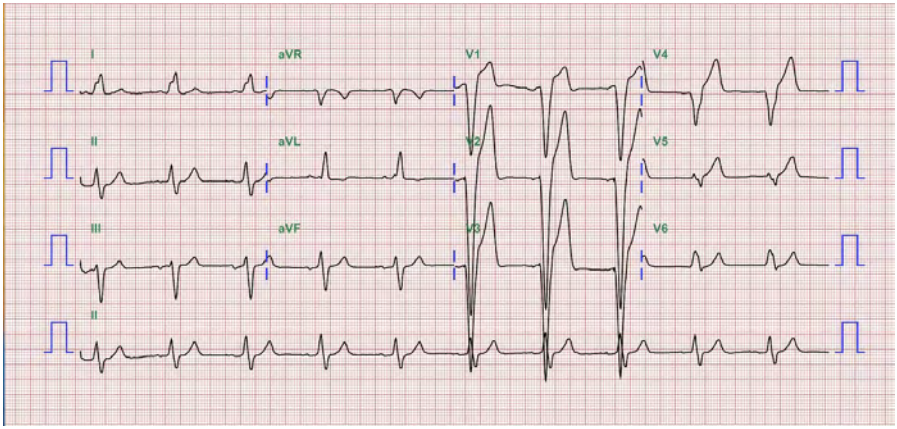


- After pacemaker implantation (2022.11)
- Atrial sensing, ventricular pacing rhythm
- QRS showed Left bundle branch block pattern under pacemaker pacing
- QRS duration: 181 ms.

## *Pacing*

### Figure 10.

Diagnostics-Timing (1st interrog.)

Rate histegrams [% time]

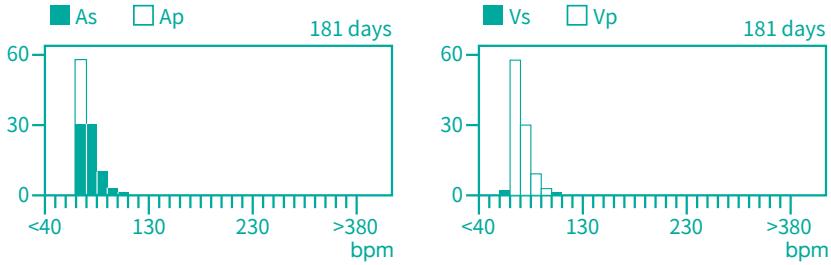


Event episodes and events
Mode switching burden [%]

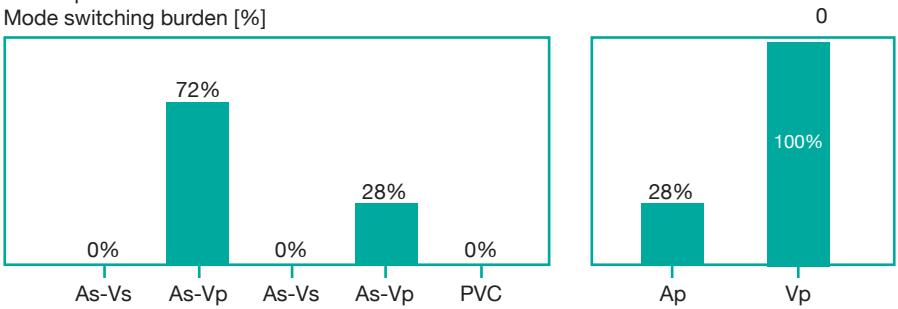


Pacing trends

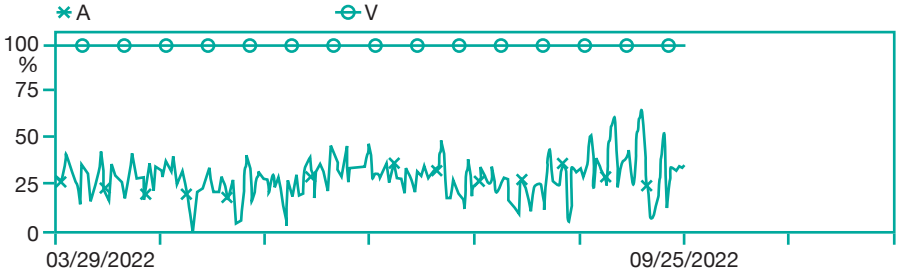


- 100% ventricular pacing (2022-9)

## *Cardiac echography*

Figure 11-12.

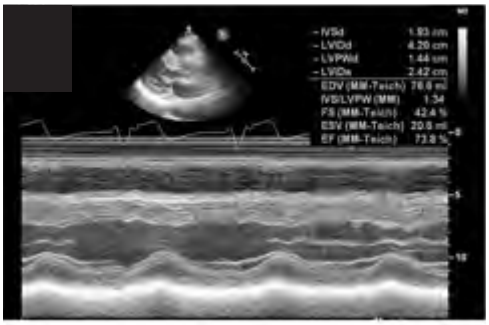

- (2021.11)
- Left ventricle eccentric hypertrophy
- LVEF: 74%

## *Cardiac magnetic resonance imaging*

- Asymmetric wall hypertrophy of the left ventricular wall, up to 2 cm in the mid-anteroseptal region.
- Patches of myocardial delayed hyperenhancement at the apical to mid-septal and lateral segments of the left ventricular myocardium.
- Decreased native T1 value of the left ventricular myocardium, consistent with Fabry disease.
- Mild hypokinesia of the septal left ventricular wall and dyskinesia of the apical septal wall.

## *Cardiac biopsy*

- Morphology and immunohistochemical staining results: hypertrophic cardiomyocytes, suggestive of Fabry disease; focal cytoplasmic vacuoles positive for toluidine blue and interstitial fibrosis positive for Masson's trichrome staining.
- Electron microscopic findings: degenerated Zebra and myelin bodies, consistent with Fabry disease.

## *Pedigree*

Figure 13.

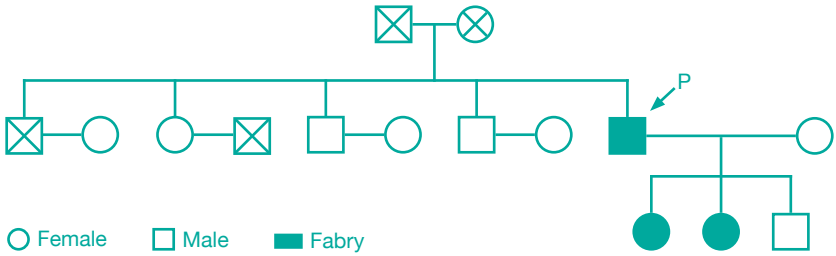


- All family members received genetic tests and only the patient's two daughters are positive for the same genetic mutation.
- No significant cardiac symptoms nor laboratory abnormality appeared in the patient's daughters; one of them has bilateral mild sensorineural hearing loss.

## *Discussion*

- In 2022, the patient's troponin T level was slightly higher, but NT-proBNP was not significantly increased, which may means that even with mild cardiac injury by Gb3 accumulation, his heart function then remained well compensated. As for the short walking distance and minor fluctuation of his heart rate, which may due to his polio condition or Fabry disease-related chronotropic incompetence. Long-term follow-up is needed to evaluate whether exercise intolerance will be improved after PPM and HRT treatment.
- With 100% ventricular backup pacing, there might be a higher incidence of pacemaker-induced cardiomyopathy in this patient in the future.
- EKG changes in Fabry disease may include short PQ intervals, repolarization abnormalities, bradycardia, chronotropic incompetence, and AV blocks. AV block

and bundle branch blocks are especially more commonly seen in the advanced stages of Fabrydisease.

- Gb3 accumulation in Fabry disease has been found in all types of cardiac cells—cardiomyocytes, endothelial cells, smooth muscle cells, coronary arteries, aorta, and valve tissues, including conduction system cells.[1] In this patient, although the endomyocardial biopsy pathology study did not identify any Gb3 accumulation in the conductive system, the clinical symptoms and EKG findings of the conduction block were still most likely due toFabry disease.
- One study indicated that the without incremental QRS duration prolongation throughout the course of Fabry disease predicts the absence of bradyarrhythmia.[2] Thus, the requirement for pacemaker implantation may be lower in Fabry disease if the QRS duration is stable. In contrast, patients with baseline QRS duration > 120 ms were more likely to have pacing requirements independent of EKG morphology or rhythm.[2] Monitoring QRS intervals for patients with Fabry disease may be considered.
- One case report indicated that Fabry disease-related first-degree AV block can be reversed after ERT. [3,4] Howevere, whether early diagnosis and prompt treatment with ERT for Fabry disease-related AV block may do help to prevent further deterioration of conduction system function remains further investigation.

## *References*


1. Cardiovascular Pathology 19 (2010) 293–301.
2. J Cardiovasc Electrophysiol. 2022;33:1072–1078.
3. South Med J. 2003 Feb;96(2):212-3.
4. Arch Intern Med 2009 Nov 9;169(20):1925-6.

# Fabry Disease Case Book

## Case 4:

A patient with classic Fabry disease due to anti-drug antibodies formed during enzyme-replacement therapy

施懿恩醫師

## *Clinical pearls*

- Risk factors for formation of neutralizing ADA include male sex, previous drug-related infusion reactions, and high titers of anti-drug IgG antibodies.
- Formation of neutralizing ADA should be considered in patients with Fabry disease when any of the following develop regardless of current ERT : new-onset cardiac symptoms and/or arrhythmias on EKG, new-onset microalbuminuria, acute limb pain, infection-related pain crisis, or progression of organ damage.
- If ADA-induced ERT insufficiency is suspected, both immediate medication change and prompt investigation for organ damage with appropriate intervention are critical.
- After being switched to another medication, patients should be closely monitored for resolution of clinical symptoms, lab abnormalities, and EKG changes.

## *Patient profile*

### Case presentation

- A 43-year-old asymptomatic man was diagnosed with classic Fabry disease in 2017 after his 10-year-old daughter was diagnosed with same disease, following development of an acute ischemic stroke.
- Agalsidase- beta (Fabrazyme) was started 1 month later. During the sixth course of ERT, the patient experienced a drug infusion reaction (fever of 39.1 ° C and chills). Slow infusion of agalsidase beta, diphenhydramine and dexamethasone was prophylactically administered in subsequent treatment courses.
- Treatment with agalsidase beta was continued despite the presence of circulating IgG antibodies against agalsidase beta (titer, 1:6400) due to the stability of his disease and the ability to control the infusion reaction.
- Approximately 3 years later (in 2020), the patient complained of a 2-day history of chest tightness. EKG at the time showed new-onset PVC. The patient was presumptively diagnosed with Fabry disease-induced arrhythmia, thought to be due to the formation of neutralizing ADA against agalsidase beta.
- A comprehensive cardiology consult found no evidence of end-organ damage.
- After agalsidase beta was replaced by agalsidase alfa (Replagal), the PVC resolved, the patient no longer reported any chest tightness, and no further infusion reactions occurred.

- Although microalbuminuria did develop after the medication change, it gradually and spontaneously resolved within 1 year.

## Medical history and review of systems

- Cardiovascular involvement: No CKD, hypertension, or diabetes mellitus.
- Peripheral or central nervous system involvement: Burning and tight sensation in both feet, like walking barefoot on the beach exposed to direct sunlight in summer since adolescence. No peripheral nervous system-related symptoms were present.

## Physical examination

- Angiokeratoma of both hands and the inguinal area.
- Anhidrosis, with hair follicle atrophy in both legs.
- Partial left-sided hearing impairment.

## *Laboratory panels*

### Figure 1.

| Systemic: | Reference | 2017011 |
|---|---|---|
| GAL-a enzyme activity | <10X | 40.57 |
| GLA mutation | -- | c.277G>A homozygote |

- GAL-a enzyme activity but c.277G>A missense mutation were found in 2017.

### Figure 2.

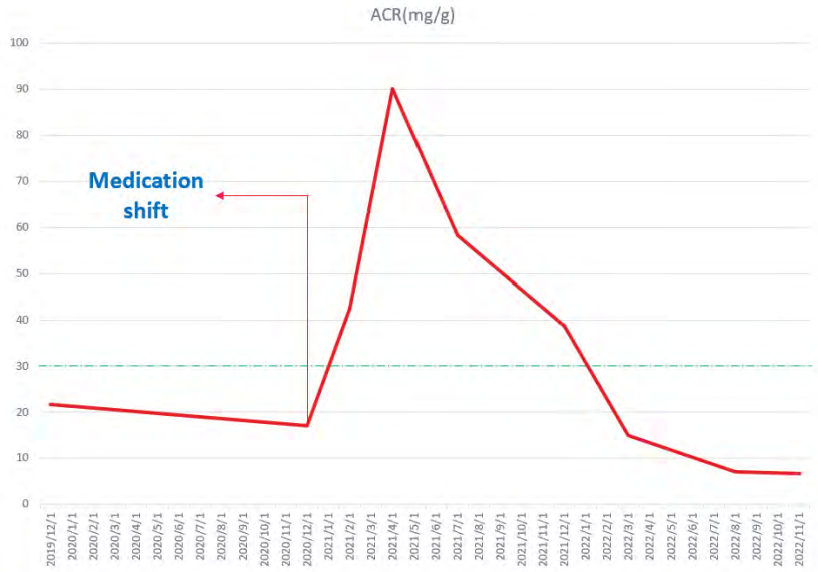


- A significant increase in albumin-to-creatinine ratio (ACR) within 100 days, from 17.07 mg/g to 90.1 mg/g
- In the following year of medication shift, ACR returned from 90.1mg/g to 14.9mg/g gradually, and then became even lower (6.76mg/g).

## Figure 3.

| Date | Lyso-Gb3 | (N>0.8ng/mL) | |
|---|---|---|---|
| 2019/2/15 | 22.7 | | 28X |
| 2019/12/16 | 48.87 | | 61X |
| 2021/2/19 | 32.2 | (N>2.6ng/mL) | 12X |

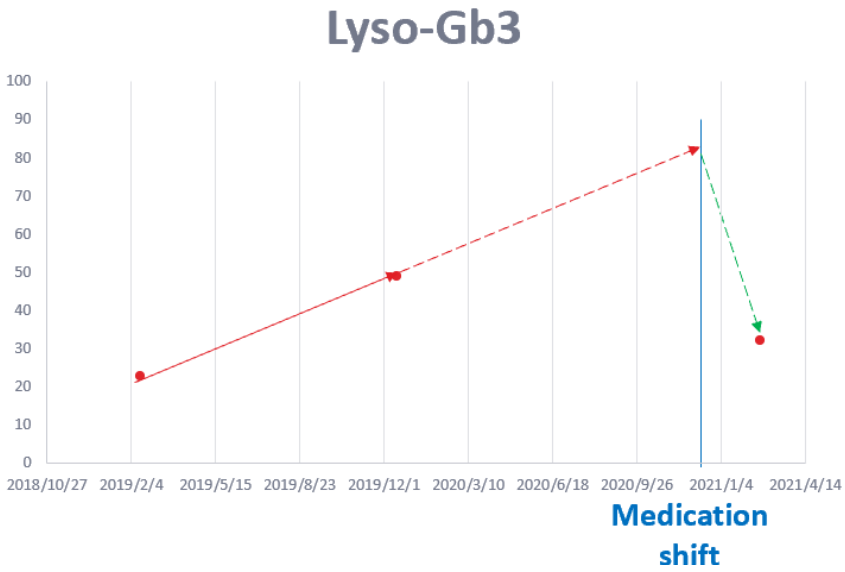


- Only three data of lyso-Gb3 concentration before and after medication shift are available. (The dashed line is assumed that linear association between lyso-Gb3 concentration and medication. Though we favored that the medication shift changed the direction of lyso-Gb3 curve, the actual time of direction change is unknown.)

## *Electrocardiography*

### Figure 4.

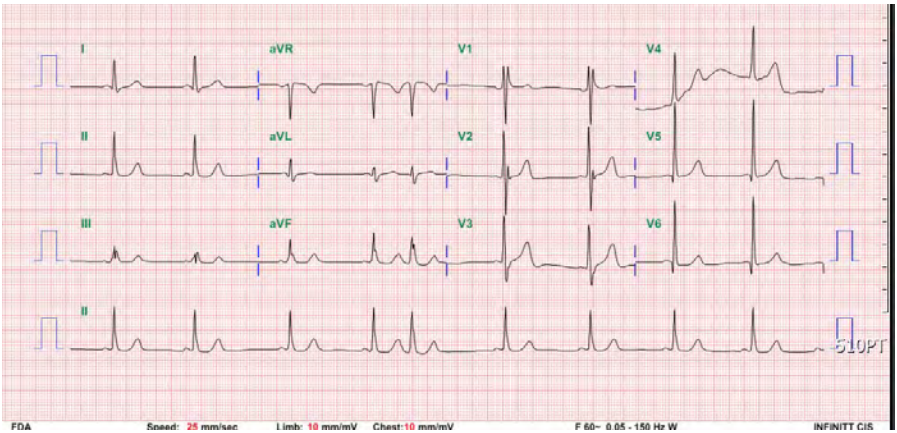


- EKG before medication shift (November 2020): New onset PVC

### Figure 5.

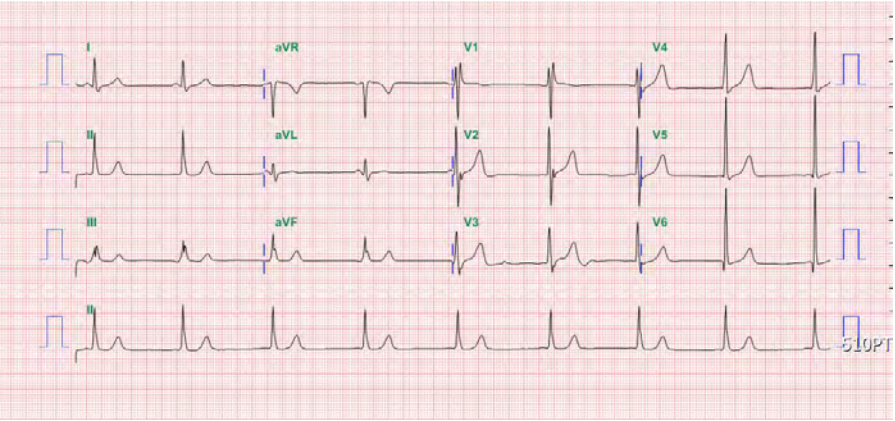


- EKG after medication shift (February 2021): Normalized morphology with no arrythmias

## *Sympathetic skin response test (2017)*

### Figure 5.

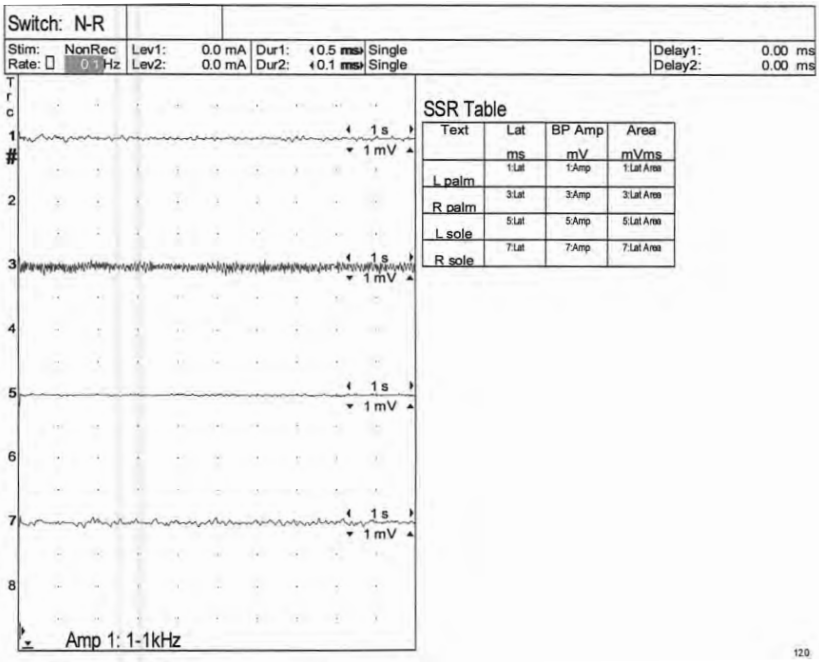


- No response of sympathetic skin response in four limbs, suggestive of severe small fiber neuropathy

## *Nerve conduction study (2017)*

### Figure 6

| Never and Site | Onset Latency | Peak Latency | Amplitude | Distance | Conduetion Veloeity |
|---|---|---|---|---|---|
| Median.L | | | | | |
| Wrist | 3.0 ms | 3.9 ms | 34 µV | 140 mm | 47 m/s |
| Elbow | 6.4 ms | 7.6 ms | 23 µV | 190 mm | 56 m/s |
| Ulnar.L | | | | | |
| Wrist | 2.8 ms | 3.8 ms | 55 µV | 140 mm | 50 m/s |
| Elbow | 6.0 ms | 7.5 ms | 25 µV | 160 mm | 50 m/s |
| Peroneal.L | | | | | |
| Ankle | 2.4 ms | 2.9 ms | 14 µV | 140 mm | 58 m/s |
| Sural.L | | | | | |
| Lower leg | 2.7 ms | 3.4 ms | 9 µV | 140 mm | 52 m/s |
| Peroneal.R | | | | | |
| Ankle | 2.8 ms | 3.8 ms | 9 µV | 140 mm | 50 m/s |
| Sural.R | | | | | |
| Lower leg | 3.7 ms | 4.6 ms | 19 µV | 140 mm | 38 m/s |
| Median.R | | | | | |
| Wrist | 3.1 ms | 4.2 ms | 28 µV | 140 mm | 45 m/s |
| Elbow | 6.4 ms | 7.8 ms | 24 µV | 170 mm | 52 m/s |
| Ulnar.R | | | | | |
| Wrist | 2.7 ms | 3.4 ms | 29 µV | 140 mm | 52 m/s |
| Elbow | 5.7 ms | 6.7 ms | 19 µV | 170 mm | 56 m/s |

- Essentially normal results, classical Fabry disease

## *24-hour Holter (2017)*

- Sinus rhythm, with a maximal heart rate of approximately 139 beats per minute at 7:20, minimal heart rate of approximately 54 beats per minute at 07:04.
- 90 supraventricular extrasystoles with episodes of PAF
- No AV block or long pause, no ST-T wave change

## *Cardiac echography (2017)*

- Mild aortic regurgitation with preserved left ventricular contractility

## *Pedigree*

Age of the patients in 2023

Abbreviation:

ET: enzyme replacement therapy;

FD: fabry disease

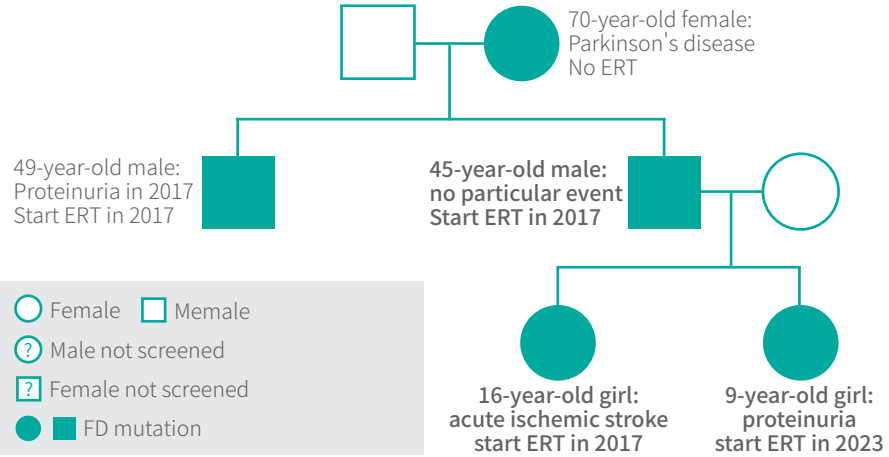

## Discussion

- Although this patient developed microalbuminuria immediately after starting agalsidase alfa, it is unlikely to be related to the medication change for two reasons. First, the increase in ACR occurred immediately after agalsidase alfa initiation, whereas the typical time to clinical response for ERT in Fabry disease is more than 6 months. Second, a gradual decrease in ACR occurred without intervention while continuing agalsidase alfa.
- This patient's eGFR increased from 112.67 mL/min/1.73 $m^2$ to 130.82 mL/min/1.73 $m^2$, potentially was indicative of early glomerular hyperfiltration phase in nephropathy due to Fabry disease as seen in one study.[1]
- IgE levels decreased from 420.7 IU/mL to 145.5 IU/mL, which may be associated with reduced infusion reactions.
- Elevated levels of IgG ADA are associated with a higher incidence of infusion reactions (89% for seropositive, 26% for seronegative, $p<0.01$)[2]. Patients treated with agalsidase beta (1.0 mg/kg every other week) have been shown to have both a higher incidence of circulating IgG ADA (80% vs. 40%, $p=0.005$)[3] and severe infusion reactions (67% vs. 19%, $p=0.004$)[2] compared to those treated with agalsidase alfa (0.2 mg/kg every other week).
- The differences in ADA formation rate between agalsidase alfa and agalsidase beta may be related to inherent chemical differences. Agalsidase alfa, produced in a human cell line, and agalsidase beta, produced in a Chinese hamster ovary cell line, have differences in glycosylation pattern, C-terminal amino acid chain, purity of preparation, and pharmacokinetic characteristics.[4]
- According to some studies, the reduction of plasma lyso-Gb3 concentration is dose-dependent for agalsidase-β,[5] but dose-independent for agalsidase-α.[6] Different patterns of dose-responsiveness may be related to varying potentials for ADA formation. The initial increase in lyso-Gb3 in the patient may have resulted from the reduced efficacy of the same dosage of agalsidase-β due to neutralizing ADA formation.

## References


1. Riccio E, et al. Nephron. 2019;141(1):10-17.
2. Smid BE, et al. Mol Genet Metab. 2013 Feb;108(2):132-7.
3. Vedder AC, et al. Mol Genet Metab. 2008 Jul;94(3):319-25.
4. Nisticò R, Pisani A. Recenti Prog Med. 2021 Oct;112(10):75e-84e.
5. Eng CM, et al. Am J Hum Genet. 2001 Mar;68(3):711-22.
6. Clarke JT, et al. Genet Med. 2007 Aug;9(8):504-9.

# Fabry Disease Case Book

## Case 5:

A patient of classic Fabry disease with hypertrophic obstructive cardiomyopathy

林志展醫師

## *Clinical pearls*

- Discrepancies in genotypes and phenotypes were more likely to occur in female patients with Fabry disease. Thus, in clinical practice, the possibility of classical Fabry disease for female patients only presenting with unexplained LVH and/or cardiac symptoms should not be completely excluded.
- HOCM is rarely observed in patients with Fabry disease in Taiwan, which differs from the observations of studies conducted in other countries.
- No fibrosis observed on cardiac magnetic resonance imaging may predict better treatment response and clinical outcomes.

## *Patient profile*

### Case presentation

- A 65-year-old female was referred to our hospital with precordial chest pain on April 1st, 2019.
- Her chest pain was not effort-related radiating to the back. No other symptoms were observed.
- EKG revealed a diffuse T-wave change, and echocardiography showed a dilated left atrium and interventricular septal hypertrophy. Thallium scan revealed small reversible myocardial ischemia.
- Based on an initial diagnosis of hypertrophic cardiomyopathy, aspirin and bisoprolol were prescribed for symptom relief.
- Progressive exertional dyspnea occurred in February 2021. No further evaluation or treatment was administered because of the mild severity.
- Unfortunately, exertional dyspnea worsened in 2022, and follow-up echocardiography showed rapid progression of LVH with left ventricular outlet obstruction over the past five months.
- Alcohol septal ablation was suggested for HOCM; however, the patient refused the treatment.
- A screening test for Fabry disease was performed, and the diagnosis of a classic genotype mutation was confirmed in August 2022.
- Treatment with agalsidase beta (1 mg/kg every other week) was initiated on January 30th, 2023.

## Past history

- Hypertension is controlled with amlodipine.

## Physical examination

- Hearing loss, associated or not associated with Fabry disease.
- Grade III/IV systolic murmurs over the left lower sternal border.
- No cornea verticillated.
- Neuropathy and acroparesthesia were not observed.
- Angiokeratoma and hypohydrosis were not observed.

## *Laboratory panels*

### Figure 1.

| Systemic: | Reference | Date (baseline) |
|---|---|---|
| Hb | 12-17 g/dL | 14.8 (2022/06/23) |
| DBS Lyso-Gb3 | <0.3 ng/mL | 2.6 (2022/08/04) |
| GAL-a enzyme activity | >15.3 μmol/L/h | N/A (female) |
| GLA mutation | c. 131 G > A (p. Trp44Ter) | |
| **Renal** | **Reference** | **Date 1 (baseline)** |
| eGFR | (>90) mL/min/1.73m$^2$ | 87 (2022/07/02) |
| Microalbuminuria | (Random Urine< 1.9 mg/dL) | 12.9 (2022/09/07) |
| ACR | ug/mg Creatinine(<30) | 129.62 (2022/09/07) |
| **Cardiac** | **Reference** | **Date 1 (baseline)** |
| Troponin I (hs-cTn I) | Pg/mL (Female: <=36.99; Male:<=57.27) | 904.19 |
| NT pro-BNP | pg/mL(< 300) | 2120 (2022/07/02) |
| 6MWT | 374 m | |

- Classic Fabry disease is diagnosed based on a high DBS lyso-Gb3 level and c.131 G>A (p. Trp44Ter) mutation.
- The patient' s eGFR is within the normal range but with proteinuria.
- Increase in troponin I and NT pro-BNP levels, along with mild decrease in six-minute walk test results are observed.

## *Electrocardiography*

### Figure 2.

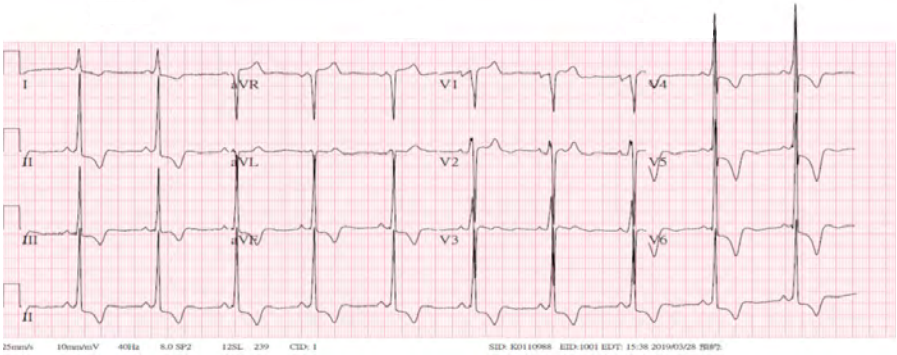


- EKG in 2019
- Sinus bradycardia with borderline short P-R interval
- LVH with strain pattern

### Figure 3.

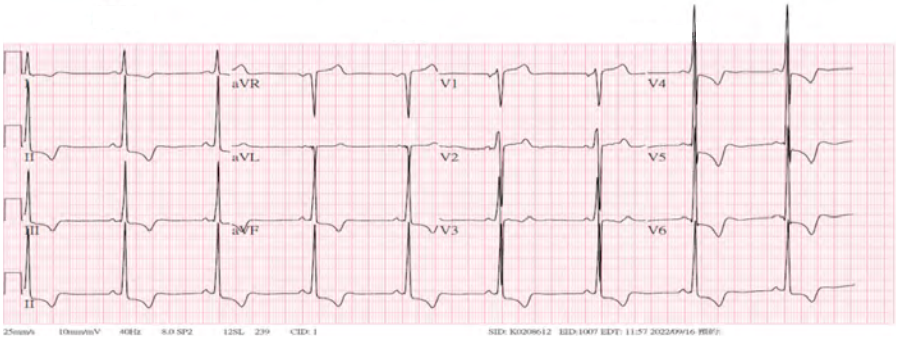


- EKG in 2022
- There is no significant difference obtained from the results of 2019.

## *Chest radiograph*

### Figure 4.

| | Ref | Date 1 2019.03.26 | Date 2 2022.02.04 | Date 3 2022.06.21 |
|---|---|---|---|---|
| IVSd, mm | 6-11 | 11.3 | 17.08 | 21.7 |
| LVPWd, mm | 6-11 | 12.46 | 12.42 | 19.1 |
| EF, % | 50-80% | 74 | 71.3 | 65.8 |
| LVd mass ind, $g/m^2$ | 70±9 $g/m^{2(men)}$<br>61±8 $g/m^{2(women)}$ | | 193.09 | 261.1 |

- Progressive LVH from 2019 to 2022

### Figure 5.

- Transthoracic echocardiography on June 1st ,2022 (A) Long-axis 2 chamber view (B) Apical four chamber view (C) LVOT pressure gradient
- Marked LVH with increase in interventricular septal thickness (21.7 mm)
- Trans-LVOT pressure gradient of up to 65 mmHg

Figure 6.

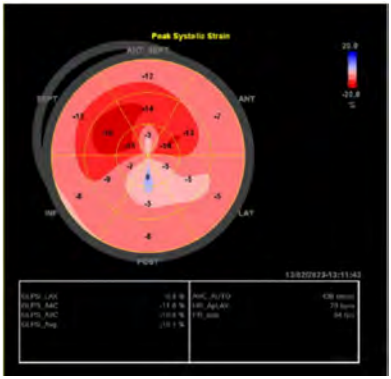


- 2D-speckle tracking-based echocardiography
- Significant reduction in peak systolic strain in the lateral and posterior segments indicates early myocardial deformation, which is a typical presentation of Faby’s disease with cardiac involvement.

## *Pedigree*

Figure 7.

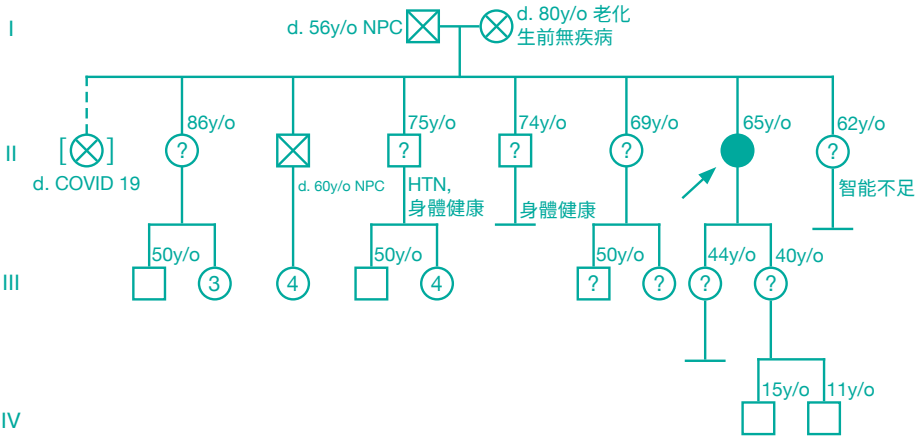


● 實心代表用藥中

？問號表示可能帶因，需進一步檢查

- Although the patient’s siblings and daughters were informed, they hesitated to undergo Fabry disease testing.

## *Discussion*

- This patient presented with typical EKG morphological changes of Fabry disease, including a shortened P-R interval and LVH. Clinicians should be aware of these EKG changes and consider Fabry disease as a differential diagnosis.
- According to the three echocardiogram results from 2019 to 2022, the patient's LVH continuously progressed, but at a different pace: slower from 2019 to February 2022 and faster between February and June 2022, indicating that Fabry disease-related cardiomyopathy may progress more rapidly over time.
- Regular echocardiographic follow-ups of patients with unexplained LVH are important. In this patient with well-controlled hypertension but a relatively thicker septal wall, echocardiography should be performed more frequently once symptoms occur.
- According to the previous studies, the presence of late gadolinium enhancement (LGE) on cardiac magnetic resonance imaging is associated with worse clinical cardiovascular outcomes and poor response to ERT. Since this patient presented LVH without obvious LGE on cardiac magnetic resonance imaging, we expected the patient may have good response to ERT, such as stabilization or regression of LVH.
- Although the patient's genotype is classified as classic Fabry disease, her clinical presentation seems more like the cardiac subtype, which indicates that there may be a discrepancy in the genotype and phenotype of Fabry disease. This discrepancy may be more commonly observed in female patients based on the mode of inheritance of Fabry disease.
- Considering that this patient's diagnosis was classic type rather than cardiac subtype Fabry disease, we strongly suggest that all her family members, especially her two grandchildren, undergo genetic tests. However, the patient's siblings and daughters were reluctant to do so. We will continue to convince them by explaining the current and future treatment options, follow-up plans, and relatively good outcomes, if under appropriate control.
- Previous studies have revealed that the most common cardiomyopathy observed in Fabry disease is eccentric hypertrophy, whereas HOCM is rarely observed. However, in our experience, HOCM is common in Taiwan.
- Alcohol septal ablation is a treatment option for HOCM and is effective in patients with Fabry disease-related HOCM. As the patient was hesitant to undergo invasive procedures, she is now using ARB, β-blockers, and low-dose diuretics for cardiomyopathy. Sodium–glucose cotransporter 2 inhibitors may be considered in poorly controlled patients.

# Fabry Disease Case Book

## Case 6:

A case of early-detected Fabry disease

張嘉修醫師

## *Clinical pearls*

- Although many patients of Fabry disease share the same genetic mutation (genotype), their phenotype can be varied.
- For patients of Fabry disease, the abnormalities presented by cardiac MRI or EKG may progress slowly, but clinical symptoms can progress rapidly once occur.
- Image examination may detect Fabry disease at early stage, even prior to clinical symptoms. Clinicians should be aware of the abnormalities of image results, to diagnose and treat Fabry disease earlier.

## *Patient profile*

Case presentation

- 64-year-old male, receiving self-pay health examination once every other year in Taipei Cathay General Hospital for many years
- Chief complaint: near fainting while fast walking across the road in June 2021
- Mild dyspnea was accompanied with the near fainting episode, but both symptoms subsided after a short break.
- Associated health examination reports from 2008 to 2015: blood pressure and heart rate within normal range; cardiac echography showed borderline LVH (IVS 12mm); 24-hour holter showed sinus rhythm (56/min) with 1325 APCs; MSCT revealed no significant coronary artery stenosis.
- Before this near fainting episode, the patient had visited our cardiovascular clinic three times because of frequent palpitation from April 2021. Propranolol was prescribed but stopped soon after because the patient experienced dizziness due to low blood pressure.
- Considering both cardiac echography and 24-hour holter in August 2021 revealed unexplained but slightly progressing LVH, Fabry disease test was performed, and IVS4 cardiac Fabry disease was diagnosed.
- Cardiac MRI was arranged for further evaluation, however, we found that the patient had underwent cardiac MRI scan in 2020, with report indicating Fabry disease was highly suspected.
- ERT of agalsidase beta (3 mg/kg every other week) was started from February 2022.
- No near fainting episode was reported after ERT, but occasional palpitation still

existed and once heart rate up to 120-130 beats per minute was complained. Because the patient’s blood pressure and heart rate increased after ERT (126/76 mmHg and 67 beats per minute), we added bisoprolol and ramipril as treatment for heart failure and keep monitoring if atrial fibrillation occurs.

- Although the infusion rate of agalsidase beta is faster than usual (within 1.5 hours for every treatment infusion) upon the patient’s request, he has not experienced any allergic reaction.

## Past history

- The patient denied any past medical history or associated family history.
- Slight LVH had been found in regular health examination from 2015.

## Physical examination

- Blood pressure: 102/64 mmHg; heart rate: 58 beats per minute
- No angiokeratoma
- No neuropathic symptoms

## *Laboratory panels*

### Figure 1—3. Before ERT (2021)

| Systemic | Reference | 2021/10/11 |
|---|---|---|
| Hb | 12-17 g/dL | 15.3 |
| Plasma Lyso-Gb3 | <1.8 ng/ml | **8.86** |
| GAL-a enzyme activity | >1.5 μmol/hr | 0.33 |
| GLA mutation | -- | **IVS4+919G>A** |

| Renal | Reference | 2021/10/11 |
|---|---|---|
| eGFR | -- | 86.1 |
| proteinuria | -- | -- |
| UPCR | <150 mg/g | 80.6 |

| Cardiac | Reference | 2021/10/11 |
|---|---|---|
| hs-Troponin T | <14 ng/L | **78** |
| pro-BNP | <125 pg/ml | **115** |
| 6MWT | -- | **296** |

- Fabry disease was diagnosed by IVS4+919 G>A mutation.
- Troponin T and pro-BNP increased with poor 6-minute walk distance.

## Figure 4—6. After ERT (2021)

| Systemic | Reference | 2021/10/11 | 2022/03/11 | 2022/06/15 |
|---|---|---|---|---|
| Hb | 12-17 g/dL | 15.3 | 15.6 | 16 |
| Plasma Lyso-Gb3 | <1.8 ng/ml | **8.86** | **8.19 ↓** | **2.3 ↓** |
| GAL-a enzyme activity | >1.5 μmol/hr | 0.33 | | |
| GLA mutation | -- | **IVS4+919G>A** | | |

| Renal | Reference | 2021/10/11 | 2022/03/11 | 2022/06/15 |
|---|---|---|---|---|
| eGFR | -- | 86.1 | 86.3 | 82.8 |
| proteinuria | -- | - | - | - |
| UPCR | <150 mg/g | 80.6 | 76.2 | 82.1 |

| Cardiac | Reference | 2021/10/11 | 2022/03/11 | 2022/06/15 |
|---|---|---|---|---|
| hs-TroponinT | <14 ng/L | **78** | **33 ↓** | **33 ↓** |
| pro-BNP | < 125 pg/ml | **115** | **676 ↑** | **375 ↓** |
| 6MWT | | **296** | **-** | **412** |

- Significant decrease in plasma lyso-Gb3 level
- Decreased troponin-T level after ERT
- pro-BNP level increased regardless of ERT at first, but decreased gradually after drug modification.
- Improved 6-minute walk distance

## *Electrocardiography*

### Figure 7.

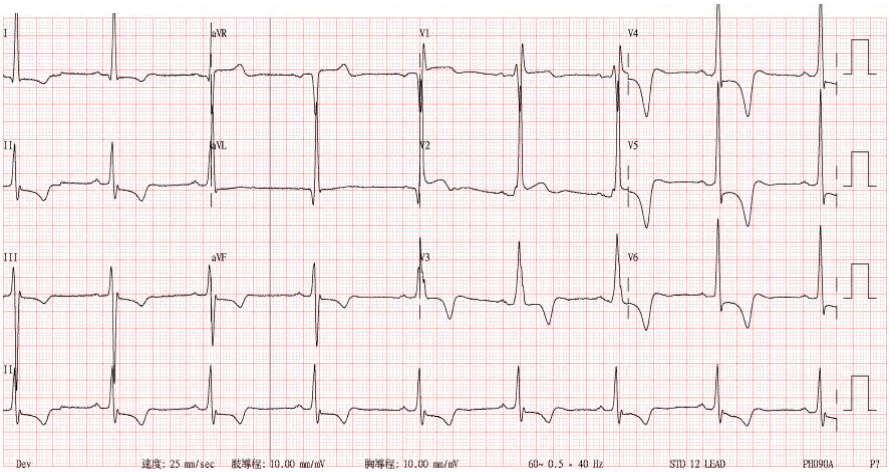


- EKG on August 23, 2021
- Bradycardia (PR interval: 188 ms; QRS interval: 140 ms)
- LVH, with inverted T waves and ST depression

### Figure 8.

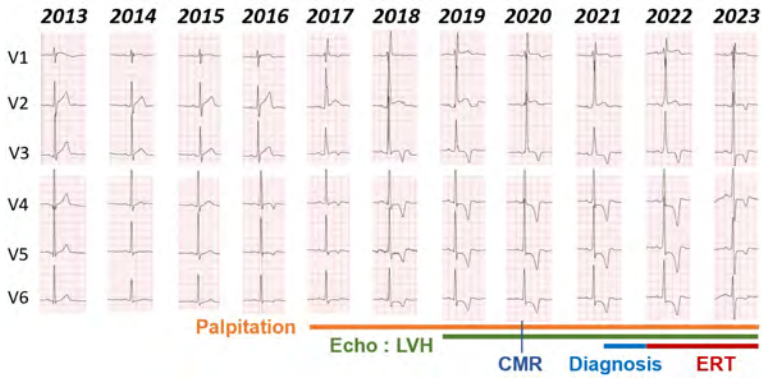


- Morphology of EKG lead V1—V6 from 2013 to 2023
- Progressive LVH before ERT
- The strain pattern was firstly identified in 2019.
- LVH pattern seemed to be improving after ERT starting in 2019.

## *24-hour holter*

### Figure 9.

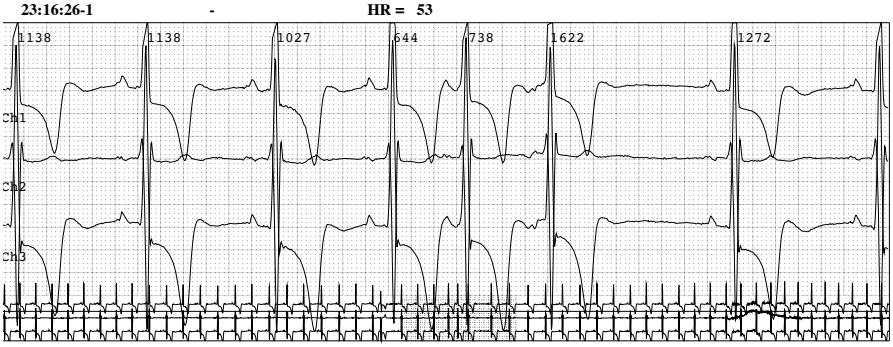


- 24-hour holter on August 16, 2021
- Sinus rhythm with rate of 40-96/min; mean rate 58/min
- Frequent APCs (2610 in total) with repetitive APCs

## *Cardiac echography*

### Figure 10—13.

- Cardiac echography on August 23, 2021
- LVH (LVMI 157.6 mL/m$^2$, IVS [end-diastole] 13mm)
- Grade 2 diastolic dysfunction
- No left ventricular outflow tract obstruction

## Figure 14.

| | Reference | 2017/05 | 2019/07 | 2020/10 | 2021/08 | 2021/11 | 2022/08 | 2023/01 |
|---|---|---|---|---|---|---|---|---|
| IVSd | 6-12mm | 12 | 13 | 13 | 13 | 13 | 13 | 14 |
| LVEDd | 40-60mm | 47 | 44 | 51 | 50 | 50 | 50 | 46 |
| LVPWd | mm | 11 | 12 | 12 | 12 | 12 | 12 | 13 |
| EF | 50-80% | 63 | 63 | 67 | 68 | 63 | 68 | 73 |
| LVMI | g/m2 | -- | 127 | 125 | 157.6 | 134.6 | 121.3 | 152 |

- LVMI still increased after ERT.

## Figure 15.

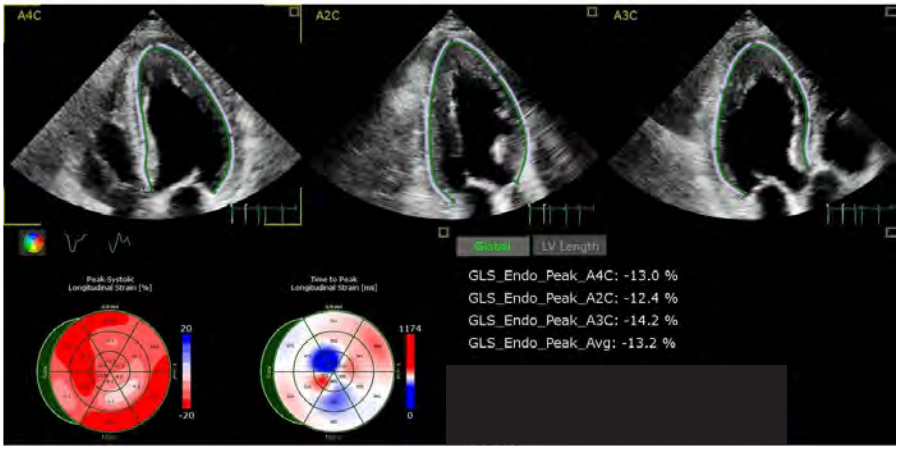


- General GLS was impaired in 2023.

## *Cardiac magnetic resonance imaging*

### *Figure 16—18.*

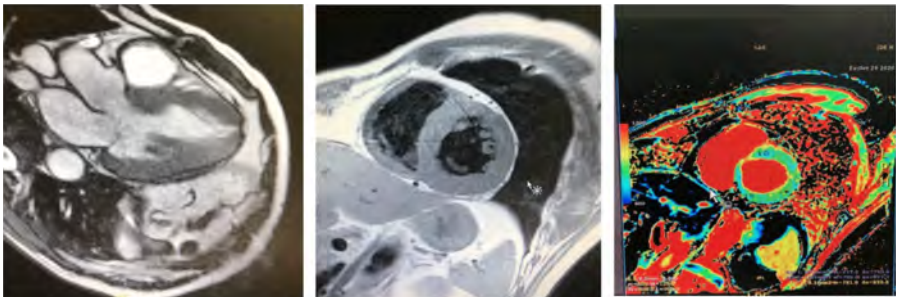

- Cardiac MRI in 2020 (approximate one year before the patient’s near fainting episode)
- VH with diffuse native T1 shortening (T1 signal 826-932 ms); no fibrosis
- Anderson-Fabry disease was highly suspected.

### Figure 19—21.

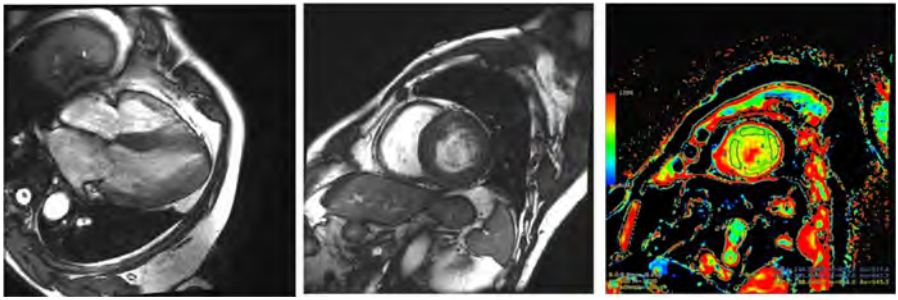

- Cardiac MRI in 2022, after ERT
- LVH (304g) with similar T1 shortening (T1 signal: 834-945 ms)
- No fibrosis or late gadolinium enhancement

## *Cardiac biopsy*

Figure 22

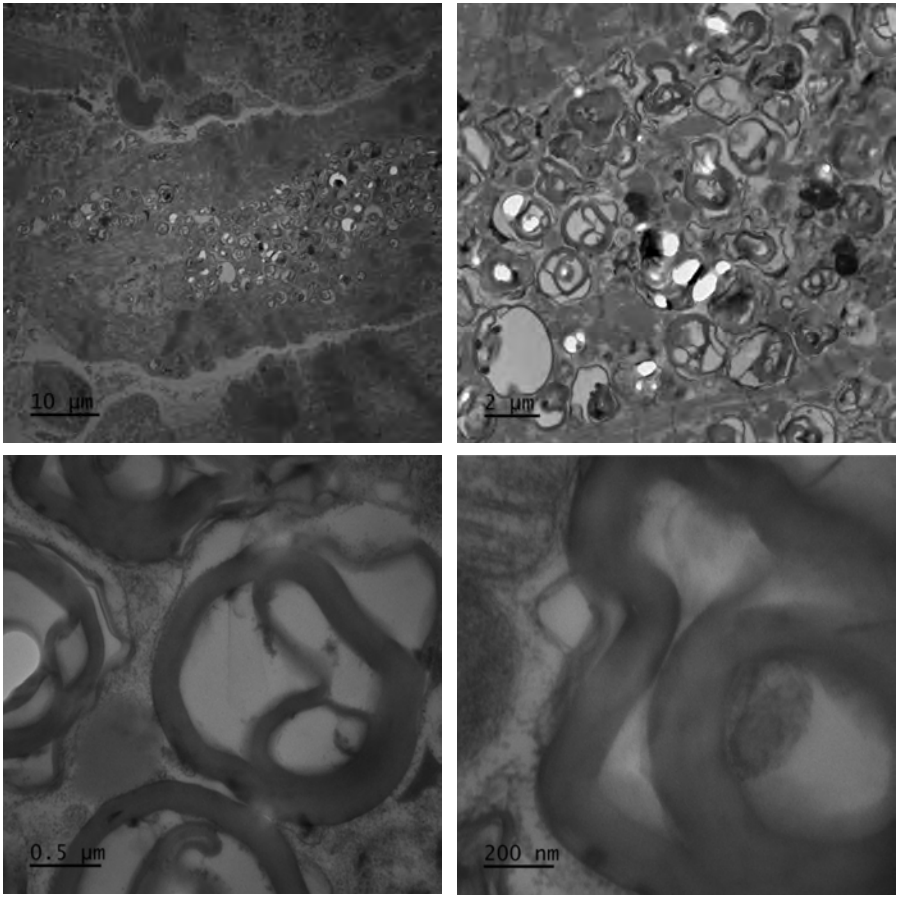


- A—D. Biopsy of the right ventricle
- Hypertrophic changes of myocytes and mild fibrosis in interstitial tissue
- Presence of lamellar inclusions (myelin bodies/zebra bodies) in the myocytes
- Compatible with Fabry Disease

## *Pedigree*

**Figure 23.**

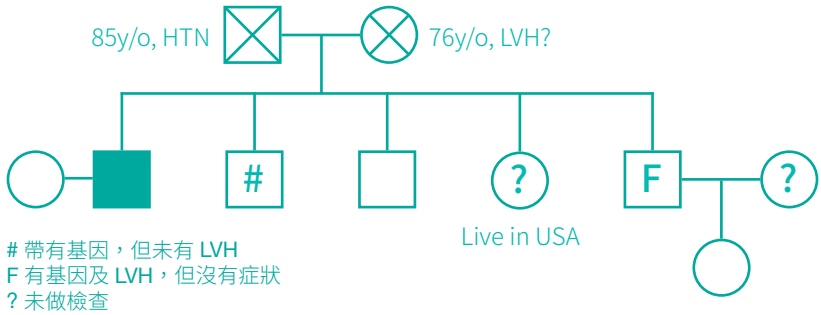


- One of the patient’s brothers was identified with the mutation and LVH. He is under regular follow-up but does not receive ERT because no symptom occurred.

## *Discussion*

- LVH, reduced T1 signal with no late gadolinium enhancement are characteristics of Fabry disease in cardiac MRI. The report of this patient’s cardiac MRI in 2022 showed similar shortening of T1 signal after ERT. Based on evidences of Fabry disease, cardiac MRI T1 value would not recover after ERT, even patients’ LVMI may improve. Thus, only T2 value indicating edema or inflammation, can be a marker for follow-up.
- This patient’s shortened native T1 signal of cardiac MRI was identified easily, and earlier than his LVH features on EKG, which means that cardiac MRI is a good detector for early Fabry disease. Unfortunately, most patients do not have chance to take cardiac MRI examination before the diagnosis of Fabry disease is confirmed owing to the consideration of cost.
- This patient claimed no significant symptom occur before this near fainting episode, whereas his first 6-minute walk distance (less than 300 m) is shorter than most of patients of Fabry disease with mild dyspnea (between 400 to 500 m).
- This patient’s plasma lyso-Gb3 level and amounts of APC (from 2610 to 514) decreased after he started to receive ERT, however, there was no continuous improvement on his LVMI and proBNP level. Long-term monitoring is needed to determine the effect of ERT in this patient.

- According to previous studies, no fibrosis in cardiac MRI may predict better outcome; but in this patient and some other patients in our hospital, 6-minute walk distance and some biomarkers may improve after starting ERT, their symptoms did not improve significantly. That might be one reason that many patients do not come back to receive ERT regularly.

## *References*


1. J Am Coll Cardiol Img 2019;12:1230–42.

# Fabry Disease Case Book

## Case 7:

A male patient with classic Fabry disease misdiagnosed for 28 years

高永達醫師

## *Clinical pearls*

- It may take years from the patient’s initial visit to confirm the diagnosis of Fabry disease, due to frequent misdiagnosis among the patient’s family members. Clinical awareness of Fabry disease, and a complete family history are critical for its prompt diagnosis.
- Since this is an x-linked disease, male patients with Fabry disease may present with diverse and severe symptoms, requiring numerous consultations. Enzyme replacement therapy may significantly improve their lyso-Gb3 level and pain.
- Safety is a priority when treating patients with Fabry disease. Clinicians should pay more attention to enzyme replacement therapy-related infusion reactions and side effects, particularly for male patients with Fabry disease.

## *Patient profile*

### Case presentation

- 37-year-old male
- Since the patient was nine years old, he has been experiencing a burning sensation in his limbs, which would be aggravated by the common cold.
- Hypohidrosis and high body temperature-induced urticaria were also observed.
- The patient consulted in several clinics and hospitals; however, no conclusive diagnosis was made.
- By the age of 32 years old, the patient noted dyspnea on exertion and palpitations while lifting heavy objects. He consulted in another hospital, where the diagnosis of a left ventricular hypertrophy (LVH) was made.
- The patient visited our hospital for a medical survey after his mother was diagnosed with classic Fabry disease at the age of 56 years (in 2016). He was also diagnosed with classic Fabry disease, and started to receive enzyme replacement therapy (ERT) (agalsidase alfa 0.2 mg/kg every other week).
- The ERT infusion time decreased from 120 mins (first session) to 40 mins (fourth session). Further, premedication was only used in the first two and the fifth sessions. No remarkable infusion reaction occurred under a 40-minute infusion time since the sixth session of ERT (seventh year of ERT).
- ERT was discontinued between April and June 2022 due to the coronavirus disease-2019 pandemic. His limb pain recurred during this period but resolved immediately after resuming ERT.

## Medical and personal history

- Smoker, with chronic obstructive pulmonary disease
- Impaired fasting glucose and mixed hyperlipidemia

## Physical examination

- Angiokeratoma over the waist and scrotum area
- Acroparesthesia
- Hypohidrosis

## Family history (patient's mother's Fabry disease-related history)

- First visited the Taipei Medical University Hospital at the age of 54 (2014), with a medical history of LVH.
- Her chest radiograph revealed marked cardiomegaly. Electrocardiography (EKG) revealed normal sinus rhythm with LVH and left atrium enlargement. Cardiac echography showed hypertrophic obstructive cardiomyopathy with obstruction (pressure gradient 18 mmHg), normal left ventricular systolic function, and diastolic dysfunction.
- Verapamil and statins were prescribed, but her palpitations persisted until 2015. Follow-up cardiac echography in November 2015 revealed results similar to those obtained in 2014.
- No history of hypertension, diabetes mellitus, and chronic kidney disease.
- Under the impression of unexplained LVH, a mutation test was performed and a diagnosis of classic Fabry disease was confirmed.
- No typical Fabry disease symptoms, such as angiokeratoma, neuropathy, or hypohidrosis, were identified or reported. No coronary artery stenosis was observed on coronary computed tomography.
- She received ERT (agalsidase alfa 0.2 mg/kg every other week) for seven years.

## *Laboratory panels*

### Figure 1-3.

| Systemic | Reference | 2016 |
|---|---|---|
| Hb | 13-17 g/dL | 14.4 |
| Plasma Lyso-Gb3 | <2.6 ng/ml | **138.5** |
| a-GAL enzyme activity | 2.05-7.46 μmol/L/h | **<0.04** |
| GLA mutation | -- | **c. 982 G>A** |

| Renal | Reference | |
|---|---|---|
| eGFR | >60 mL/min/1.73m | 116 |
| UACR | <30mg/g | **35** |

| Cardiac | Reference | 2017 |
|---|---|---|
| Troponin T | <0.014 ng/L | NA |
| NT pro-BNP | <125 pg/mL | NA |
| 6MWT | >400 meter | 465 |

- Extremely high plasma lyso-Gb3 level and low α-GAL enzyme activity were noted at the time of diagnosis.
- Classic Fabry disease was diagnosed by c.982 G>A mutation.
- Normal eGFR with mild albuminuria
- Troponin-T and NT-proBNP were not measured because of the absence of significant symptoms and an acceptable 6-minute walk distance.

## Figure 4.

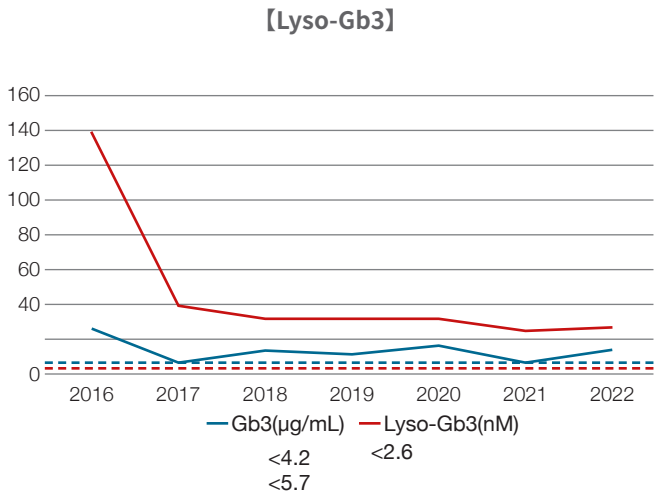


- Lyso-Gb3 significantly decreased in the 1st year of treatment and has maintained since then.

## Figure 5.

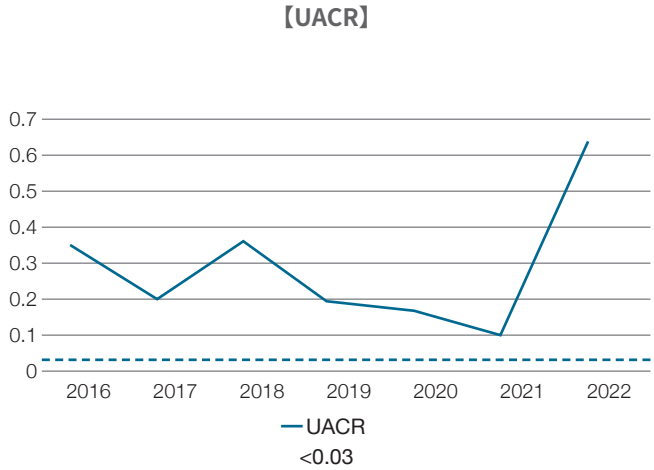


- UACR fluctuated between 2016 and 2021 and was continuously increasing after 2021.

## *Electrocardiography*

Figure 6.

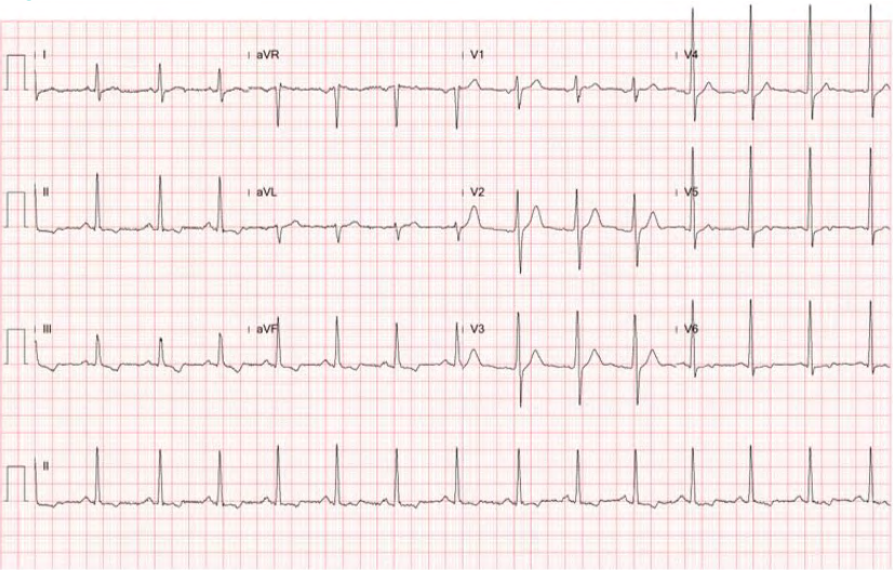


- LVH with no significant ST-T wave change
- No bundle branch block

## Figure 7.

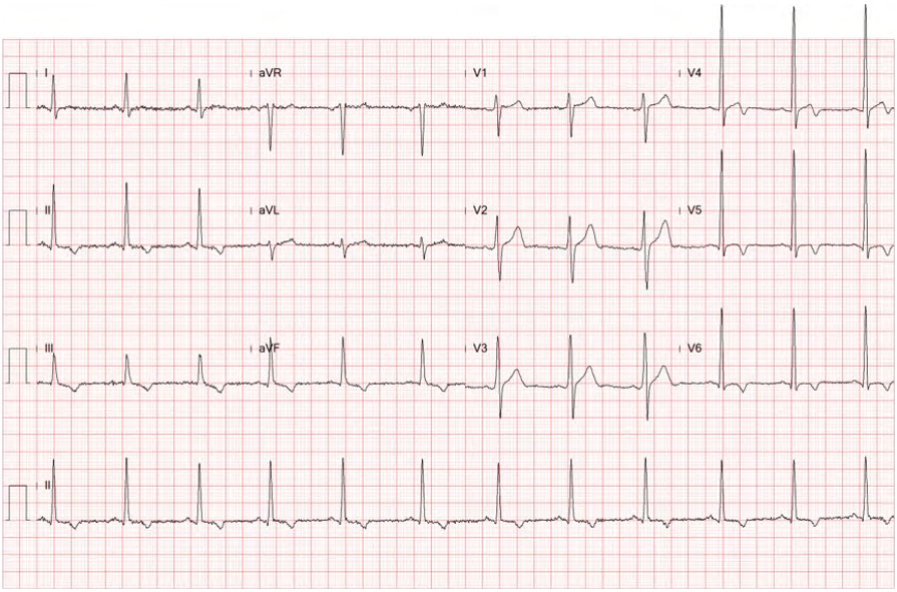


- Mild T wave inversion over lead III and V4 to V6
- No bundle branch block

## Figure 8.

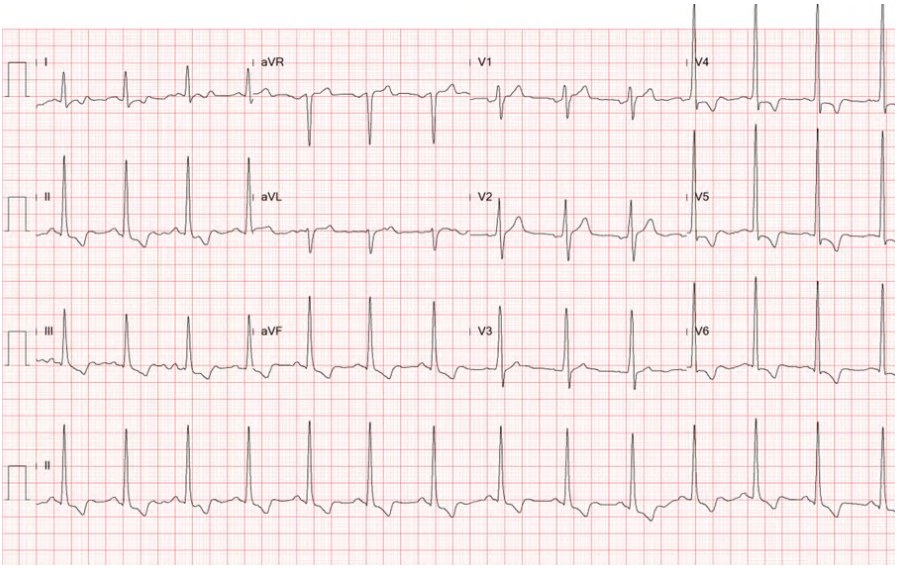


- Prominent ST-T wave changes over leads III and V4–V6 indicate LVH strain.
- No bundle branch block

## *Cardiac echography*

### Figure 9-10.

- Marked concentric LVH with increased thickness of the IVS (15 mm) and left ventricular posterior wall (14 mm) in diastole
- Normal mitral inflow E/A ratio

### Figure 11-12.

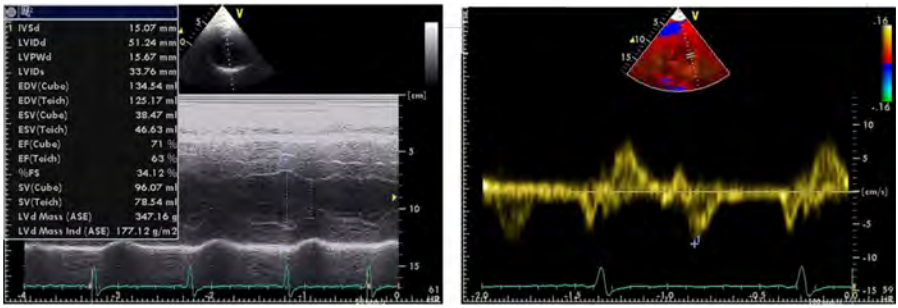


- Marked concentric LVH with increased thickness of the IVS (15 mm) and left ventricle posterior wall (16 mm) during diastole.
- Tissue Doppler revealed left ventricular diastolic dysfunction.
- No significant change on left ventricular wall thickness and LVMI compared with baseline.

Figure 13.

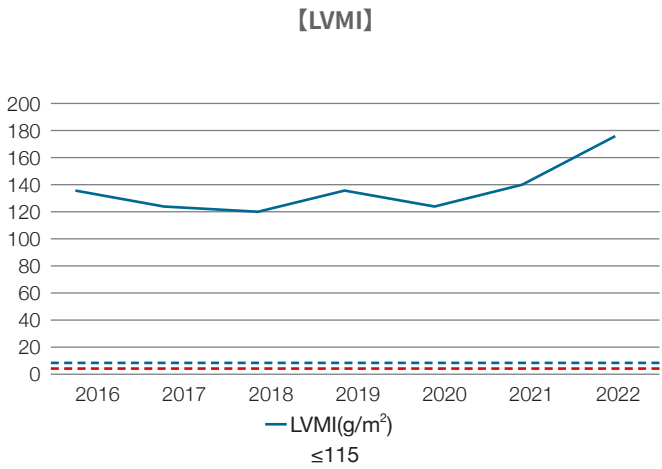


- Continuously increasing LVMI regardless of ERT

## *Cardiac magnetic resonance imaging*

Figure 14.

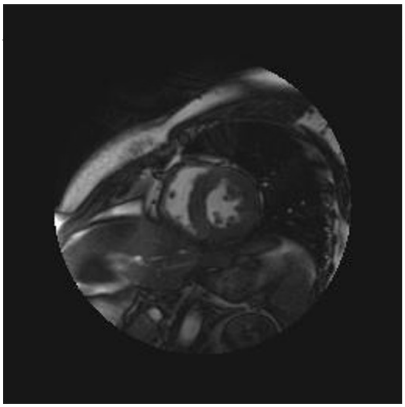

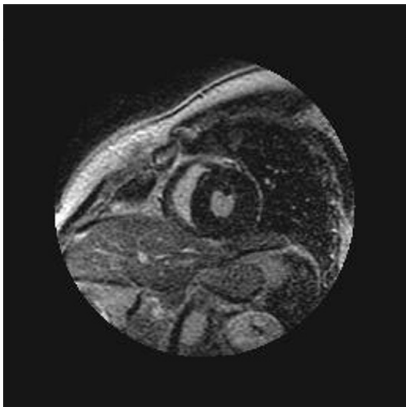

Cardiac MRI in the third year of ERT (2019)

- Homogeneous distribution of LVH
- No late gadolinium enhancement

## *Pedigree*

Figure 15.

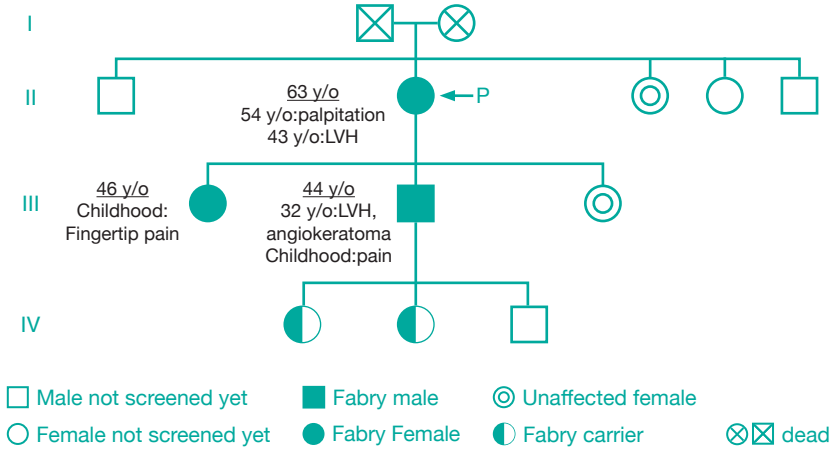


- One of this male patient's sisters was diagnosed with classic Fabry disease through family screening. She reported no cardiac symptom, but had suffered from burning sensation on fingers and toes since childhood. No cardiomegaly, LVH or other functional abnormality was observed by chest radiography, echocardiography, and EKG; her cardiac MRI results showed no HCM nor LGE, and her renal function remained normal. She had undergone 5 courses of ERT, but became loss of follow up because of the lack of family support.

## *Discussion*

- According to a study published in 2004, the mean time between the onset of symptoms and diagnosis of Fabry disease is 13.7 years for male patients, and 16.3 years for female patients. For this male patient, it took 28 years from the symptom onset to reach the diagnosis of Fabry disease. For his mother, Fabry's disease was only diagnosed 14 years after identifying her LVH, including the 22 months spent in our hospital.
- Although the male patient and his mother shared the same genotype of classic Fabry disease, their symptoms differed in organ involvement, severity, and age of onset. Both patients had LVH on EKG and cardiac echography during diagnosis. Only the male patient had proteinuria, neuropathic pain, angiokeratoma, and hypohidrosis. Different phenotypes between male and female patients with the same genotype are characteristic of classic Fabry disease.

- Less infusion-associated reactions are induced by algasidase alfa. However, infusion reactions occur more frequently in male patients with Fabry disease. Clinicians should pay more attention to safety issues in male patients, who are considered to have extremely low enzyme levels and may have stronger immune reactions toward ERT.
- One study showed that after five years of ERT, a clinically significant reduction in pain was observed in more than 50% of patients, as evaluated by a brief pain inventory change. This patient in our case reported less limb pain after his two courses of ERT. His worst pain markedly decreased after three years of ERT.
- One previous study concluded that ERT improves left ventricular morphology and function in patients with LVH. Further, it normalizes long QTc intervals, shortens PQ intervals, and shortens P waves, effectively reducing the burden of Fabry disease. However, this male patient' s LVH on EKG seemed to be continuously progressing despite ERT.
- Classic Fabry disease is a risk factor for coronary artery disease due to glycosphingolipid deposition in the endothelium of blood vessels. Our male patient was an obese smoker with impaired fasting glucose and hyperlipidemia. His EKG morphological changes may have resulted from coronary artery disease. Further examinations should be performed to evaluate his coronary artery condition.

## *References*


1. Mehta A, et al. Eur J Clin Invest. 2004;34(3):236-42.
2. Replagal Summary of Product Characteristics, EMEA, 2014.
3. Fabrazyme Summary of Product Characteristics ,EMEA, 2014.
4. Desnick JR, et al., N Engl J Med, 345,2001.
5. Mehta A, et al. Lancet. 2009;374:1986–96.
6. Motwani M, et al. Mol Genet Metab. 2012;107(1-2):197-202.

# Fabry Disease Case Book

## Case 8:

Syncope in a patient with left ventricular hypertrophy

余文鍾醫師

## *Clinical pearls*

- Fabry disease should always be considered in patients with an unexplained LVH.
- Syncope is not rarely observed in Fabry Disease patients. In Taiwan, the incidence of syncope in Fabry disease is estimated to be between 10–15%.
- Detailed history taking is pivotal in determining the cause of syncope in patients with Fabry disease. Long-term monitoring may be required for difficult cases.

## *Patient profile*

### Case presentation

- A 64-year-old retired male patient had medical history of mild exertional dyspnea and arrhythmias, underwent regular follow-ups in Taitung.
- The patient visited our hospital in 2011 because he experienced two episodes of loss of consciousness within a month.
- The patient's wife observed seizure-like limb movements while the patient was fainting.
- Motivated by the unexplained LVH, we administered a Fabry disease test, and a diagnosis of IVS4 cardiac Fabry disease was confirmed.
- ERT was promptly initiated. However, two episodes of syncope occurred within the first three months of treatment.
- After which, 24-hour Holter, coronary angiography and electrophysiological studies were performed, but no significant findings were reported. Brain MRI and electroencephalography revealed normal findings.
- An implantable loop recorder was used for six months, and a heart pause of up to 20 s was recorded.
- A permanent pacemaker was implanted in late 2011 or early 2012 and syncope has not re-occurred since then. The patient's LVH has not significantly progressed over the past 10 years, and he has been exercising and maintaining a good quality of life.

### Medical history

No hypertension, diabetes mellitus, or hypercholesterolemia.

## Personal history

- No smoking or alcohol consumption
- Walking 5–6 km daily.

## Physical examination

No significant findings.

## *Laboratory panels*

### Figure 1

| Systemic | Reference | Date 1 (baseline) |
|---|---|---|
| Hb | 12-17 g/dL | 149 |
| eGFR | | 68 |
| proteinuria | | Nil |
| ACR | <0.003 | 0.0059 |
| ALT | | 33 |
| AST | | 27 |
| Cholesterol | | 163 |
| TG | | 153 |
| Glucose | | 54 |

- No anemia.
- Acceptable eGFR with no proteinuria.
- No metabolic syndrome.

### Figure 2

| | Reference | Date 1 (baseline) |
|---|---|---|
| GALa enzyme activity | 7.9-16.9 umol/L/h | 1.15 |
| GLA mutation | | IVS4 919G>A- |

- Fabry disease was diagnosed by the IVS4 mutation.

## *Electrocardiography*

### Figure 3.

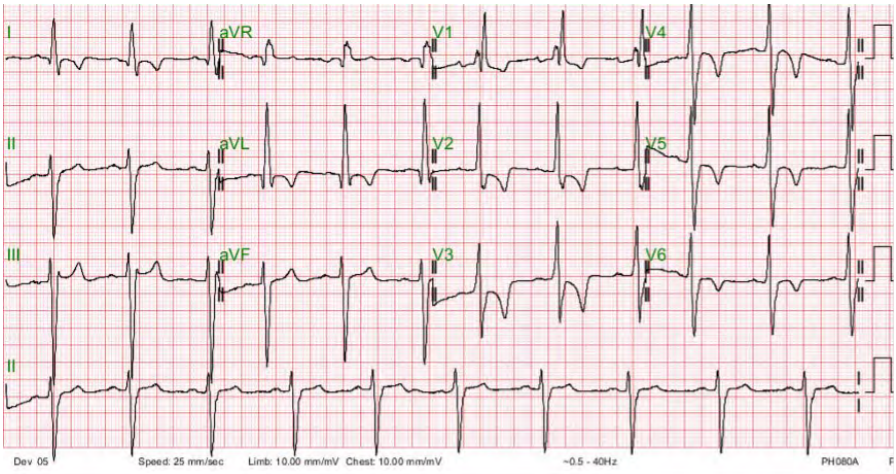


EKG in 2011

- Sinus rhythm.
- Left anterior fascicular block and right bundle branch block.
- LVH.
- Marked T wave inversion on lead V2 to V6, lead I and aVL.

## *Cardiac echography*

### Figure 4.1—4.4

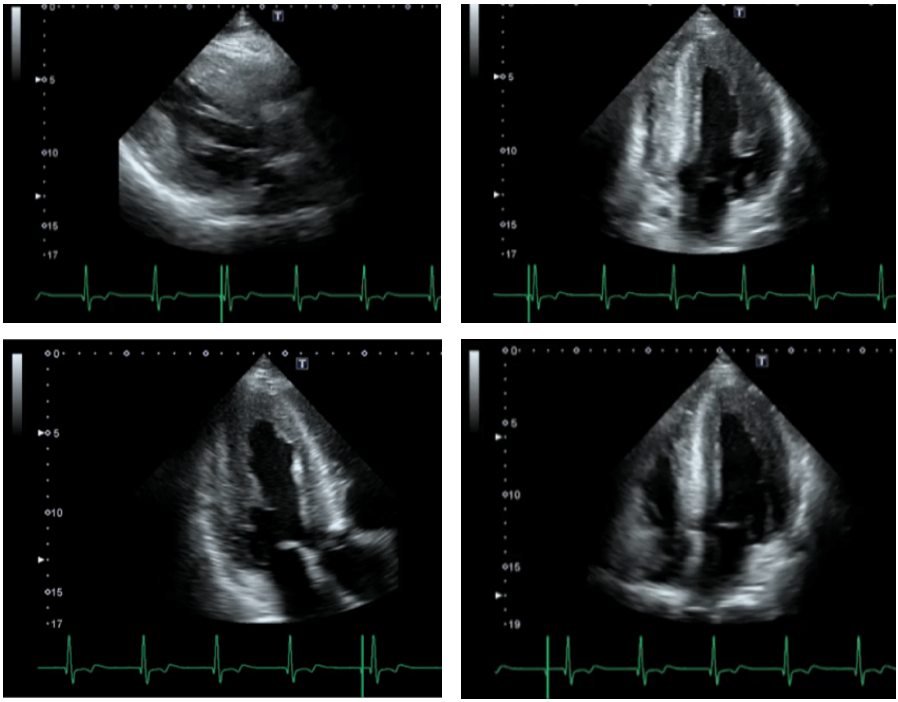

- Diffuse LVH.
- No significant regurgitation or valve hypertrophy.

## Figure 5—7

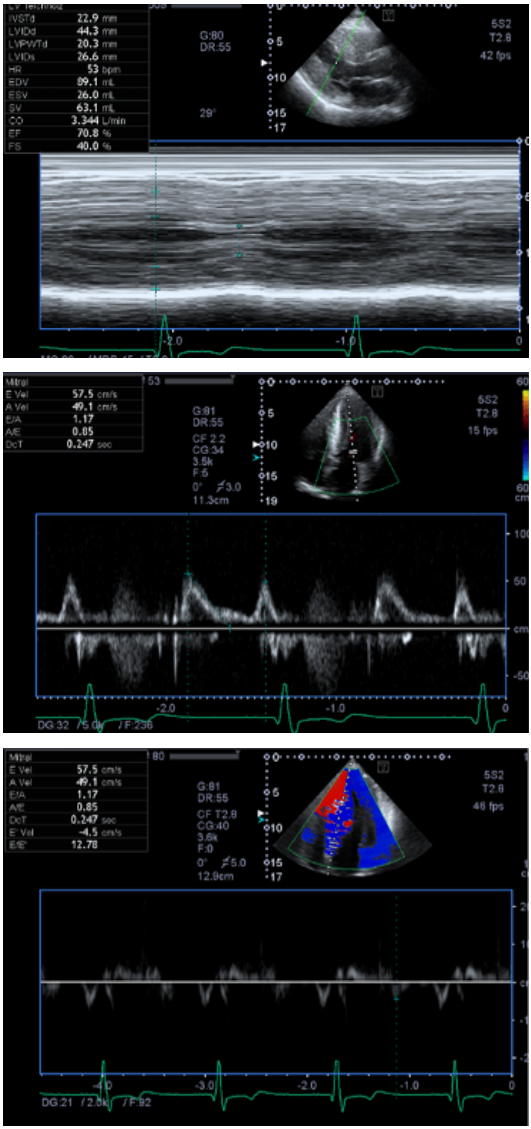


- IVS thickness: 23 mm, posterior wall thickness: 20 mm.
- E: 57.5 cm/s, A:49.1 cm/s.
- Septal E’ 4.5 cm/s; E/E’ : 12.8.

## *Cardiac magnetic resonance imaging*

Figure 8—9.

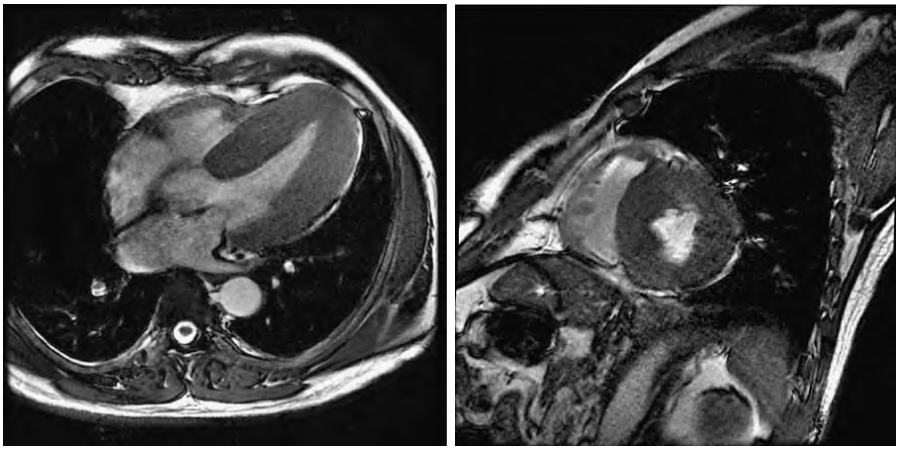

Severe concentric LVH; no late gadolinium enhancement

## *24-hour holter (after ERT started)*

- The basic rhythm was sinus rhythm with complete right bundle branch block.
- The rate was 55–120 beats per minute with seven APCs, 126 multiforms, two couplets, and one salvos VPC.
- QT interval:503 ms; QTc:553 ms.
- No event occurred.

## *Electrophysiological study*

- Borderline SA and AV node functions.
- No inducible VT by RV S1S2S3S4 pacing after isuprel and atropine challenge.
- Typical inducible counterclockwise rotational atrial flutter.

## *Implantable loop recorder*

Figure 10.

A 20-second heart pause with arrhythmias before and after this pause

## *Discussion*

- ERT may be effective for Fabry disease-associated cardiomyopathy, but it cannot resolve existing conductive system problems, which means that conductive system-related symptoms, such as syncope, may not be improved by ERT. For patients with Fabry disease, a comprehensive workup is needed to determine the exact cause and treatment of syncope.
- According to the Fabry Outcome Survey (FOS), syncope can be seen in 2-4% of patients with Fabry disease; our analysis showed an approximate 10% incidence rate in Taiwanese patients. Therefore, syncope is relatively common in patients with Fabry disease.
- Based on our clinical experience, the causes of syncope in patients with Fabry disease include postural hypotension, sinus node dysfunction, atrioventricular block, and VT. Detailed history-taking and comprehensive tests are important for determining the cause of syncope.
- It was difficult to determine the cause of syncope in this patient because of the infrequent episodes and borderline results of the electrophysiological study. However, syncope did not occur after pacemaker implantation, suggesting that a long heart pause was the underlying problem.
- This patient had severe diffuse LVH; however, the cardiac MRI report showed no evidence of late gadolinium enhancement, which was inconsistent with our clinical experience. Although the quality of the images acquired in 2011 was not satisfactory, this patient could not undergo a cardiac MRI scan again because his permanent pacemaker was not MRI-compatible.
- ICD implantation should be considered a treatment option for patients with syncope and hypertrophic cardiomyopathy. Nevertheless, considering the lack of strong evidence, many guidelines would exclude Fabry disease when describing the indications for ICD.

# Fabry Disease Case Book

## Case 9:

A case of Fabry disease with apical aneurysm

林中行醫師

## *Clinical pearls*

- Cardiac MRI provides important information regarding the diagnosis and prognosis of Fabry disease.
- Left ventricular apical aneurysm, thrombus formation, and LGE observed on cardiac MRI indicate long-lasting Fabry disease with myocardial fibrosis.
- ERT may not delay or reverse the progression of LVH, especially in patients with LGE. Thus, early diagnosis and initiation of ERT are important, and symptomatic treatment with medications other than ERT may be necessary.
- Ablation therapy may be beneficial for patients with Fabry disease presenting persistent Af.

## *Patient profile*

### Case presentation

- A 62-year-old male patient with no medical history of cardiovascular or metabolic disease visited our emergency department with dizziness, chest tightness, and palpitation for one hour in March 2020.
- At the emergency department, the patient' s vital signs were stable (body temperature: 37.1° C, pulse rate: 99 beat per minute, breathing rate: 20 breaths per minute, blood pressure: 166/99 mmHg) with clear consciousness and 100% of blood oxygen saturation level.
- Frequent non-sustained VTs were recorded using a continuous EKG monitor. Intermittent VPCs, APCs, and sinus pauses were observed after intravenous amiodarone infusion.
- Coronary angiography revealed no evidence of CAD. Left ventriculography revealed apical hypokinesis, suggestive of apical ballooning (Takotsubo) syndrome. However, the patient denied of any possible stress induction; thus, no specific treatment was administered.
- Two days after symptom onset, a follow-up cardiac echography revealed severe but unexplained LVH with no LVOT obstruction.
- Fabry disease screening was performed to investigate the unexplained LVH, and cardiac variant Fabry disease was diagnosed in March 2020.
- Cardiac MRI revealed marked LVH and LGE, and endomyocardial biopsy revealed myelin body accumulation in cardiomyocytes.
- Treatment with ERT (agalsidase alfa) was initiated in August 2020. Bisoprolol (2.5

mg) was prescribed daily for VT, and the patient underwent ICD implantation (MRI-compatible dual-chamber rate-modulated, DDDR) in September 2020.

- However, in October 2020, paroxysmal Afs persisting for up to four hours were observed during ICD follow-up. The dose of bisoprolol was increased to 5 mg/day because of one episode of VT following anti-tachycardia pacing.
- In June 2021, progressive Af and prominent VPCs were reported by 24 h-Holter examination despite ERT and ICD implantation.
- In October 2021, persistent Af for up to nine days (87%), with no VT or VF was observed. The patient complained of dyspnea and lower limb pitting edema over the past six months. Apical aneurysms and thrombi were noticed in previous cardiac MRI scans through periodic review. Thus, diltiazem and edoxaban were added to Af.
- In January 2022, the patient complained of frequent palpitations and dyspnea. EKG revealed persistent Af and mode switching. The patient decided to undergo ablation.
- After ablation, < 1% and no atrial tachycardia or fibrillation were reported in April and July 2022, respectively. Edoxaban, spironolactone, and bisoprololremained with no amiodarone after July 2022. The patient’s leg edema resolved after the ablation therapy.
- LVMI improved after Af ablation. However, in 2023, owing to intermittent dyspnea on exertion, deterioration of the left ventricular EF was reported on cardiac MRI, and several non-sustained VTs found by ICD, valsartan, and amiodarone were added.

## Past history and personal history

- Body weight: 74.3 kg; height: 168 cm; BMI: 26.3 kg/m$^2$.
- Smoked one pack per day for 40 years and quit after symptom onset.
- No hypertension, diabetes mellitus or dyslipidemia.

## *Laboratory panels*

### Figure 1.

| | |
|---|---|
| WBC | 7600/uL |
| Hb | 14.8 g/dL |
| D-dimer | 0.83 mg/L |
| Creatinine | 1.09 mg/dL |
| Na | 138 mmol/L |
| K | 3.3 mg/dL |
| CPK | 357 > 284>273 U/L |
| CKMB | **39.50 >34.64 >33.50 ng/mL** |
| Troponon | **251.4 >209.4 > 242.0 pg/mL** |
| Urine routine | **Protein(-)** |

The laboratory data upon arrival at the emergency department showed:

- Normal renal function; no proteinuria.
- No elevation of cardiac enzymes.

## Figure 2—4.

| 檢驗項目 | 結果 | 參考範圍 | 單位 |
|---|---|---|---|
| α-Galactosidase A enzyme activity | 0.58 | >2.05 | μmo/mL |

| 檢驗項目 | 結果 | 陰性參考值 |
|---|---|---|
| Plasma Gb3 | 6.1 | <5.7 ug/ml |
| Plasma Lyso-Gb3 | 4.8 | <2.6 n/M |

IVS4+919G>A, hemizygous late-onset, cardiac variant

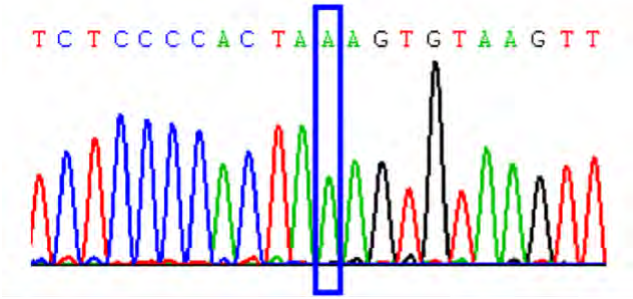


Cardiac variant Fabry disease was diagnosed by decreased α- GAL enzyme activity, elevated plasma Lyso-Gb3 level, and positive for IVS4+919G>A GLAmutation.

## Figure 5.

| 檢驗項目 | 結果 | 陰性參考值 |
|---|---|---|
| Plasma Gb3 | **7.1** | <5.7 ug/ml |
| Plasma Lyso-Gb3 | **3.8** | <2.6 n/M |

Follow-up laboratory data in August 2021 showed elevated plasma Gb3 level but decreased lyso-Gb3 level after ERT.

## *Chest radiograph*

### Figure 6.

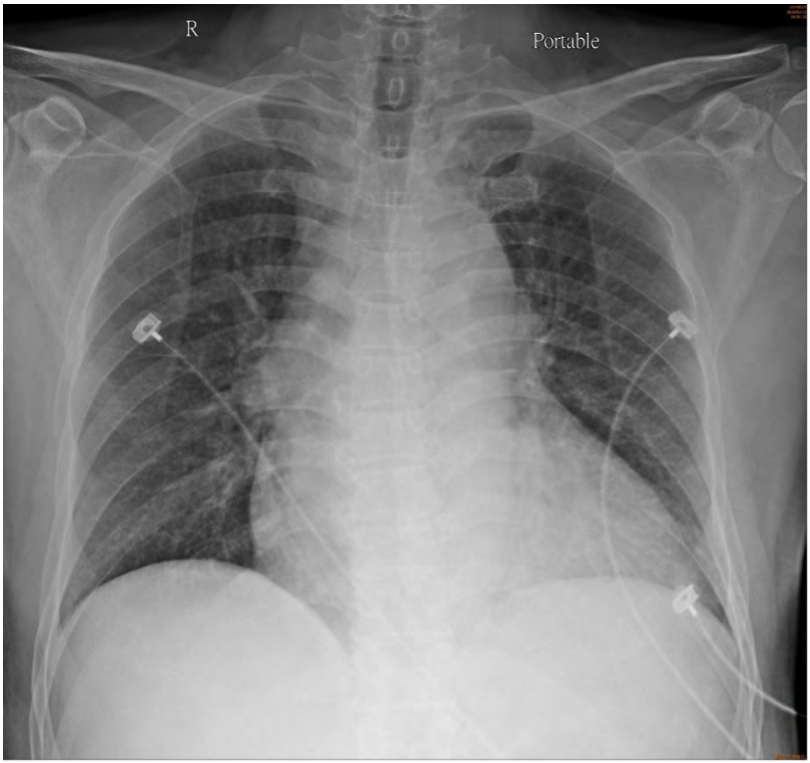


Chest radiography at the emergency department showed cardiomegaly with no pulmonary edema.

## *Electrocardiography*

### Figure 7.

Morphology of EKG monitor at the emergency department showed frequent non-sustained VTs.

## Figure 8.

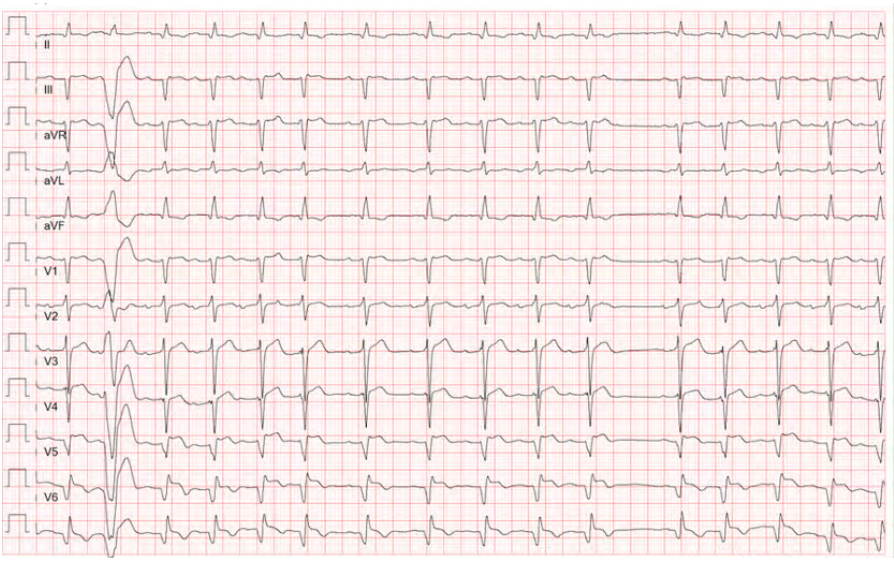


12-lead EKG obtained after amiodarone infusion at the emergency department showed intermittent VPCs, APCs and sinus pause.

## Figure 9.

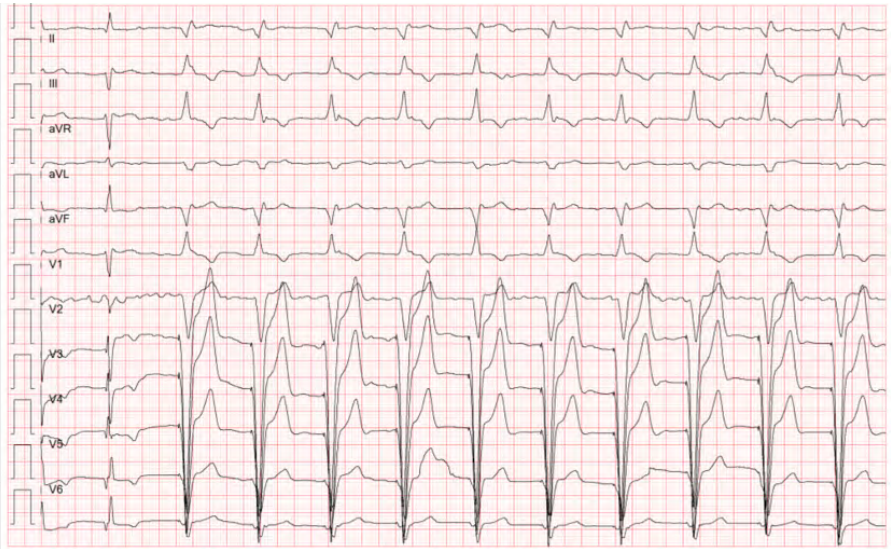


Follow-up EKG obtained before ablation therapy (in January 2022) showed Af >99% with mode switch to ventricle pace, ventricle sensed, inhibited (VVI) pacing mode.

## Figure 10.

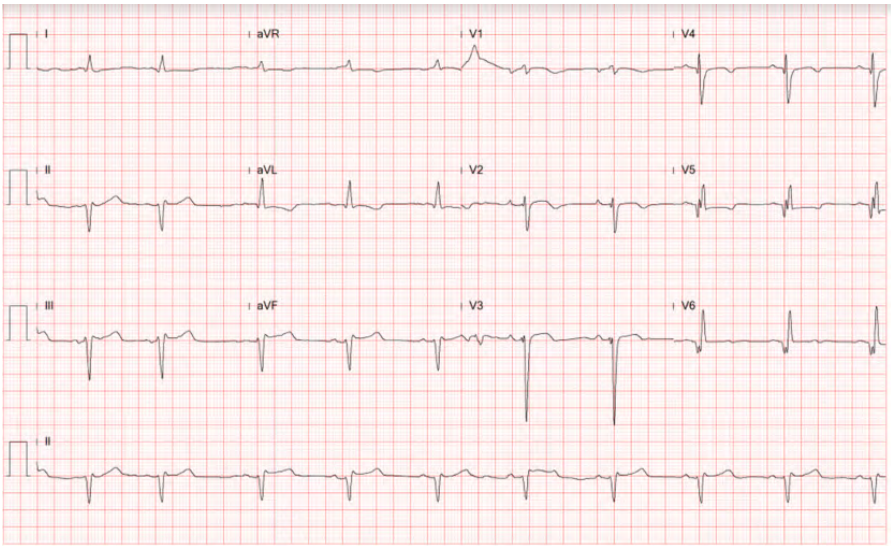


The morphology of EKG after ablation therapy returned to sinus rhythm.

## *24-hour Holter*

### Figure 11.

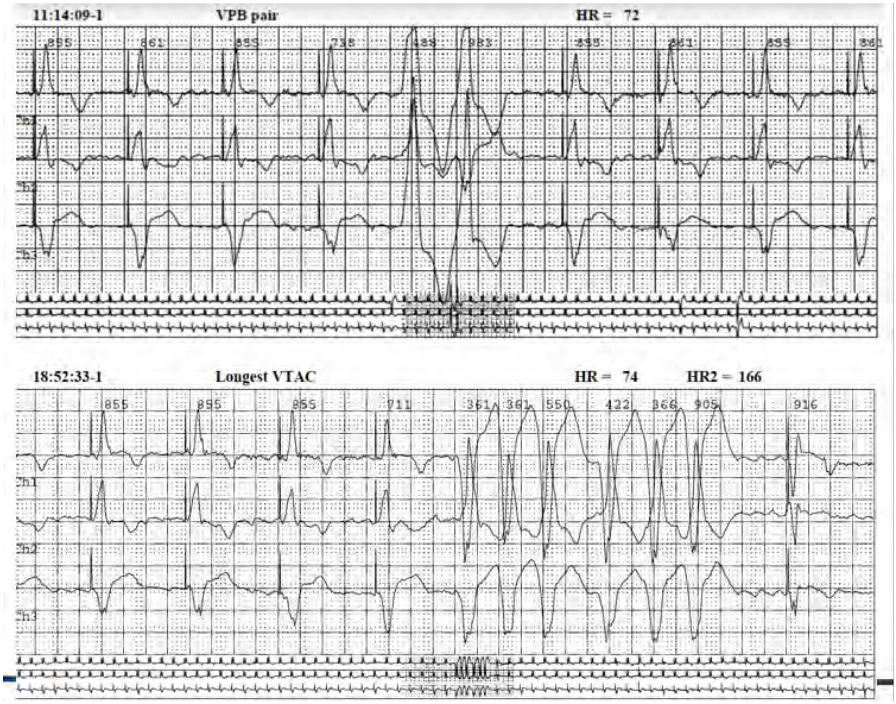


24-hour Holter examination in June 2021 found progressive Af and 1129 VPCs of multiform pattern.

## *Cardiac echography*

Figure 12—13.

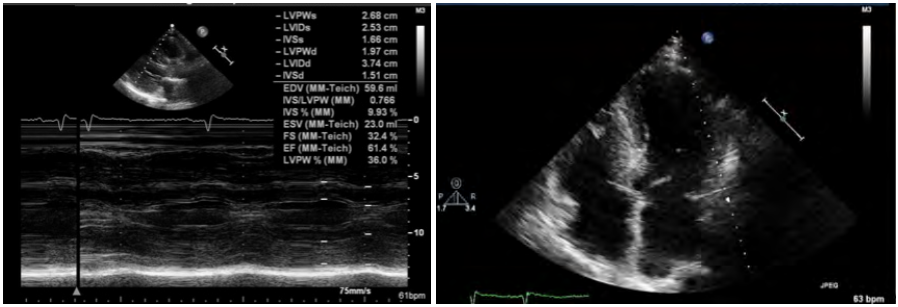


Cardiac echography on two days after symptom onset showed:

- Resolution of apical ballooning syndrome.
- A mildly enlarged left atrium (diameter, 43 mm; volume index:34.1 ml/m2).
- Marked LVH (IVS,15 mm; LVEDd,37 mm; LVPW,19 mm; and LVESD,25 mm).
- LVEF: 61%.
- No LVOT obstruction.
- Mitral valve inflow E/A: 52/72.
- Medial E/E’ : 26.3

## *Cardiac magnetic resonance imaging*

Figure 14—18.

Cine images

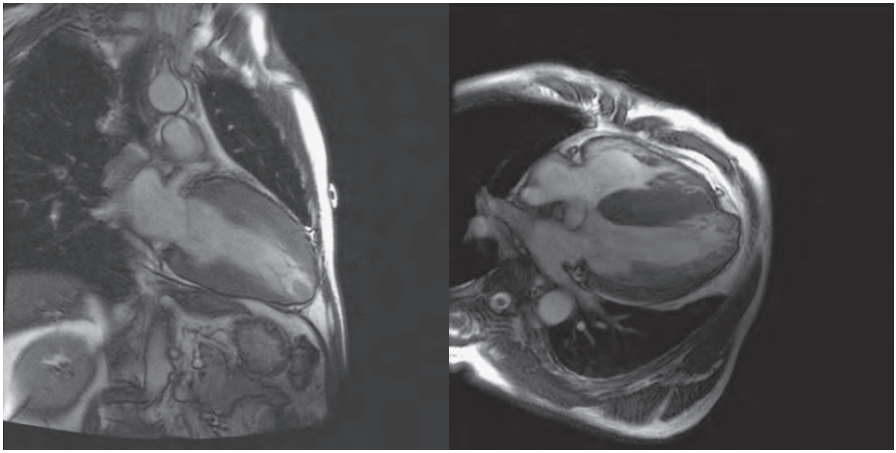

LGE

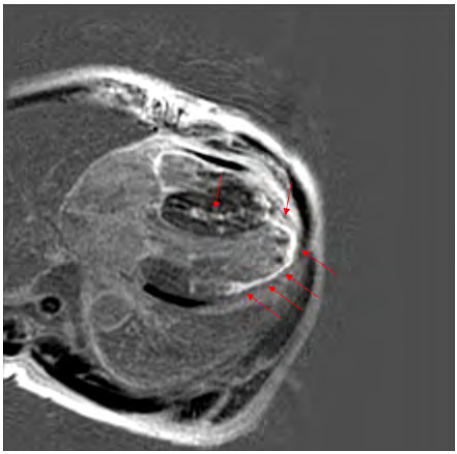

## Apical aneurysm and thrombus

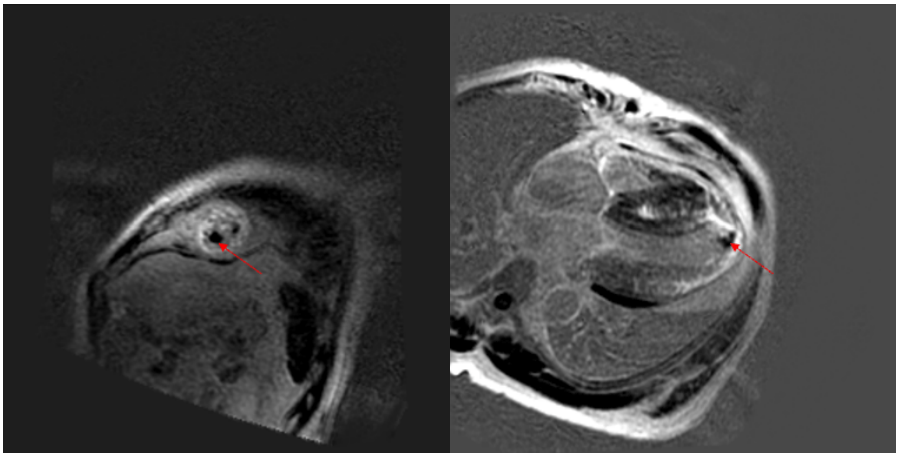

Cardiac MRI in April 2020 showed:

- Marked LVH.
- Left ventricular mass: 293 g.
- Prominent LGE on basal, inferior, lateral, septal and apical walls.
- Left ventricular EF: 46%.
- Apical aneurysm and thrombus were found by image review after detection of Af.

## *Treatment follow up*

### Figure 19—20.

| | 2022/4/11 | 2022/7/4 | 2023/2/6 | 2023/7/4 |
|---|---|---|---|---|
| AT/AF burden | <1% | 0% | <1% | <1% |
| VT | Nil | Nil | Non-sustained x1 | Non-sustained x2 |
| ID shock | Nil | Nil | Nil | Nil |

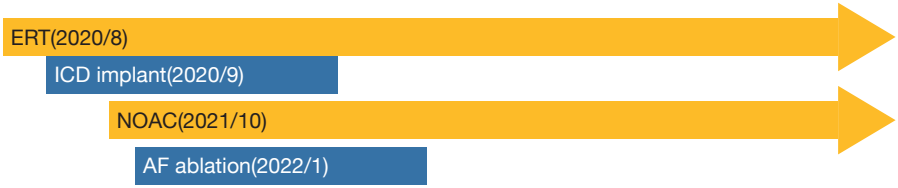

| | 2022/4/11 | 2022/7/4 | 2023/2/6 | 2023/7/4 |
|---|---|---|---|---|
| EF (%) | 43.45% | 18.4% | | 32% |
| LV Mass (g) | 293 g | 303.7 g | | 275 g |
| LVMi (g/m$^2$) | 108.17 g/m$^2$ | 131.55 g/m$^2$ | | 112.51 g/m$^2$ |
| LGE | **Yes** | **Yes** | | **Yes** |
| Thrombus | **Yes** | **Yes** | | **Resolved** |
| Troponin | 251.4 pg/mL | | | |
| NT pro-BNP | nil | nil | | 2982.1 |
| **Echo med E/E'** | 26.3 | | 12.2 | 19.9 |
| **Echo E/A** | 52/72 | | 40/62 | 58/41 |

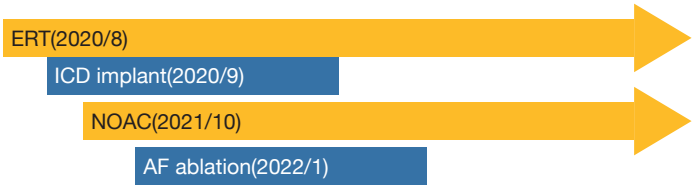


Follow-up ICD, echocardiography, and cardiac MRI showed:

- Although no VT were observed until 2022, intermittent non-sustained VTs were detected in 2023.
- After Af ablation, the patient’ s LVMI improved.
- Apical thrombus resolved after using DOACs.
- In 2023, cardiac MRI revealed poor left ventricular EF and elevated NT pro-BNP levels.

## *Coronary angiography*

Figure 21—22.

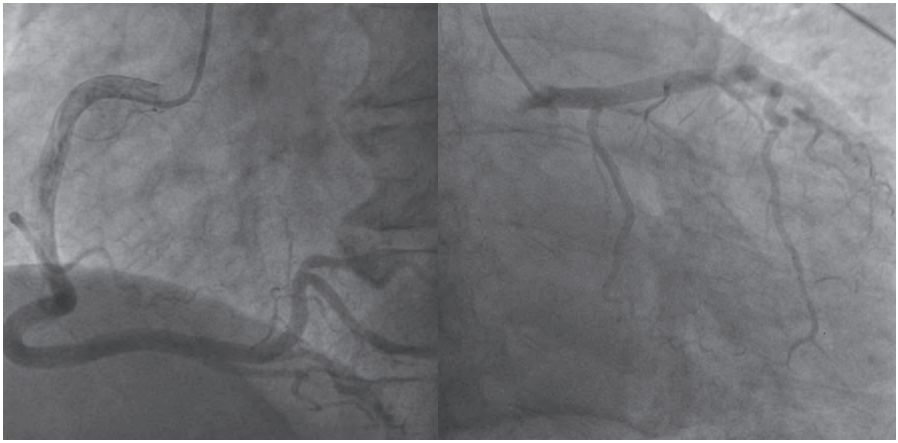

Coronary angiography revealed patent arteries with no evidence of CAD.

## *Left ventriculography*

Figure 23.

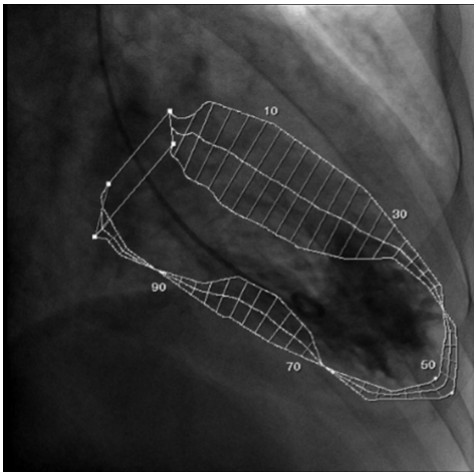


Left ventriculography showed normal motion of middle portion with apical area hypokinesis, suggesting apical ballooning syndrome.

## *Atrial fibrillation ablation*

Figure 24—27.

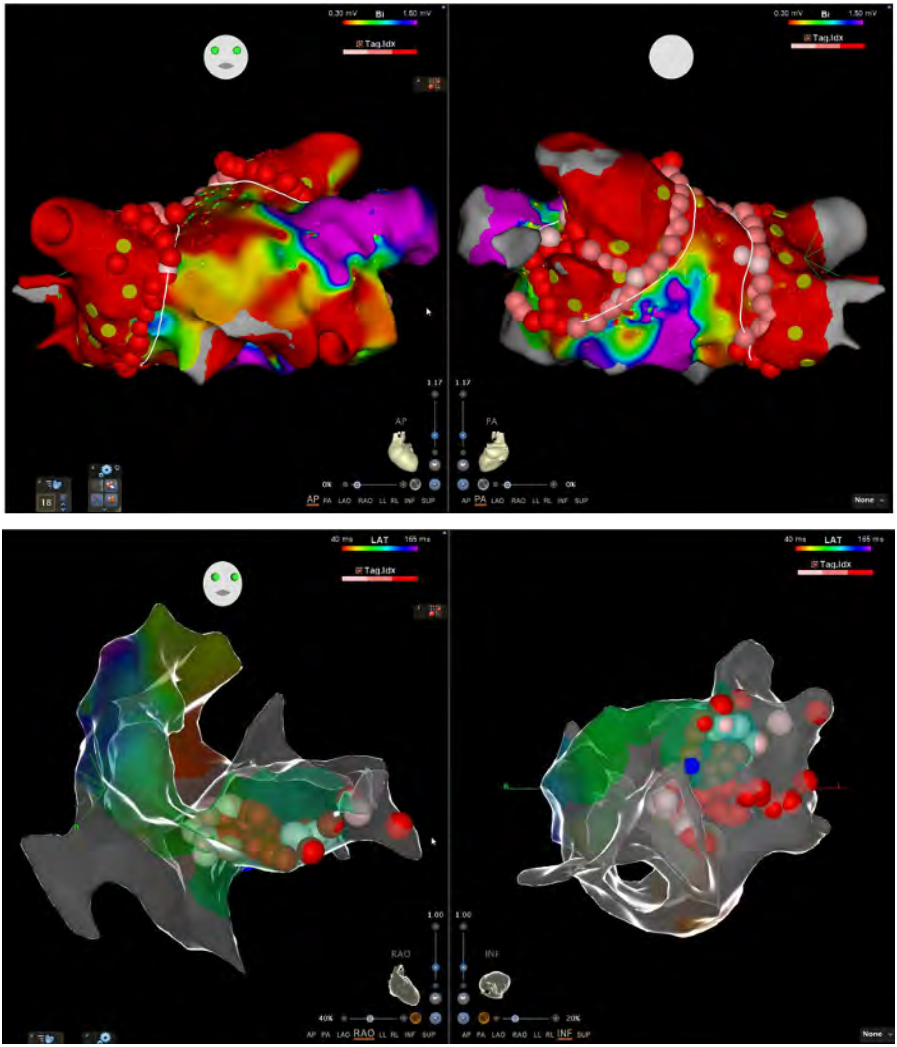


Ablation therapy for Af was performed in January 2022.

- Four pulmonary vein isolation, roof line ablation, cavotricuspid isthmus ablation.
- Ablation index: anterior wall-500, posterior wall-450, 40W.

## *Pedigree*

Figure 28.

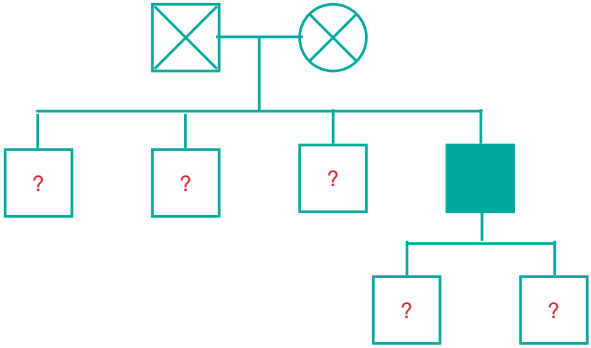


All the patient's siblings were not willing to undergo Fabry screening. No further information could be collected.

## Discussion

- In this case, based on the patient's clinical presentation and the results of cardiac MRI, the cause of the initial VT should be an apical aneurysm instead of apical ballooning syndrome. Compared to apical ballooning syndrome, which is a reversible response to stress, the cardiac MRI of the patient showed severe fibrosis of the left ventricular wall with extensive scar formation, which could not be reversed by ERT and might have induced ventricular arrhythmia.
- In patients with marked myocardial fibrosis, continuous deterioration of the left ventricular EF and hypertrophy are expected, and arrhythmia may occur. Thus, antiarrhythmic agents and medications for heart failure are necessary depending on the clinical presentation. Early ICD implantation in patients with new-onset arrhythmia may be helpful in monitoring heart rhythm. For patients with no ICD implantation or arrhythmia occurrence, frequent 12-lead EKG or 24-hour Holter follow-up may be indicated for the early detection of potential arrhythmia.
- For apical aneurysms with heart failure and reduced ejection fraction, the apical thrombus should be carefully examined during imaging studies. Anticoagulant should be prescribed if an apical thrombus is observed.
- According to the expert consensus published in the 2020 European Journal of Heart Failure, Af is observed in 5% of male and 3% of female patients with Fabry

disease, and the annual incidence of new-onset Af is approximately 6%. In patients with Fabry disease, all patients with Af and atrial flutter should receive anticoagulant with DOACs or warfarin unless contraindicated, regardless of their CHA2DS2-VASc scores. Maintenance of sinus rhythm, rather than rate control, is recommended for patients with Fabry disease and Af, and ablation therapy may be considered for the general population.

- One review article including 13 studies, 4185 patients with Fabry disease with a follow-up time of 1.2 to 10 years reported an 8.3% rate of death from any cause, 75% of which was due to cardiovascular problems, primarily sudden cardiac death. The meta-analysis showed that LVH and LGE were moderately associated with the occurrence of ventricular arrhythmia and that male sex, age > 40 years, LVH, LGE, and ventricular arrhythmia were risk factors with moderate association with sudden cardiac death. However, owing to the lack of randomized controlled trials, no parameter was strongly associated with ventricular arrhythmia or sudden cardiac death.
- One case series study reported three male patients with Fabry disease-related drug-refractory VT electrical storms. All three patients had extensive LGE in multiple segments of the left ventricular wall during ICD implantation. All patients underwent reentry VT and ablation therapy. Although VT was initially induced and terminated by radiofrequency ablation, a new VT was subsequently observed. These patients died 4 months, 3 weeks, and 3 years after the ablation procedures. Thus, ablation therapy may not be beneficial for patients with extensive LGE, and early intervention before severe myocardial fibrosis may be helpful.

## *References*


1. European Journal of Heart Failure (2020) 22, 1076–1096.
2. Europace (2018) 20, f153–f161.
3. European Heart Journal - Case Reports, 2021.

# Fabry Disease Case Book

## Case 10:

A case of the cardiac variant of Fabry disease with intermittent chest pain

陳俊兆醫師

## *Clinical pearls*

- If the patient's symptoms persist regardless of treatment, further evaluation should be performed to ensure that the diagnosis is accurate and appropriate treatment is administered.
- Fabry disease should be a differential diagnosis in cases of unexplained LVH.
- Early diagnosis is important for patients with Fabry disease. Given that the progression of left ventricular fibrosis leads to worse outcomes, ERT should be initiated as soon as possible.
- Considering the cost-effectiveness of ERT, further studies on the clinically relevant predictors of treatment outcomes are necessary.

## *Patient profile*

### Case presentation

- A 63-year-old female patient presented with intermittent chest pain that had persisted for several years. She had visited several clinics and hospitals but had not received a conclusive diagnosis.
- In 2011, the patient was admitted to our hospital for intermittent chest pain. Cardiac echography showed marked concentric LVH with preserved left ventricular EF. The treadmill stress test revealed ischemia; however, no significant stenosis was observed on coronary angiography.
- As CAD was excluded, hypertension- or gastroesophageal reflux-related chest pain was suspected.
- The patient visited several hospitals for a second opinion between 2011 and 2015 because her symptoms persisted. Coronary angiography performed at one of the hospitals showed no evidence of stenosis, which was similar to the result obtained at our hospital.
- In 2017, the patient visited our emergency department with a complaint of intolerable chest pain. Laboratory tests, EKG, and echocardiography performed on admission revealed elevated troponin level, LVH with a strain pattern, and preserved left ventricular function. CAD was excluded based on the results of venous-phase coronary computed tomographic angiography.
- Considering that CAD was excluded again and the patient had unexplained LVH, Fabry screening was performed, and the diagnosis was confirmed in 2018.
- In September 2018, pathological findings of myocardial biopsy showed myelin

body accumulation in cardiomyocytes.

- ERT performed using agalsidase alfa was initiated in December 2018. After ERT, the patient’s left ventricular mass and LVMI deteriorated, her left ventricular EF remained preserved, and her diastolic function improved, as suggested by the decreasing E/E’.
- The patient visited our emergency department in 2021 because she had intolerable chest pain. Frequent VPCs, APCs, and paroxysmal AFs that lasted for several minutes were recorded during a 24-hour Holter examination. Thus, blockers and anticoagulants were administered for the treatment of the arrhythmias.
- Review of the cardiac MRI results obtained in 2019, 2021, and 2023 revealed no significant changes in the patient’s LGE.

## Medical history

- Well-controlled hypertension
- Hyperlipidemia
- Gastroesophageal reflux disease

## Physical examination

- No angiokeratoma
- No neuropathic symptoms
- Slight hearing impairment

## *Laboratory panels*

### Figure 1.

| Systemic: | Reference | 201806 |
|---|---|---|
| Hb | 12-17 g/dL | 12.9 |
| Plasma Lyso-Gb3 | <1.8 ng/ml | **2.4** |
| GALa enzyme activity | >2.05 umol/L/h | **1.04** |
| GLA mutation | -- | IVS4+919G>A |

- The patient was diagnosed with the cardiac subtype of Fabry disease based on the observation of low α-GAL enzyme activity, elevated plasma lyso-Gb3 level, and positive IVS4+919g>A mutation.

### Figure 2—3.

| Renal | Reference | 201704 | 202007 | 202210 | 202212 |
|---|---|---|---|---|---|
| Creatinine | 0.40-1.30 mg/dL | 0.63 | 0.62 | 0.75 | 0.74 |
| eGFR | >90 mL/ min/1.73m | 101 | 102 | 81 | 83 |
| Urine analysis | | No proteinuria | No proteinuria | No proteinuria | No proteinuria |

| Cardiac | Reference | 201704 | 201806 | 202007 | 202109 | 202210 | 202212 |
|---|---|---|---|---|---|---|---|
| Troponin I | <0.04 ng/mL | 0.12 | 0.24 | 0.64 | 1.56 | 1.91 | |
| NT pro-BNP | <125 pg/mL | | 307.1 | | 549.2 | 414 | 514 |

- Normal renal function with no proteinuria
- Sustained elevated troponin I levels regardless of the administration of ERT
- Elevated NT pro-BNP level was first documented in 2021 when the arrhythmias occurred.

## *Chest radiography*

Figure 4.

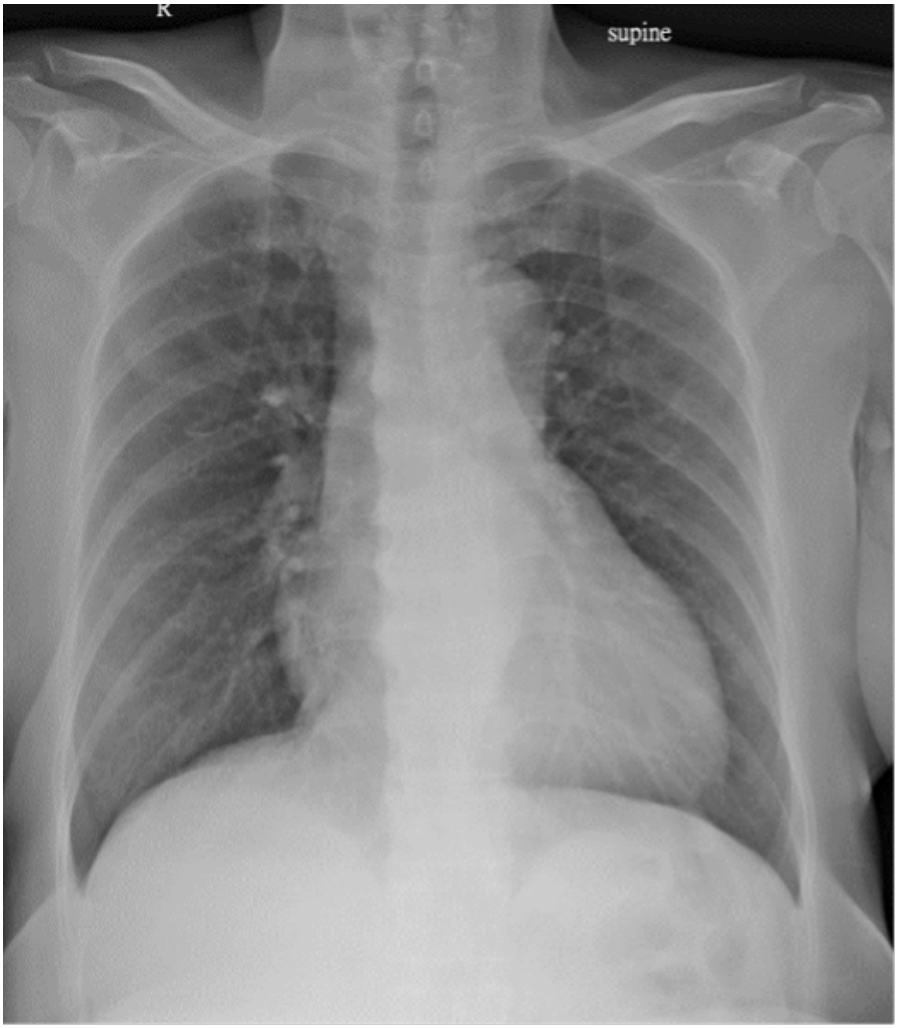


- Chest radiography performed in 2017 showed cardiomegaly with no pulmonary edema.

## *Electrocardiography*

### Figure 5.

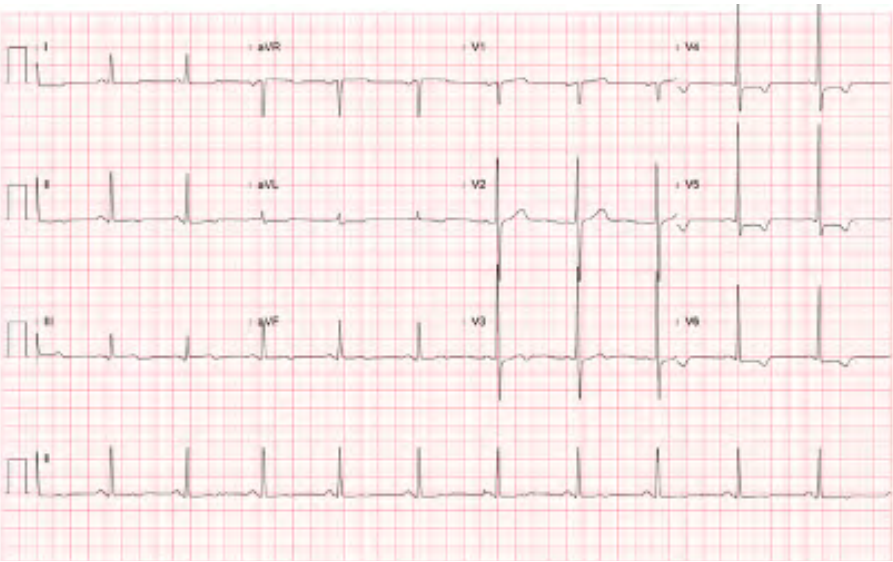


EKG performed in 2017 revealed the following:

- Sinus rhythm; no bradycardia
- No short PR (PR interval, 140 ms).
- Marked LVH with inverted T waves and ST depression on lateral leads.

## *Cardiac echography*

### Figure 6—7.

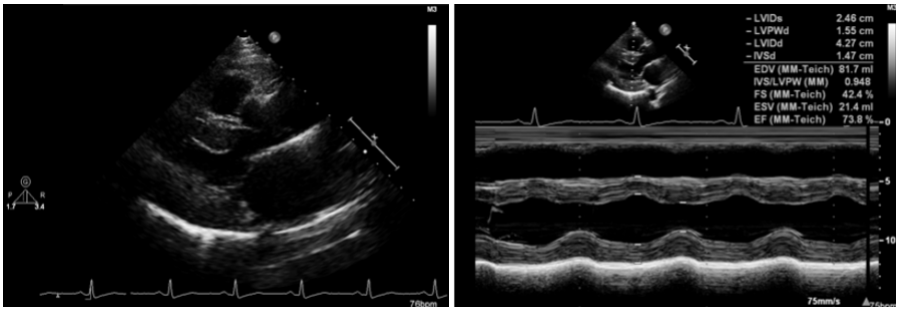


Cardiac echography performed in 2011 showed the following:

- Preserved left ventricular function (EF, 73%).
- Concentric LVH; IVSd, 14 mm; LVPWd, 15mm; LVEDd, 42mm.
- Left ventricular mass, 236.74 g; LVMI, 158.26.

### Figure 8—12.

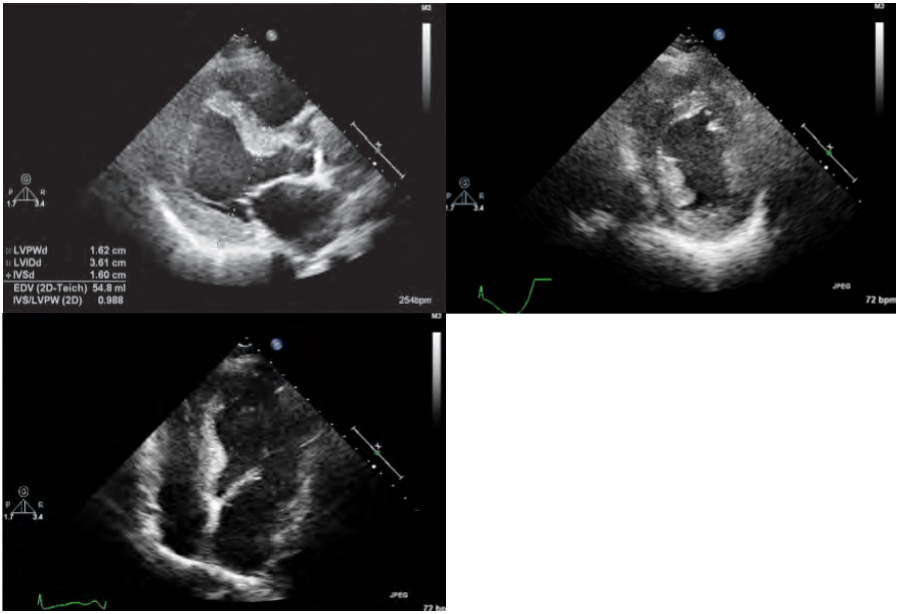

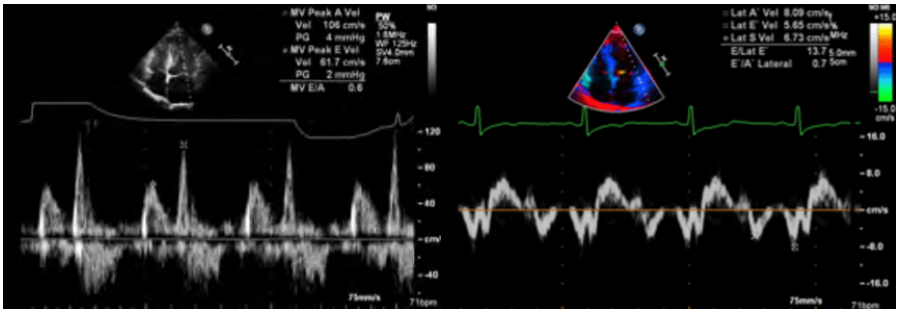


Echocardiography performed in 2017 showed the following:

- Preserved left ventricular function (EF: 69%).
- Concentric LVH; IVS, 16 mm; LVEDd, 36 mm; LVPWd, 16 mm.
- Left ventricular mass, 223.4 g; LVMI, 144 g/m2.

Figure 13—14.

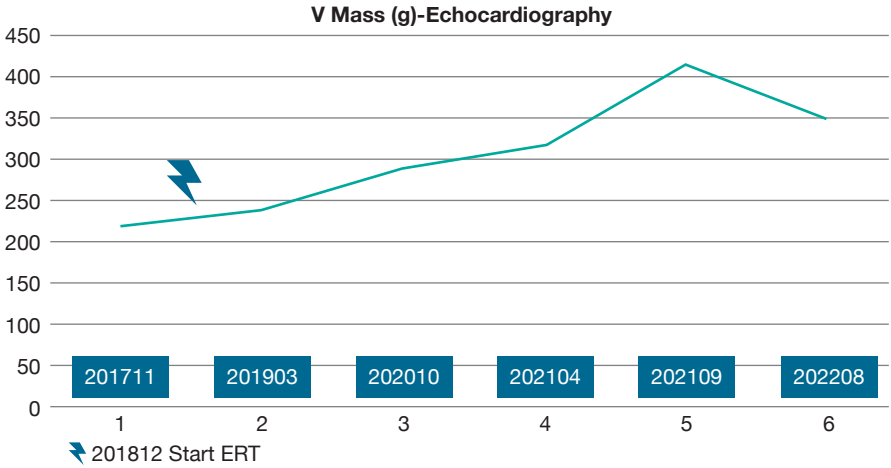


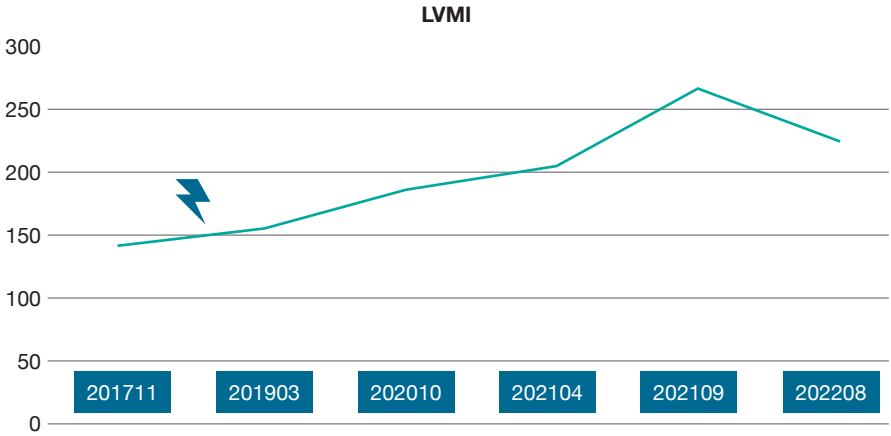


- The patient's left ventricular mass and LVMI continuously deteriorated after ERT.

## Figure 15.

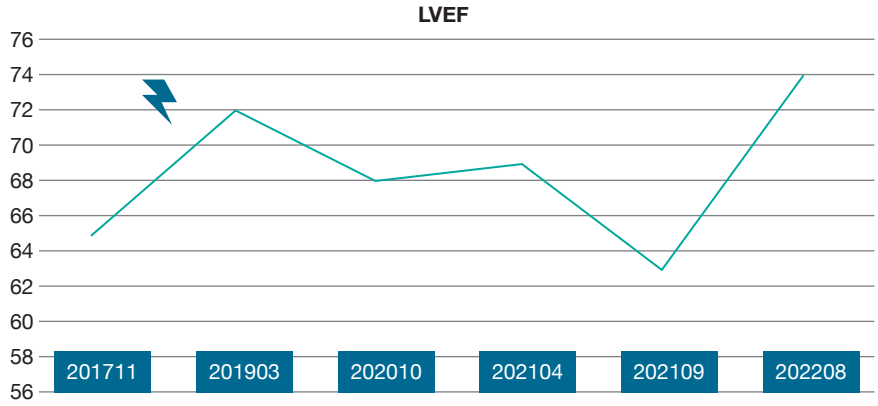


- The patient's left ventricular EF remained preserved before and after ERT

## Figure 16.

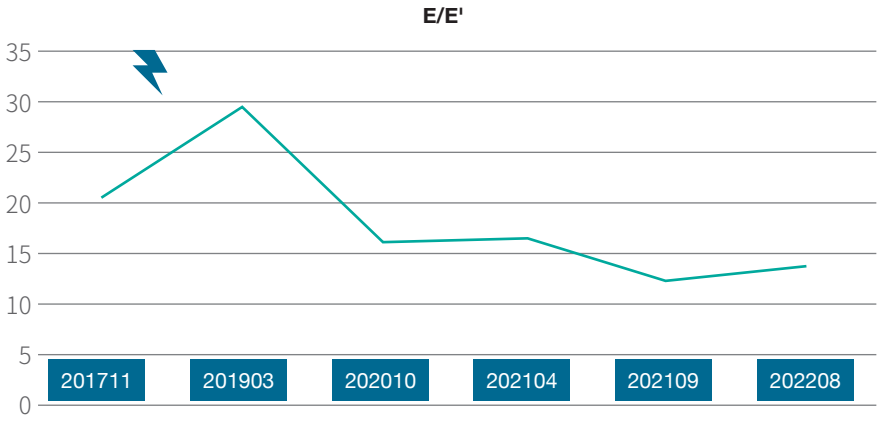


- The patient's E/E' gradually decreased after ERT

## *Coronary angiography*

Figure 17—18.

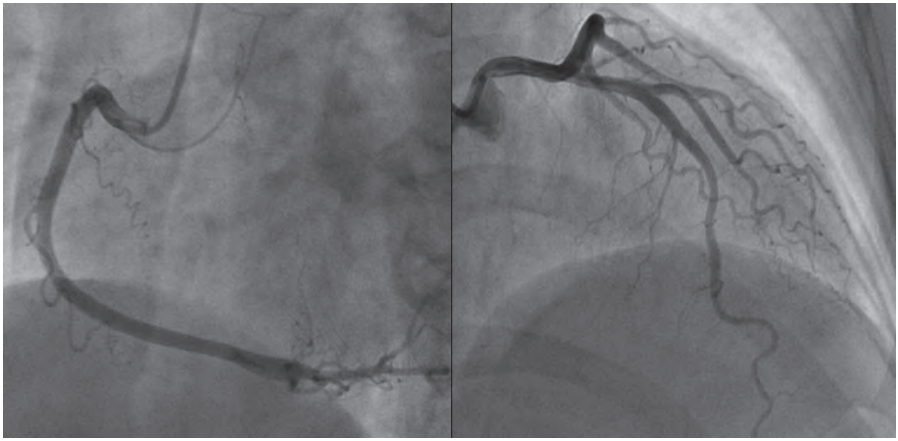

- Coronary angiography performed in 2011 showed insignificant stenosis in the left anterior descending artery.

## *Venous-phase coronary computed tomographic angiography*

Figure 19—20.

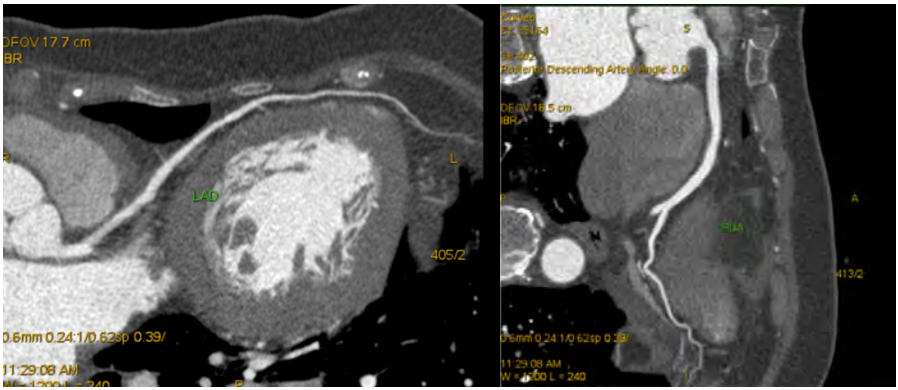


- Venous-phase coronary computed tomographic angiography was performed in 2017 because the patient was unwilling to undergo coronary angiography, and the results showed no obvious evidence of stenosis.

## *24-hour Holter monitoring*

### Figure 21—22.

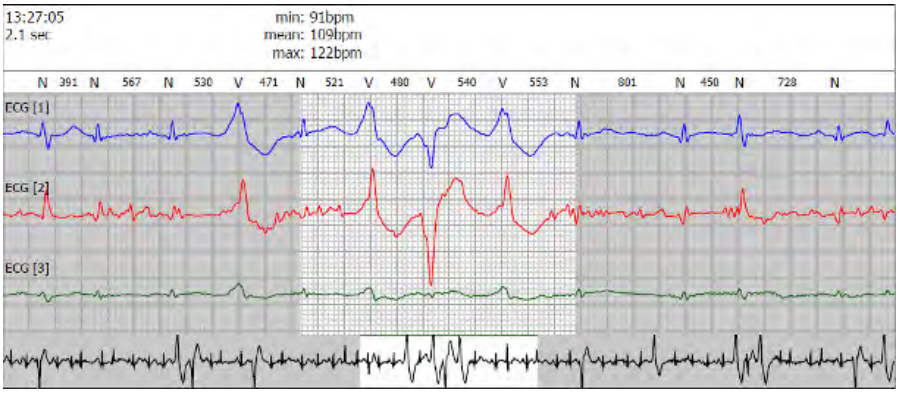


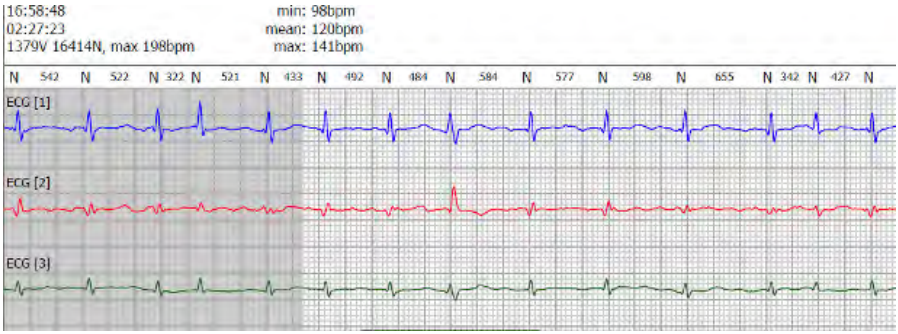


24-hour Holter examination revealed frequent VPCs with multiform patterns, APCs, and long-lasting paroxysmal AFs for several minutes.

## *Cardiac magnetic resonance imaging*

Figure 23—28.

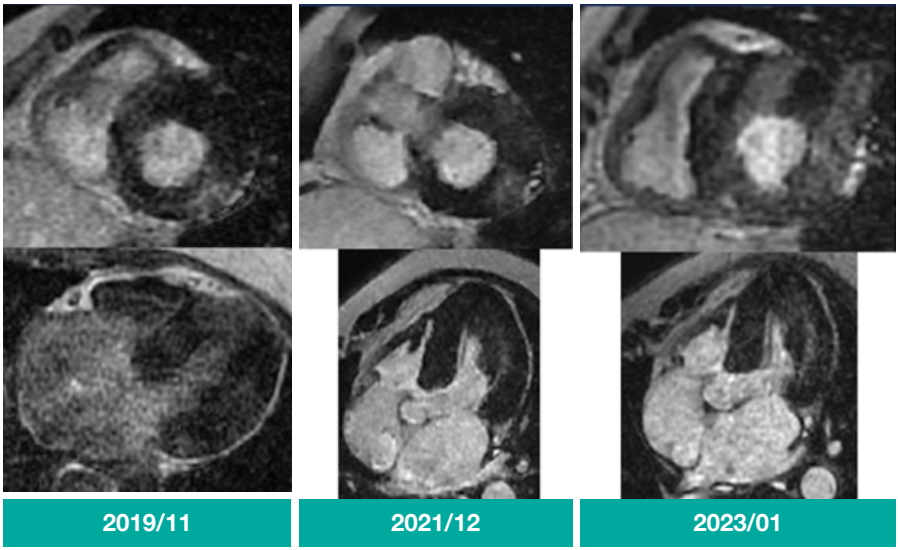


- Cardiac MRI performed in 2019, 2021, and 2023 revealed adequate left ventricular EF, concentric LVH, and fibrosis. LGE was detected on lateral and inferolateral walls, and no significant change occurred during these four years.

## *Pedigree*

Figure 29.

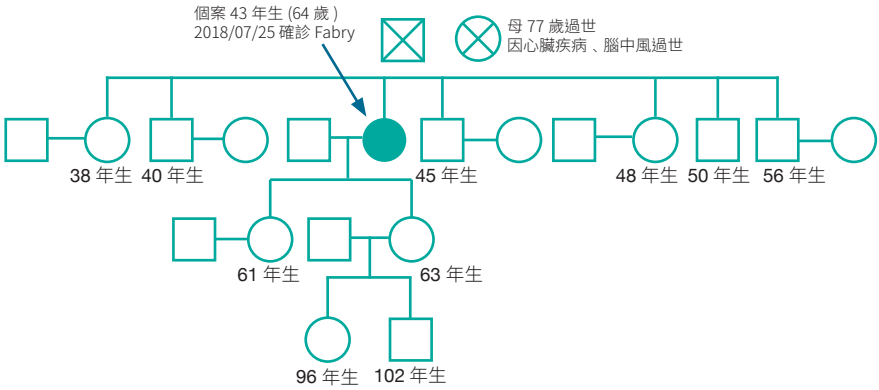


- No family member was willing to undergo screening for Fabry disease because they had no clinical symptoms and were considering the medical insurance implications of the screening.
- The patient's grandson has a history of seizures and periodically visits the neurology clinic for follow-up.
- The patient's mother died of cardiac disease and stroke and her elder brother died of hyperkalemia, both of which may have been associated with Fabry disease.

## *Discussion*

- The patient in this case had intermittent chest pain and mild elevated troponin/Nt-proBNP levels, and underwent coronary angiography twice; however, no evidence of coronary artery stenosis was found. For patients who present with recurrent chest pain and elevated cardiac enzyme levels but are diagnosed with myocardial infarction with non-obstructive coronary arteries alone, further evaluation should be conducted to determine the exact cause of their symptoms other than CAD. Screening for Fabry disease should be included in the evaluation because Fabry disease is associated with microvascular changes.
- ERT is important in the treatment of Fabry disease; however, it cannot delay or reverse the progression of left ventricular fibrosis. In a German study, the extent of fibrosis, which was determined using cardiac MRI, gradually increased even though ERT was administered. In addition, the existing fibrosis did not

regress after ERT. Notably, blood collagen markers of fibrosis are not helpful for predicting the progression of fibrosis. Thus, MRI plays an important role in evaluating the progression of Fabry disease.

- The proposed evolution of cardiac involvement in Fabry disease includes three stages: storage, inflammation-hypertrophy, and fibrosis-dysfunction. The efficacy of ERT is expected to be good if a diagnosis can be established during the inflammation stage, in which common presentations include chest pain, arrhythmias, and elevation of high-sensitivity troponin T level. However, reduced ERT efficacy can be expected in patients with existing HFrEF who are entering the dysfunction stage of the disease. In a study on heart failure in Fabry disease, patients with HFpEF showed an elevated all-cause mortality rate and worsened heart failure compared with those without HF despite receiving ERT.
- In a previous study, patients with Fabry disease showed increased LVMI after 10-year ERT, which was not associated with sex or baseline LVH. In contrast, another study demonstrated that baseline LGE is significantly associated with the outcomes of Fabry disease, and that a high annual increase in fibrosis is significantly associated with poor outcomes. Based on the findings of these two studies, periodic cardiac MRI and a clear definition of the extent of fibrosis are crucial for evaluating disease progression in Fabry disease.
- In a 2013 study on the correlation between EKG and cardiac fibrosis in patients with Fabry disease, a widened QRS duration and higher left ventricular Sokolov index predicted LVMI on MRI. However, none of the single EKG parameters was significantly different between the patients with fibrosis and those without fibrosis. In addition, although baseline ST-T alternation is not strongly correlated to LGE on MRI, almost all the patients without baseline ST-T alternation findings showed no LGE on MRI.

## *References*


1. Am J Cardiol 2014.
2. Pieroni M, et al. J Am Coll Cardiol 2021;77:922-936.
3. Drug Des Devel Ther 2019;13:3705–3715.
4. Am J Cardiol 2014.
5. J Inherit Metab Dis 2013.
6. ESC Heart Fail 2022;9:4043-4052.

# Fabry Disease Case Book

## Case 11:

A patient with chest tightness

郭泠醫師

## *Clinical pearls*

- Comprehensive evaluation, including cardiac MRI and Fabry screen for patients with unexplained LVH or HCM, is important for developing accurate and early diagnosis.
- The presentation on cardiac MRI of Fabry cardiomyopathy can mimic that of HOCM, especially in patients with borderline decrease of T1 sequencing signal.
- Patients with IVS4 variant Fabry disease may not experience remarkable extracardiac symptoms, which makes the diagnosis primarily reliant on a comprehensive evaluation of their cardiac symptoms.

## *Patient profile*

### Case presentation

- A 44-year-old male patient visited our cardiology clinic in 2022 with chest tightness, mild dyspnea on exertion, and a strong heartbeat sensation lasting for six months.
- The patient visited our cardiology clinic in 2012 with a chief complaint of palpitations. LVH was found on EKG; however, the 24-hour Holter examination detected no remarkable findings.
- In 2015, the patient revisited the cardiology clinic because of palpitations and chest discomfort. Mild LVH was also observed on EKG, and echocardiography revealed mild concentric LVH with a normal left ventricular EF.
- The patient presented with similar symptoms in 2018. No specific interventions were performed after the three visits.
- During a visit in 2022, HOCM with high LVOT late systolic pressure gradient was observed on echocardiography.
- Because the patient had no extracardiac symptoms, Tc-99m PYP scintigraphy was performed, and transthyretin cardiac amyloidosis was excluded.
- Cardiac MRI revealed HFpEF and LVH with borderline decreased T1 signals and patchy LGE. Cardiac variant Fabry disease was diagnosed based on low alfa-galactosidase enzyme activity, genetic testing positive for IVS4 mutation, and GB3 deposition in cardiac myocytes by endomyocardial biopsy.
- The patient is currently awaiting further treatment. His medications include spironolactone, carvedilol, dapagliflozin, clopidogrel, and valsartan.

## Past and personal history

- The patient denied smoking.
- No hypertension, diabetes mellitus, dyslipidemia, or leg edema were diagnosed or observed.

## *Chest radiography*

Figure 1.

Chest radiograph in 2022 showing borderline cardiomegaly

## *Electrocardiography*

Figure 2—6.

**2012/03**

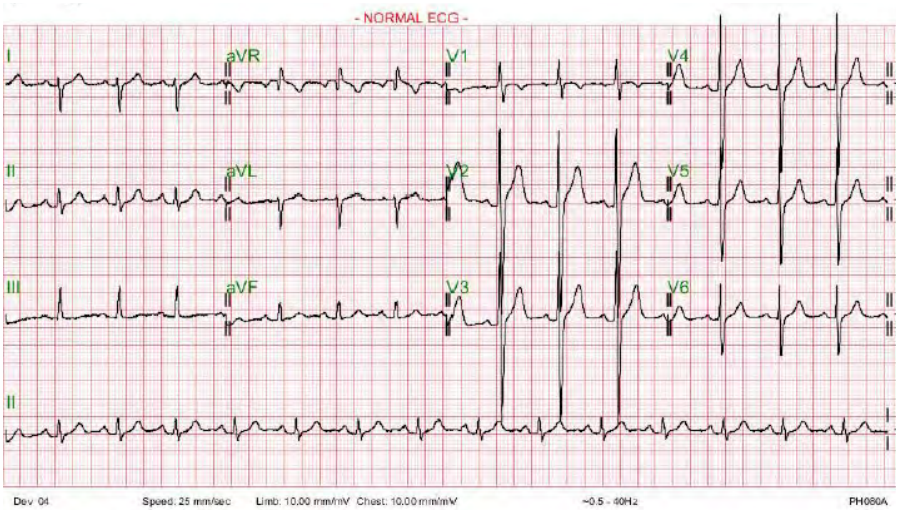


**2013/01**

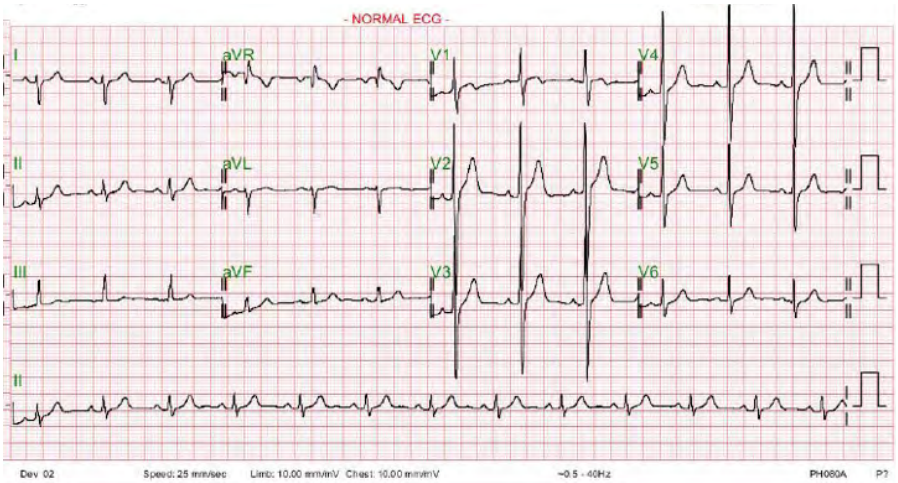

## 2015/11

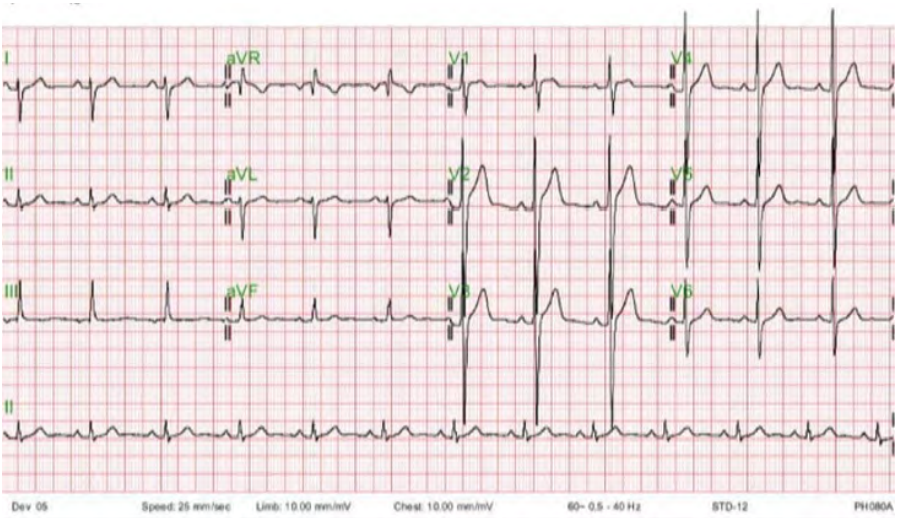


## 2018/01

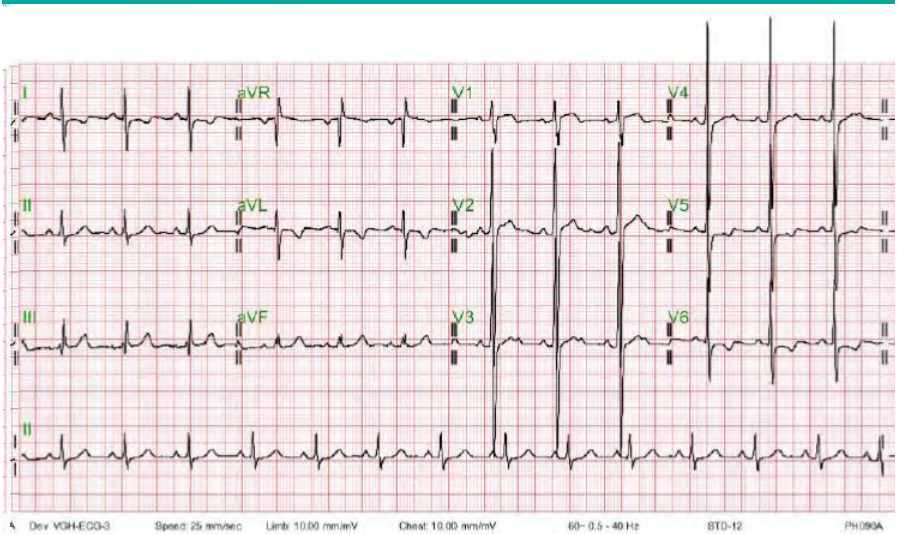

**2021/02**

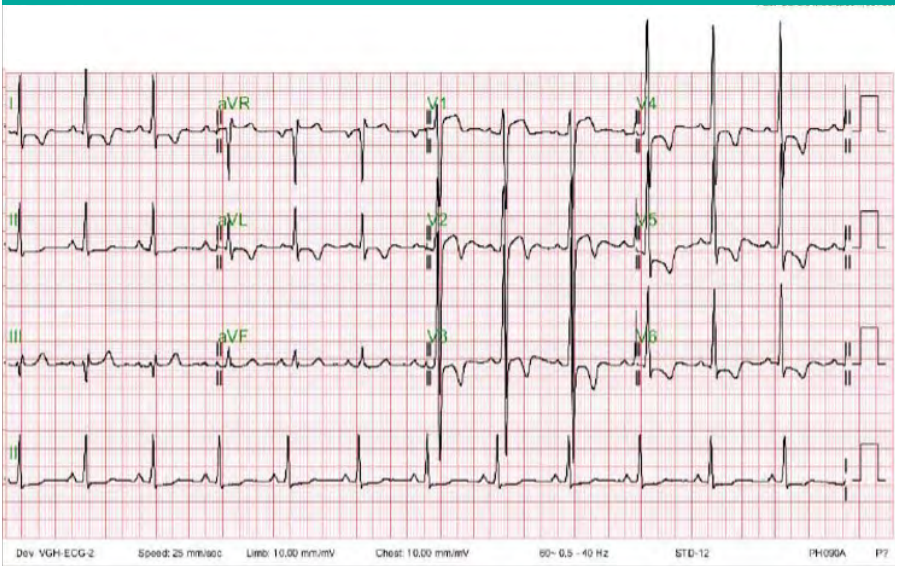


Serial EKG from 2012 to 2021

- LVH can be observed on the EKG obtained in 2012.
- Strain pattern (T wave inversion) started in 2018.
- EKG obtained in 2021 showed a progressively significant LVH strain pattern.

## *Cardiac echography*

Figure 7—10.

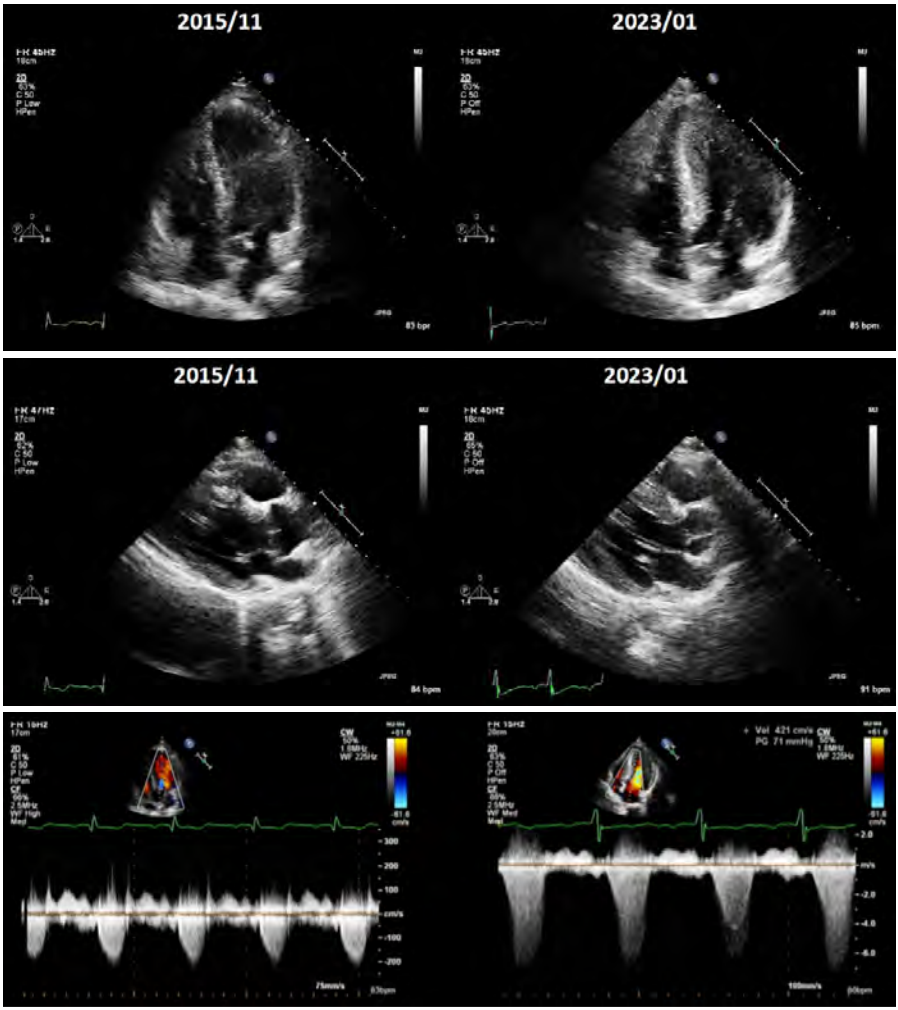


Cardiac echography in 2015 and 2023

- Four chamber and parasternal long-axis views showed more marked septal wall hypertrophy.
- No pressure gradient was noted in 2015; however, an LVOT late systolic pressure gradient of up to 91 mmHg was documented in 2023.
- There was preserved left ventricular EF from 67%–57%.

## *Tc-99m pyrophosphate scintigraphy*

Figure 11—12.

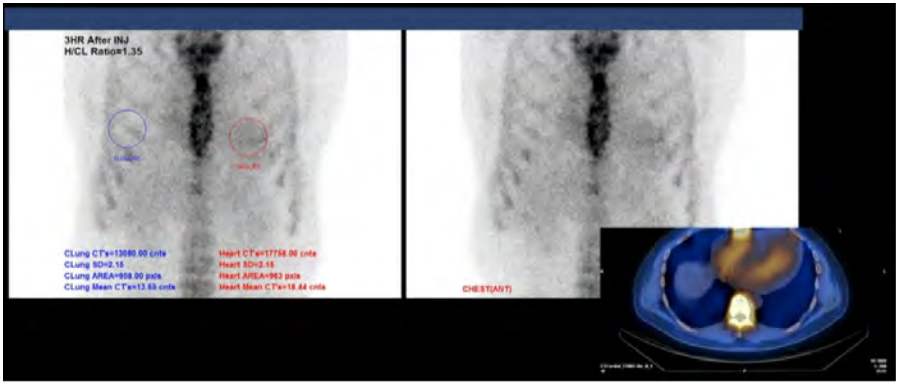


Tc-99m PYP scintigraphy revealing no evidence of transthyretin cardiac amyloidosis; PYP uptake observed in blood pool but not in myocardium

## *Cardiac magnetic resonance imaging*

Figure 13—36.

Cine images

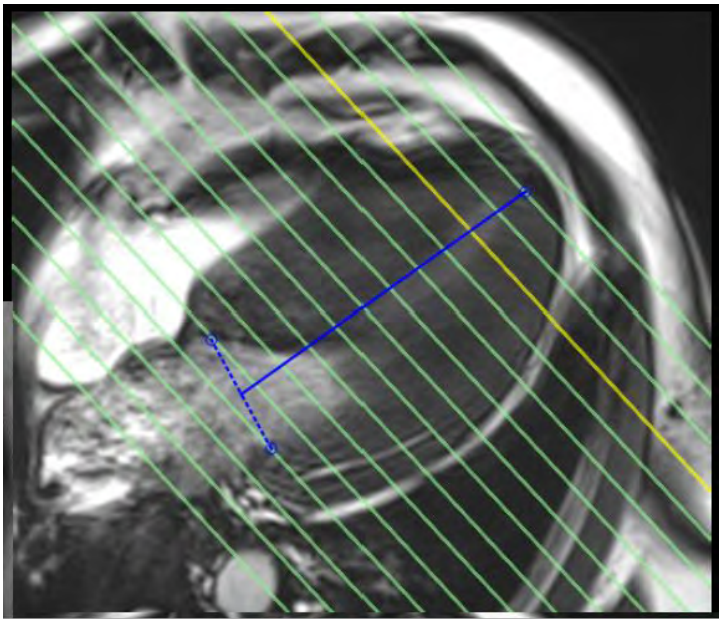

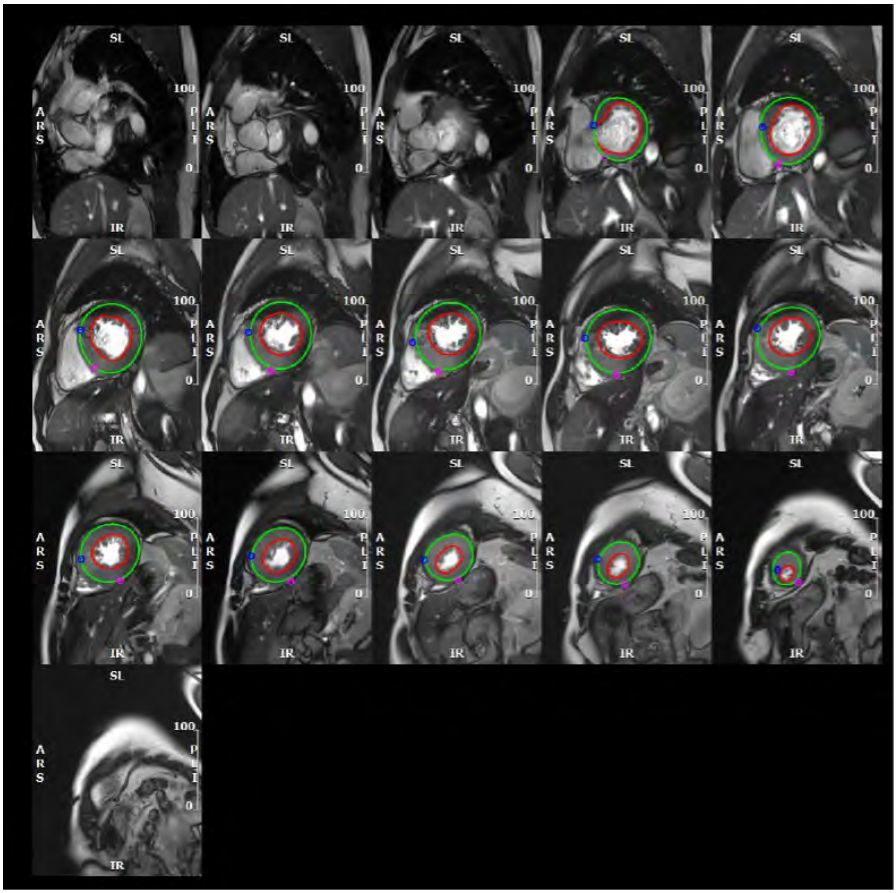
SL
100
A
R
S
P
L
I
0
IR

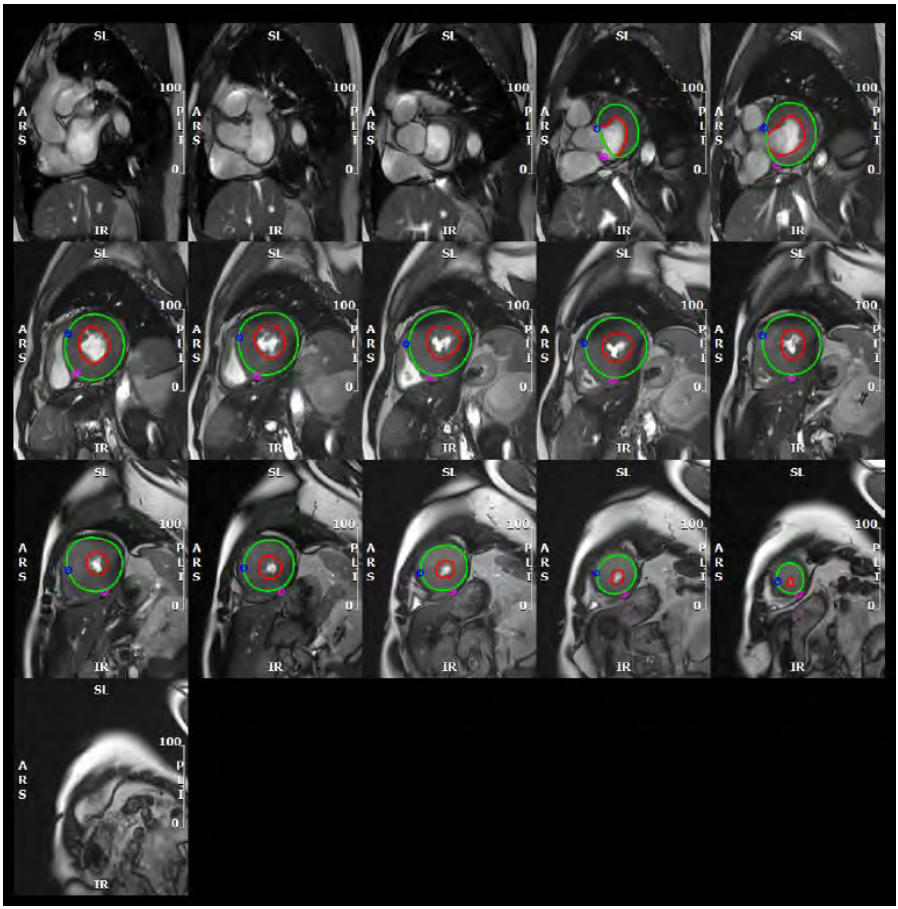
SL
100
A
R
S
P
I
L
0
IR

| | |
|---|---|
| EDV: | 199.41 ml |
| ESV: | 99.53 ml |
| SV: | 99.88 ml |
| **EF:** | **50.09 %** |
| CO: | 8.55 l/min |
| CI: | 4.86 1/min/$m^2$ |
| HR: | 85.6/min |
| **Myo Mass (DIAST):** | **290.84 g** |
| Myo Mass (Syst): | 313.23 g |
| Phase Diastole: | 24 |
| Phase Systole: | 15 |
| EDV/H: | 121.59 ml/m |
| **EDV/BSA:** | **113.30 ml/$m^2$** |
| ESV/H: | 60.69 ml/m |
| **ESV/BSA:** | **56.55 ml/$m^2$** |
| SV/H: | 60.90 ml/m |
| SV/BSA: | 56.75 ml/$m^2$ |
| Myo Mass/H (Diast): | 177.34 g/m |
| Myo Mass/BSA (Diast): | 165.24 g/$m^2$ |
| Myo Mass/H (Syst): | 190.99 g/m |
| Myo Mass/BSA (Syst): | 177.97 g/$m^2$ |

Wall thickness

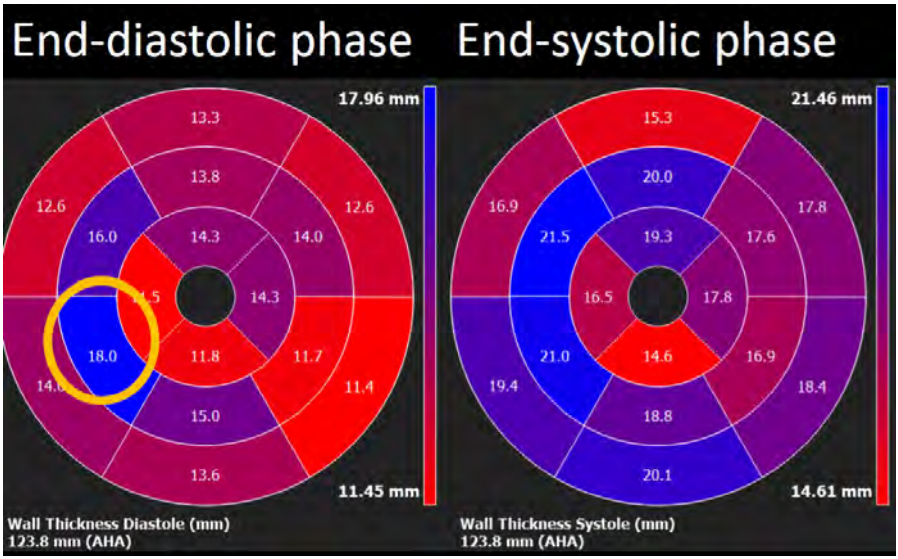


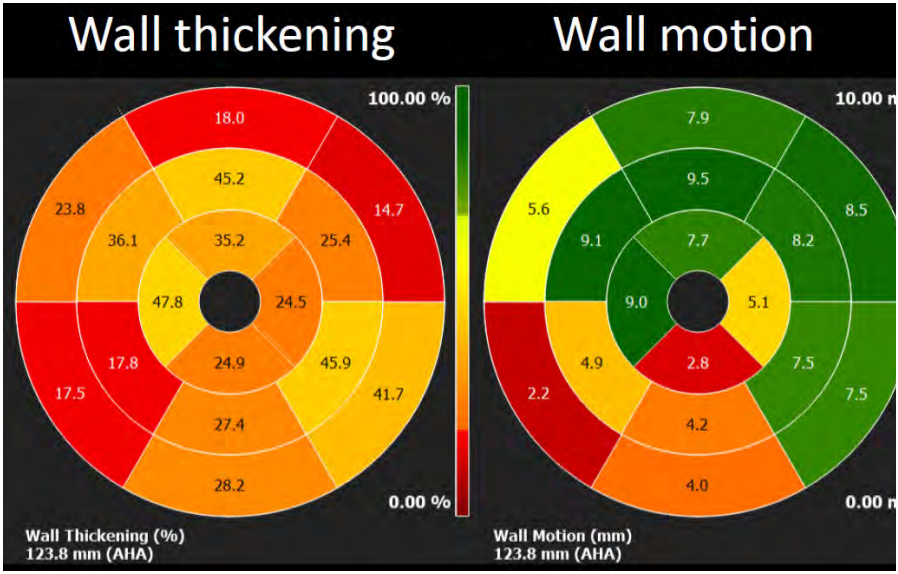

## T1 mapping

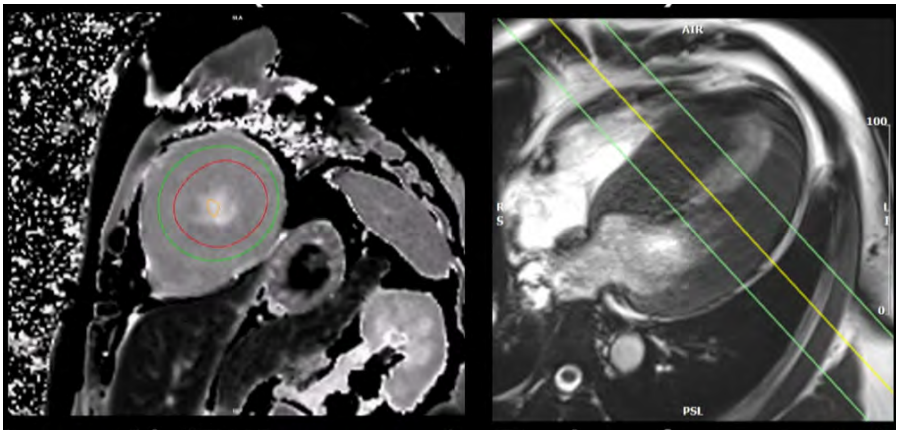


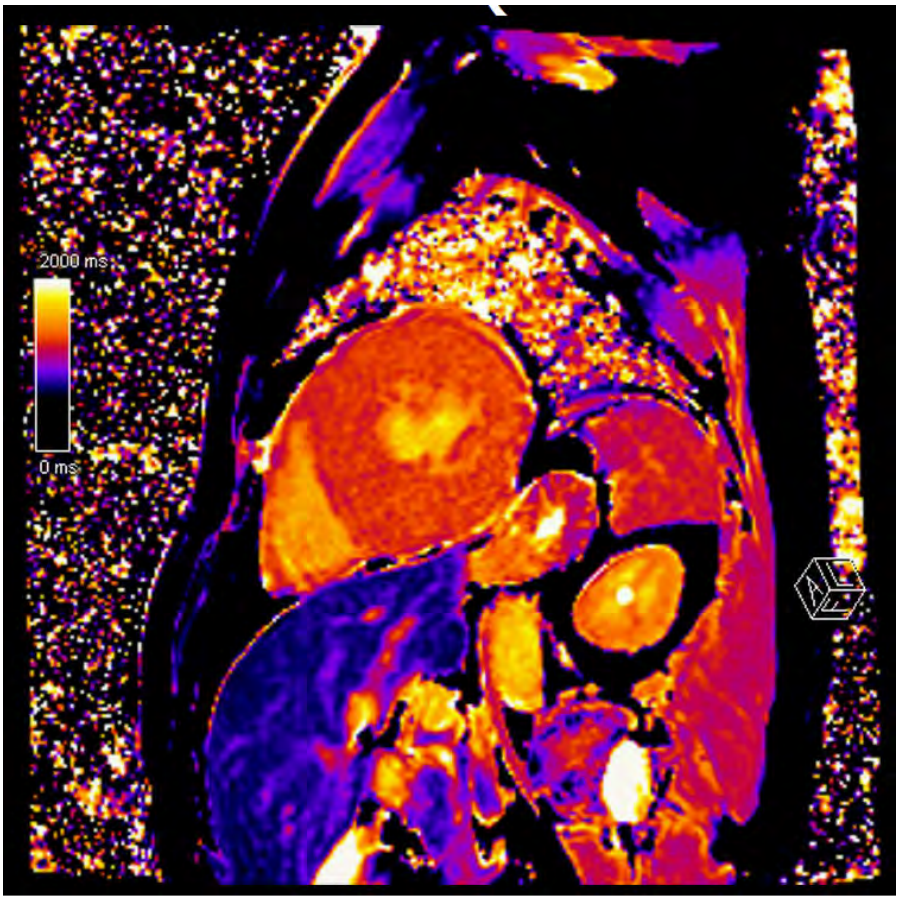

T2 mapping



Modified Look-Locker Imaging (MOLLI) sequence (using pre- and post-contrast T1 mapping to generate in-line ECV mapping).

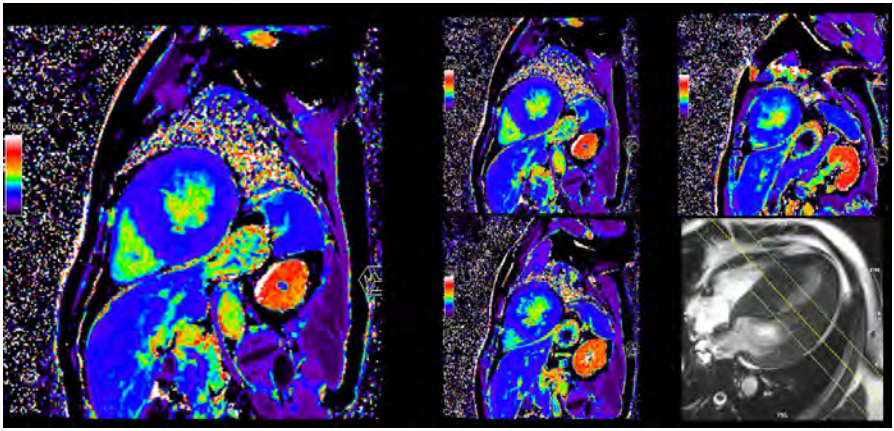

LGE images

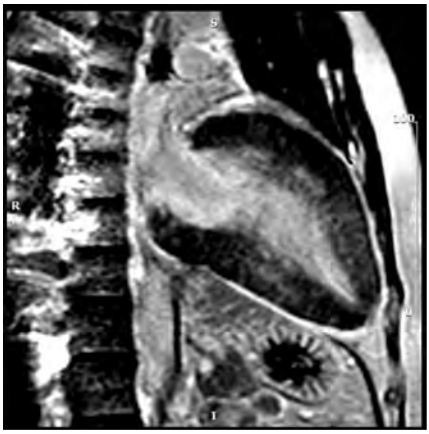

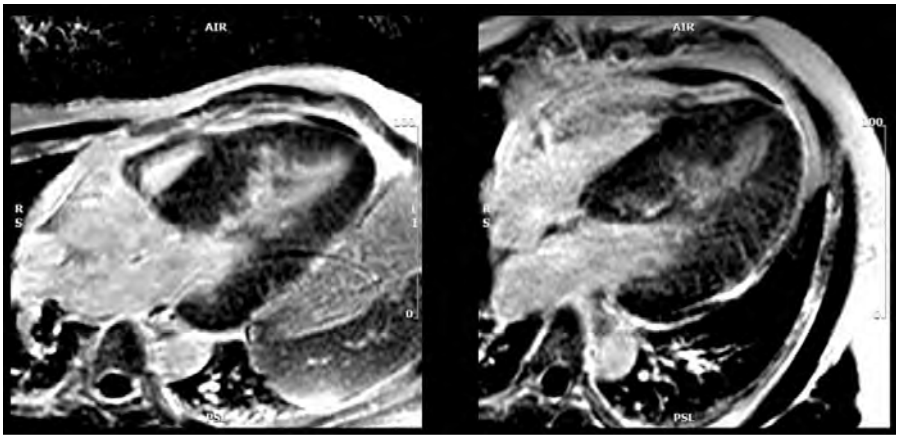


Cine images and corresponding LGE images obtained at the end-diastolic phase

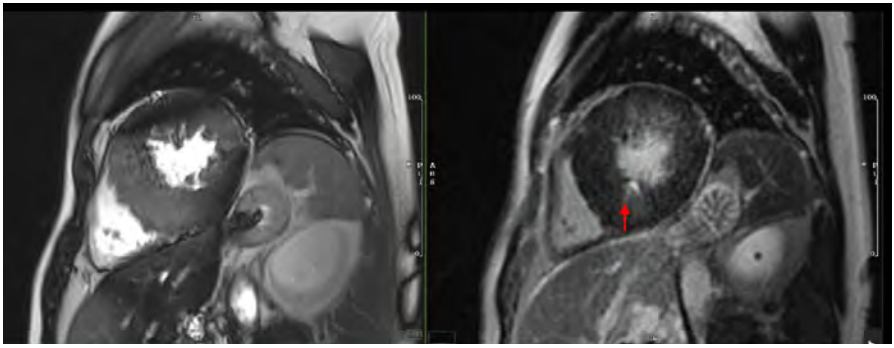

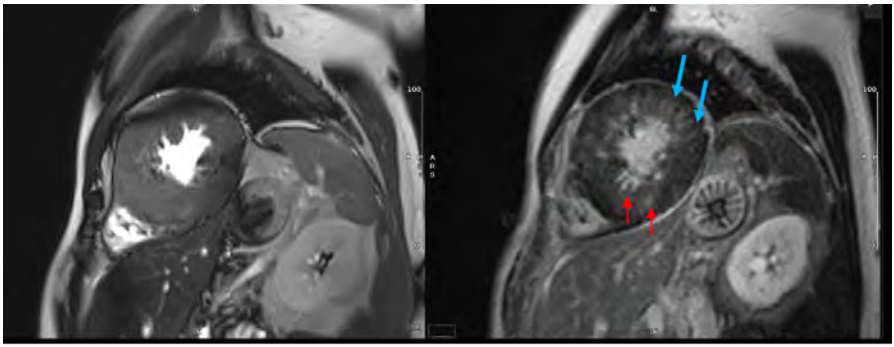

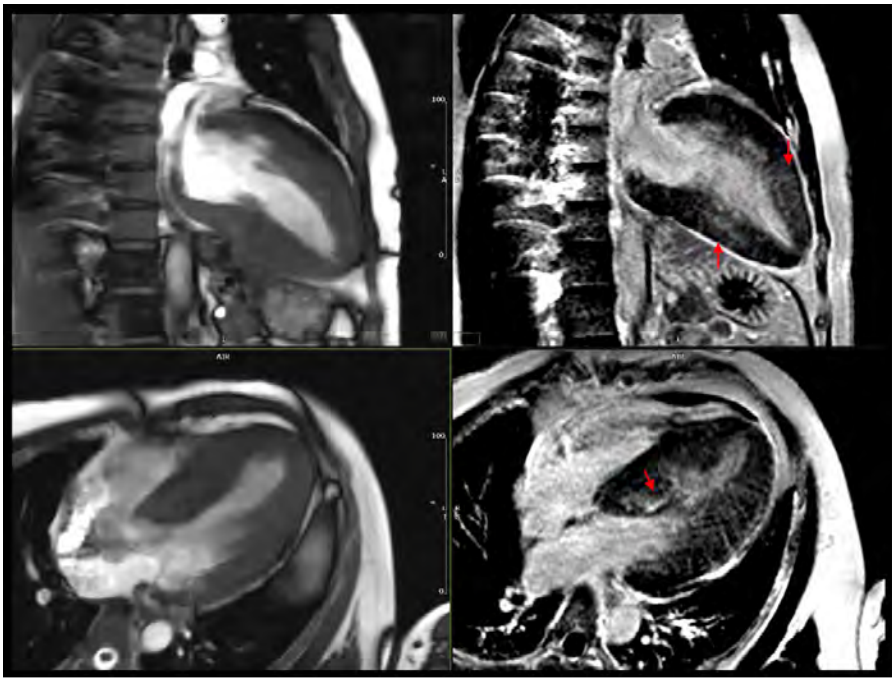

- HFpEF (left ventricular EF 50%)
- Thickest wall: 18 mm at AHA segment 9
- Patchy LGE at AHA segments 3,4,8,9,12
- Native T1 value within the lower limit of the normal range, 1280 ± 172ms (Siemens Vida 3T MR scanner native T1 value: reference 1156-1355 ms); at the Fabry cardiomyopathy stage of pseudonormalization of T1 value.
- Native T2 value, 39.2 ms; no evidence of edema.

- Normal ECV value, 27 ± 3%, with focally elevated ECV value corresponding to LGE.
- LVOT flow: underestimated due to technical problems.

## *Cardiac biopsy*

### Figure 37

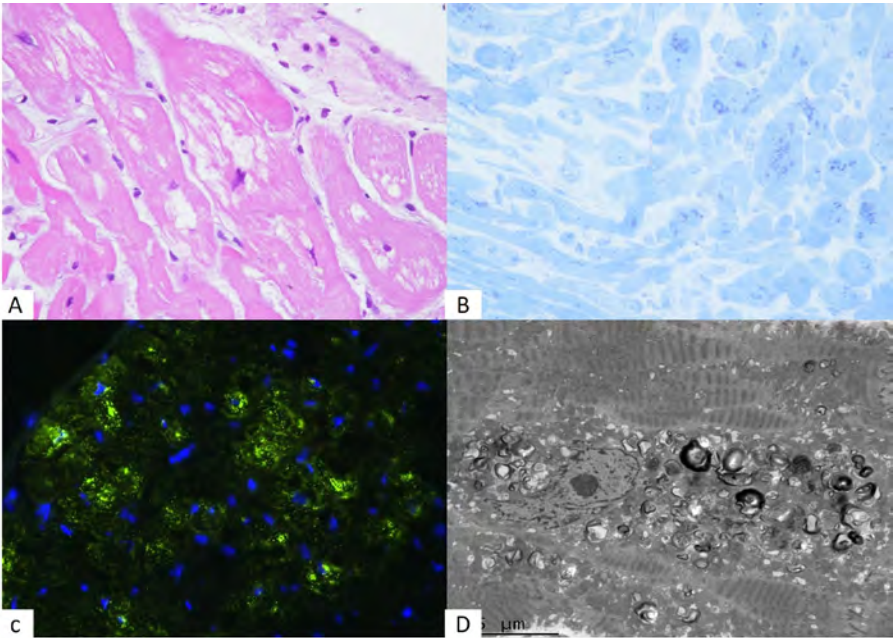


(A&B)Light microscopy with H&E stain and Masson trichrome stain: cytoplasmic vacuolization in cardiomyocytes; (C): Glybotriaosylceramide (Gb3) accumulation can be demonstrated with anti-Gb3 antibody by immunofluorescence; (D): The presence of myelin bodies in cardiomyocytes. Above findings confirmed the cardiomyocytes with Gb3 accumulation, compatible with Fabry disease. (Courtesy by Dr. 張富邦 )

## Discussion

- The patient's native T1 value was within the lower limit of the normal value (the reference native T1 value [1156-1355 ms] was obtained from 20 healthy volunteers using a Siemens Vida 3T MR scanner in Taipei Veterans General Hospital). Based on the Fabry disease staging criteria, he was classified as being in LVH/fibrosis stage with marked LVH observed on echocardiography and cardiac MRI, and pseudonormalization of native T1 value obtained by MOLLI sequence on MRI.
- Considering the long waiting time for Fabry screening results and appointments for Tc-99m PYP scintigraphy and cardiac MRI, we planned all the studies simultaneously instead of sequentially. However, this patient was too young for the onset of transthyretin cardiac amyloidosis, and the frequency of concurrent amyloidosis and Fabry disease is considerably rare; therefore, Tc-99m PYP scintigraphy may not have been necessary in the current case.
- The patient had no specific risk factors or family history of cardiomyopathy; however, he experienced marked LVH at a young age, which progressed within the previous ten years, accompanied by HOCM with a high-pressure gradient. However, HOCM is not a common presentation of Fabry disease, and marked LVH is usually observed in male patients aged > 50 years. Further surveys of concurrent sarcomere protein mutations should be conducted.
- Symptoms resulting from severe LVH in Fabry disease may be relieved by alcohol ablation or myectomy, depending on the thickened site. However, these procedures and surgeries cannot delay or stop the progression of Fabry disease; thus, ERT still plays an indispensable role in its treatment.

## References


1. Pieroni et al. JACC 2021 review.
2. Augusto JB, et al. EHJ-Cardiovascular Imaging. (2020)0,1-10.

# Fabry Disease Case Book

## Case 12:

A patient of Fabry disease with atrial fibrillation and recurrent stroke

黃群耀醫師

## *Clinical pearls*

- In Taiwan, a certain proportion of patients with cardiac-variant Fabry disease have accompanying incidences of AF and stroke.
- The underlying causes of AF and stroke in patients with Fabry disease remain unclear and may be complex.
- ERT remains the pivotal treatment for Fabry disease; however, further studies are needed to determine detailed strategies including screening, monitoring and treatment for stroke prevention in Fabry disease with AF.
- Comprehensive communication with the patients' families and maintaining patients' compliance with ERT are keys to successful treatment.

## *Patient profile*

### Case presentation

- A 68-year-old male patient experienced two consecutive stroke episodes on April 30 and May 19, 2016. The patient was treated at another hospital. Rivaroxaban 15 mg qd was prescribed for stroke prevention, and HCM was diagnosed.
- Because this patient's younger brother was diagnosed with Fabry disease at Taipei Medical University Hospital, he was later transferred for screening of Fabry HCM. The diagnosis was confirmed as Fabry disease in May 2016.
- ERT was initiated from December 2016.
- In spite of regular follow-up and medication, the patient experienced a third stroke episode in April 2020. Further evaluation was performed to investigate the underlying cause of recurrent stroke other than Fabry disease; however, no autoimmune or coagulation disorders were found.
- Intra-arterial thrombectomy was performed on time, with near-complete recovery of neurological function. In May 2020, after thrombectomy, LAA occlusion was performed using an Amplatzer LAA occluder.
- Considering that this patient had Fabry disease combined with a repeat stroke history, even with a NOAC, we continued rivaroxaban 15 mg/day treatment after LAA occlusion.
- Unfortunately, the fourth stroke episode occurred with multiple embolizations over his bilateral brain hemispheres in April 2022, resulting in a disability. Rivaroxaban 15 mg/day was changed to edoxaban 60 mg/day after the stroke.

- The patient is currently receiving regular ERT and edoxaban for the treatment of Fabry disease and stroke prevention.

## Past history and personal history

- Arrhythmias, documented in medical records from other hospital (type not specified.
- No history of diabetes mellitus or hypertension.
- Alcohol consumption and smoking history, both were quit in 2016.

## *Laboratory panels*

### Figure 1.

| Systemic | α-GAL enzyme activity (nmol/hr/ml) | Plasma Lyso-Gb3 | GLA mutation |
|---|---|---|---|
| Reference | 2.05- 7.46 | <0.8 | Classic/ Cardiac/ Renal |
| 2016 | **0.46 nmol/hr/ml** | NA | **c.639+919 G>A** Cardiac variant |

| Systemic | NT-proBNP |
|---|---|
| 2016 | **2062** |

- Cardiac variant Fabry disease was diagnosed based on low enzyme activity and IVS4 mutation.

### Figure 2.

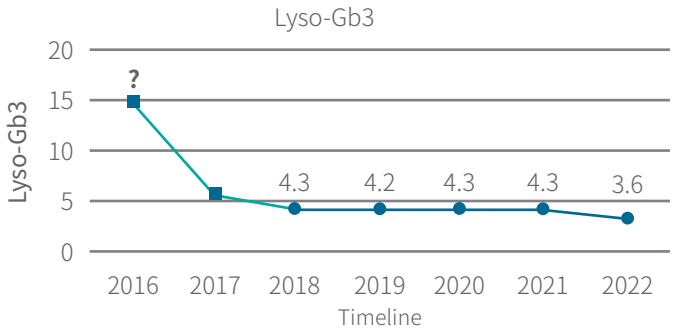


- Although this patient's data of 2016-17 was missing, there is still a trend of lyso-Gb3 level decrease after ERT.

## Figure 3-4.

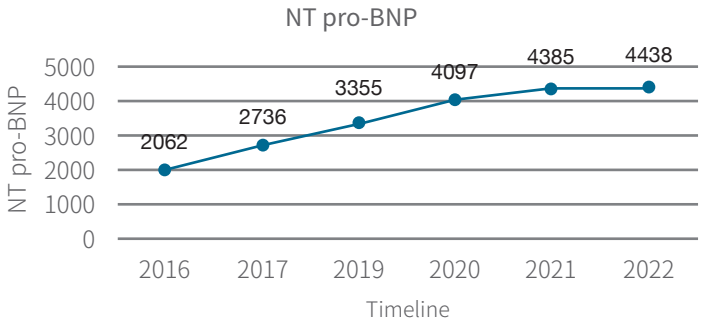


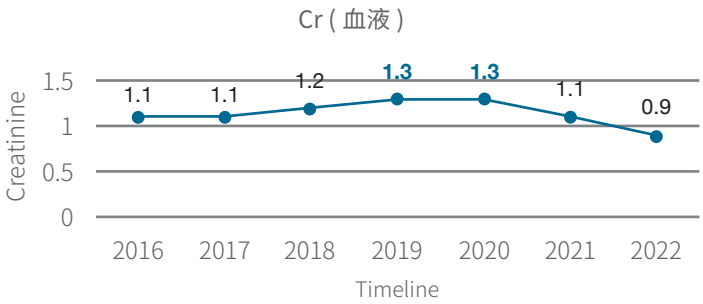


- This patient's NT-proBNP has been continuously increasing regardless of ERT, but creatinine level was gradually decreased.

## *Chest radiograph*

Figure 5.

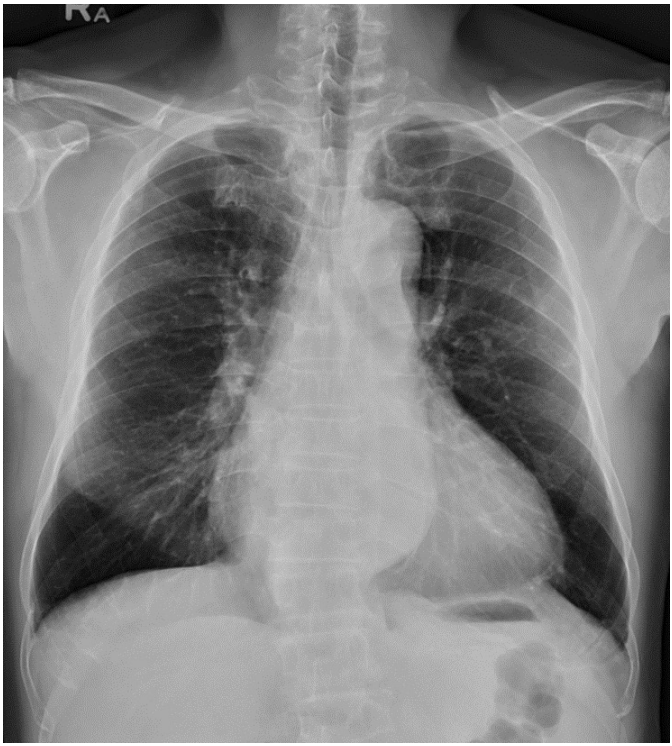

- Chest radiograph in 2016 revealed cardiomegaly.

## *Electrocardiography*

### Figure 6.

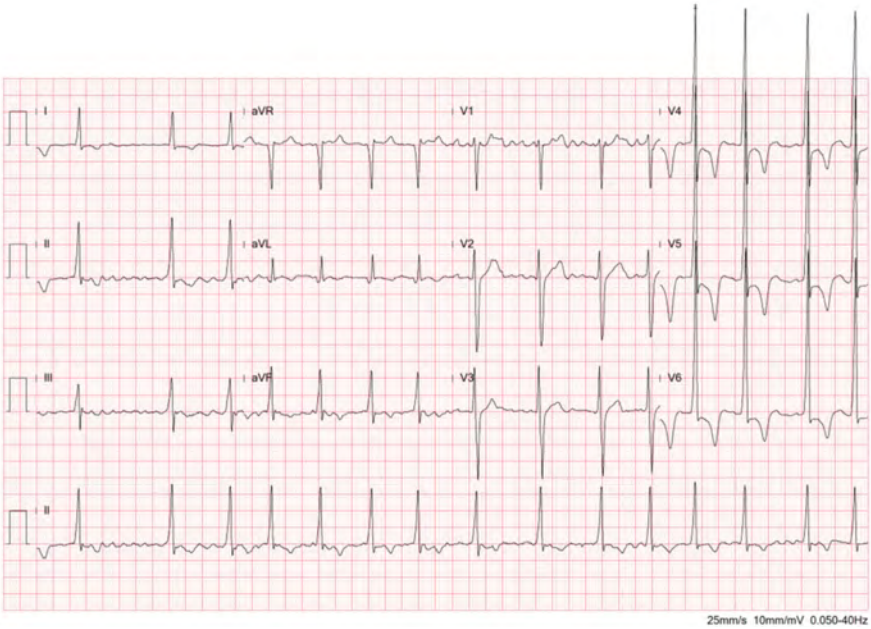


EKG in 2016

- LVH with inverted T wave, strain pattern
- Af

## Figure 7.

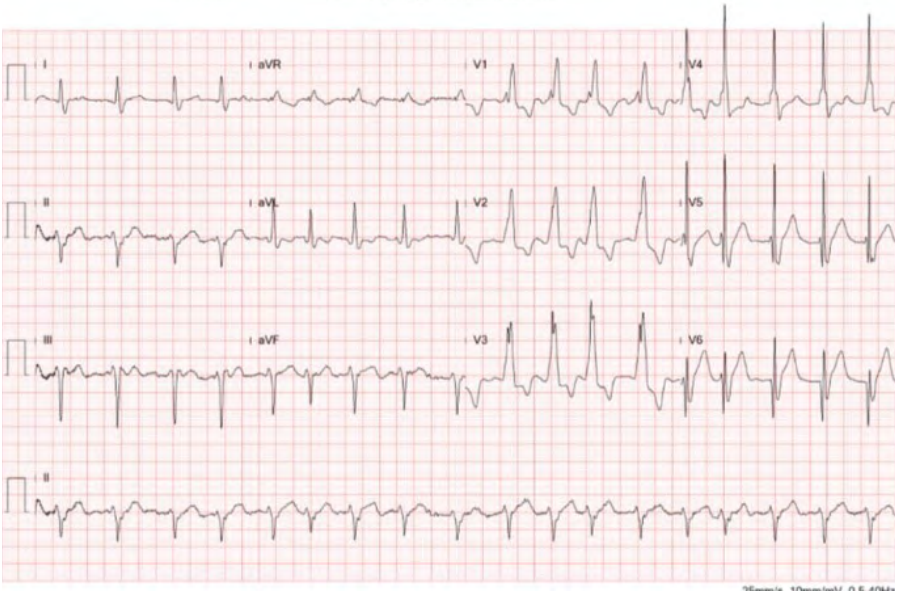


EKG in 2022

- Compared to EKG in 2016, new RBBB was seen.
- Slightly lower voltage was also noted, probably resulted from myocardial injury or pericardial effusion.

## *24-hour Holter*

### Figure 8-9.

- 24-hour Holter in 2016 showed Af, LVH with strain, frequent RVR; the longest pause was 1.8 seconds.

## *Brain magnetic resonance imaging*

Figure 10-13.

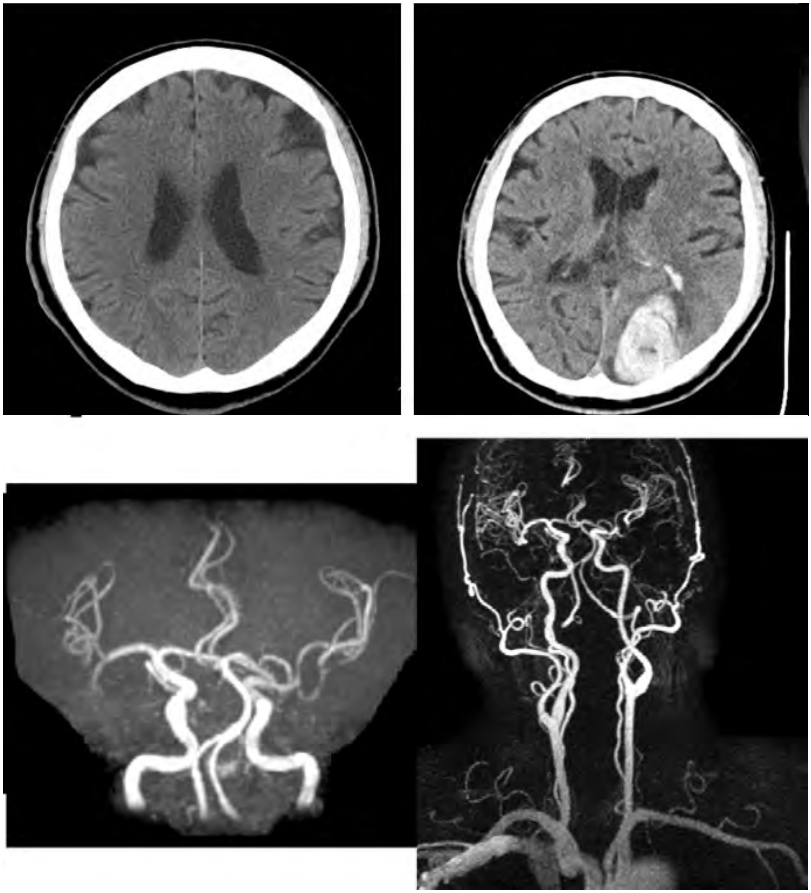

- Embolic stroke with Posterior occipital hemorrhage
- No significant atherosclerosis of intracranial vessels

Figure 14-15.

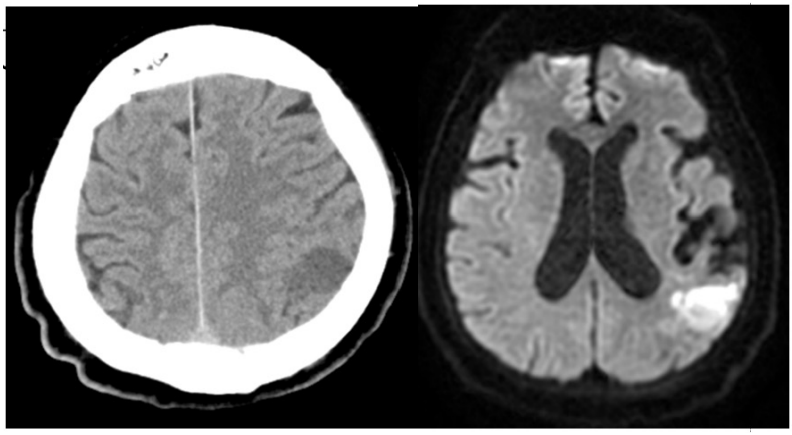

- Brain MRI after this patient's third stroke in 2020 showed embolic stroke and hemorrhage in posterior occipital region.

Figure 16-21.

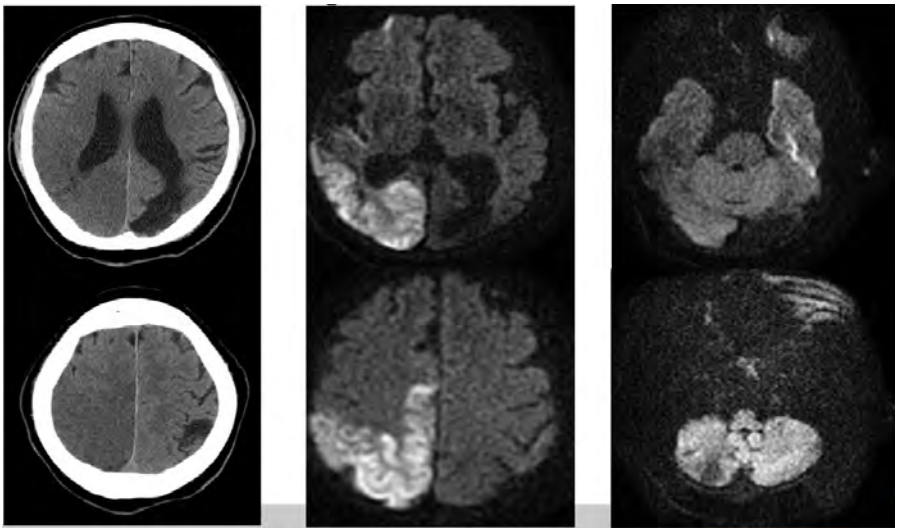

- Brain MRI after this patient's fourth stroke in 2022 showed large ischemic change over cerebellum, right occipital, frontal and left temporal area.

## *Echocardiography*

### Figure 22-23.

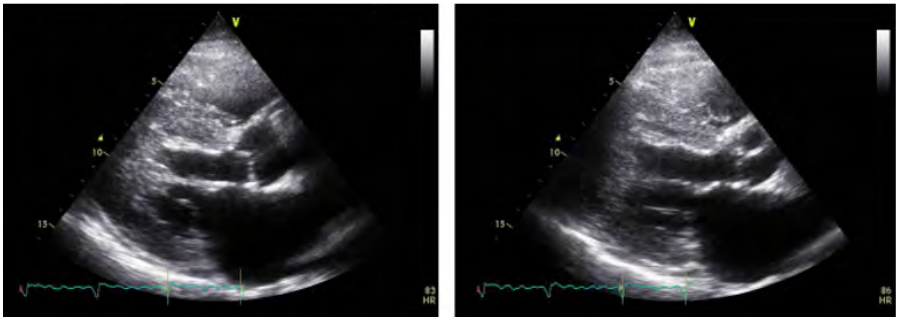

- Cardiac echography in 2016 showed concentric LVH, atrial enlargement and mild pericardial effusion.

### Figure 24-25.

| | | 2016 | 2017 | 2020 | 2021 | 2022 |
|---|---|---|---|---|---|---|
| **IVSd, mm** | 7-10 | **20.34** | **22.40** | **22.90** | **24.41** | **23.03** |
| **LVIDd, mm** | 35-53 | 26.55 | 41.84 | 39.76 | 37.38 | 37.23 |
| **LVPWd, mm** | 8 | **29.25** | **23.40** | **19.01** | **19.59** | **20.47** |
| **LVIDs, mm** | 13 | 24.27 | 26.24 | 22.47 | 18.09 | 20.34 |
| **LV mass, gm** | | 352.25 | 519.33 | | 405.62 | |

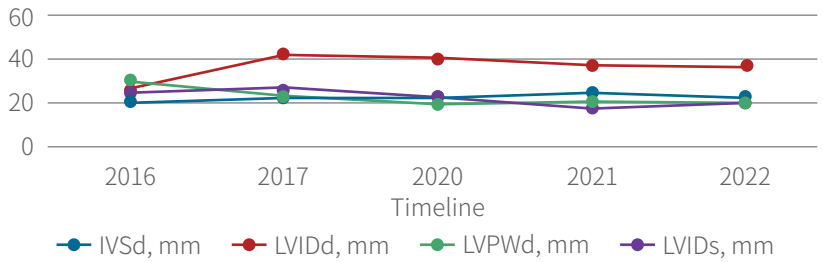


- During the treatment, although this patient's NT-proBNP level continuously increased, his left ventricular volume did not enlarge significantly from 2016 to 2022. However, interobserver bias arising from different cardiac echography performers should be taken into consideration.

## *Cardiac magnetic resonance imaging*

Figure 26-27.

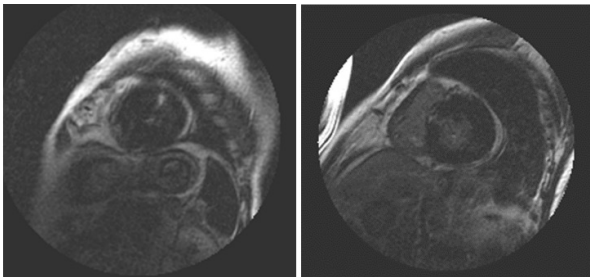

- Cardiac MRI in 2016 (T1 mapping sequence and extracellular volume are unavailable)
- Diffuse thickening myocardium of left ventricle
- Patch late gadolinium enhancement at basal septum (AHA segment 2 & 3) and anterior wall (AHA segment 7) of mid LV cavity.

## *Six-minute walk test*

Figure 28.

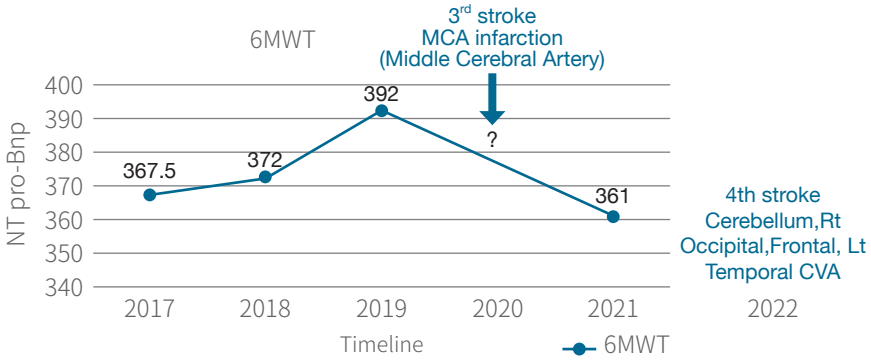


- This patient’s 6MWT once improved after ERT, but significantly deteriorated after the third stroke episode.

## *Pedigree*

Figure 29.

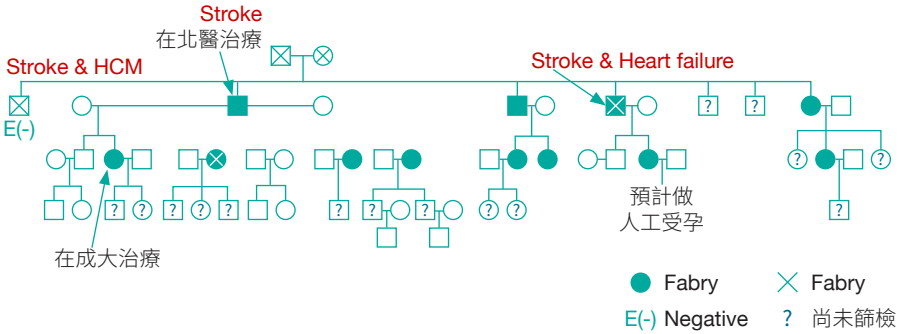


- This patient's two brothers had stroke history, but one was not detected with IVS4 mutation.
- One of this patient's daughter is positive for IVS4 mutation; however, she is also a patient of systemic lupus erythematosus under chloroquine use, which may interfere with the diagnosis of Fabry disease.
- Due to the patient's poor family relationship, more time and effort are needed for complete family screening.

## *Discussion*

- In Taiwan, the prevalence of AF is 1%, and the risk of stroke in patients with AF is five times higher than that in those without AF. Based on several studies, the prevalence of AF among patients with Fabry disease is between 3% and 13.3%, and is higher in men.
- Fabry disease not only affects the left ventricular function but also diastolic function of the left atrium. Some studies have investigated whether left atrial function measurements are indicators of Fabry disease progression.
- Because this was a patient with AF, the general EKG criteria for diagnosing Fabry disease, such as a short PQ interval, high QRS voltages, and AV blocks, may not have been prominent.
- According to European and American guidelines, LAA occlusion should be considered for stroke prevention in patients with AF and those contraindicated for long-term anticoagulant treatment or in patients with recurrent stroke despite anticoagulant treatment use. The class of recommendation for LAAO was IIb.

- Several ongoing trials have compared LAA occlusion with oral anticoagulation therapy, one of which has demonstrated non-inferiority in the efficacy and safety of LAA occlusion to oral anticoagulation. However, this trial was not conducted in patients with Fabry disease, and further information is required to determine the most appropriate treatment option for these patients.
- Although LAA occlusion can significantly reduce the incidence of stroke, a small group of patients still experience recurrent stroke within one year of the procedure. In this patient, we cannot conclude that Fabry disease was the only or major factor responsible for recurrent stroke because both his brothers had a history of stroke, but only one of them was positive for the Fabry disease mutation. ERT seemed effective in reducing this patient' s lyso-Gb3 level but had no significant effect on the heart failure progression and stroke prevention.
- In patients with Fabry disease and AF, many antiarrhythmic drugs, including amiodarone, dronedarone, sotalol, flecainide, and propafenone, are contraindicated or avoided because of their potential to induce lysosomal dysfunction or drug interactions with ERT. ACEIs/ARBs, beta-blockers, loop diuretics, and CCBs are recommended for the supportive treatment of cardiac manifestations of Fabry disease.
- There is no specific recommendation for anticoagulant therapy in patients with Fabry disease and AF; however, according to reports of cerebral microbleeds in Fabry disease, NOACs may have a potential advantage over warfarin, as they are associated with reduced risks of intracranial bleeding. For patients unable to use anticoagulants, LAA closure may be considered an alternative treatment.

## *References*


1. Freedman B, et al. Circulation. 2017 May 9;135(19):1851-1867.
2. Azevedo O, Cordeiro F, et al. Int J Mol Sci. 2021 Apr 23;22(9):4434.
3. Lee HJ, et al. AJNR Am J Neuroradiol. 2016 Jun;37(6):1044-9.
4. Pichette M, et al. J Am Soc Echocardiogr. 2017 Feb;30(2):170-179.e2.
5. J Am Coll Cardiol 2021;77:922-36.
6. https://doi.org/10.1016/j.jscai.2022.100577.
7. DOI: 10.33963/KP.a2022.0047
8. European Journal of Heart Failure (2020) 22, 1076-1096.
9. Int. J. Mol. Sci. 2021, 22, 4434. https://doi.org/10.3390/ijms22094434.

# Fabry Disease Case Book

## Case 13:

A patient of cardiac variant Fabry disease with complete AV block

王朝永醫師

## *Clinical pearls*

- When a stroke event occurs, patients with IVS4 (cardiac variant) Fabry disease may exhibit brain MRI findings similar to those observed in patients with classic Fabry disease.
- Prompt treatment for Fabry disease is important.
- There are two available ERT medications with different infusion times, and this dissimilarity may influence patient compliance.
- In addition to LVH, conduction dysfunction is not uncommon in cardiac variant Fabry disease, and its prevalence is higher in male patients.

## *Patient profile*

### Case presentation

- The patient was a 50-year-old male with a history of brain stem (right pons) stroke in 2002 and has been regularly followed up in the neurology clinic at our hospital.
- In 2017, the patient was enrolled in a young stroke study and subsequently diagnosed with cardiac variant Fabry disease.
- ERT with agalsidase beta was initiated in the same year as the diagnosis, but the patient' s compliance was inadequate owing to the extended infusion time and lack of cardiac symptoms.
- In 2018, a cardiac biopsy was recommended to continue ERT reimbursement; however, the patient refused and discontinued ERT.
- Between 2018 and 2022, the patient periodically attended follow-up visits at cardiology and neurology clinics but continued to refuse biopsy.
- In 2022, the patient was admitted to the emergency department, where an AV block was identified. Following this event, the patient agreed to undergo biopsy and ERT.
- A pacemaker was implanted owing to complete AV block.
- ERT was scheduled for 2022, and agalsidase alpha was selected considering its shorter infusion time.
- The current treatment plan entails regular visits once every other week for ERT sessions, hematological and biochemical tests every three months, and annual cardiac imaging examinations for efficacy evaluation.

## Medical history

- Diabetes mellitus
- Hyperlipidemia
- Hyperuricemia with acute gouty arthritis attack
- Chronic hepatitis B

## Family history

The patient' s mother experienced a stroke (hemisphere intracranial hemorrhage) at the age of 54 years.

## *Laboratory panels*

### Figure 1.

| Systemic | a-GAL enzyme activity | Plasma Lyso-Gb3 | GLA mutation |
|---|---|---|---|
| Reference | N <10 X | <0.8 ng/mL | Classic/ Cardiac/ Renal |
| 2017 | 10.68 | NA | **c.639+919 G>A (Cardiac)** |
| Reference | 13-17 g/dL | **<2.6 ng/mL** | |
| 2023(Jan.) | NA | 2.7 | |

- In 2017, the patient was diagnosed with cardiac variant Fabry disease based on lower enzyme activity and a positive IVS4 mutation.

## *Electrocardiography*

### Figure 2-3.

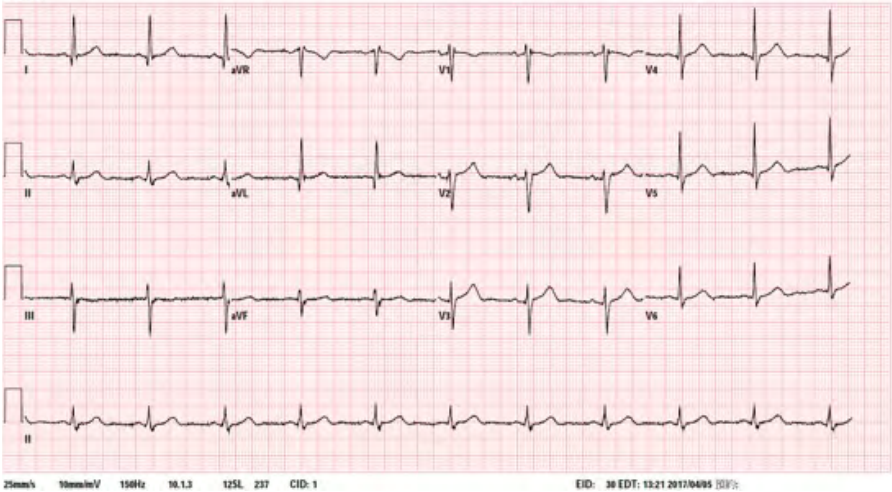


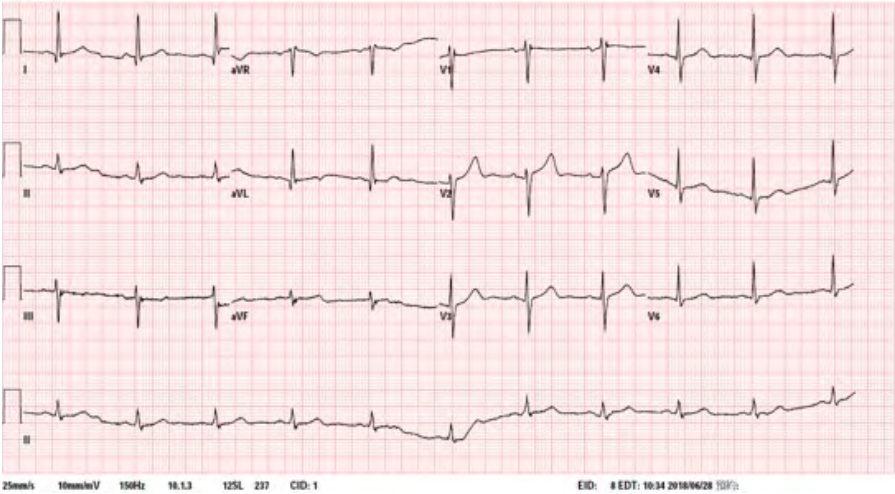


- EKGs in 2017 and 2018 showed incomplete RBBB.

## Figure 4.

- EKG in 2019 found progressive RBBB.

## Figure 5.

- EKG in 2020 revealed RBBB and nonspecific ST-T changes.

## Figure 6.

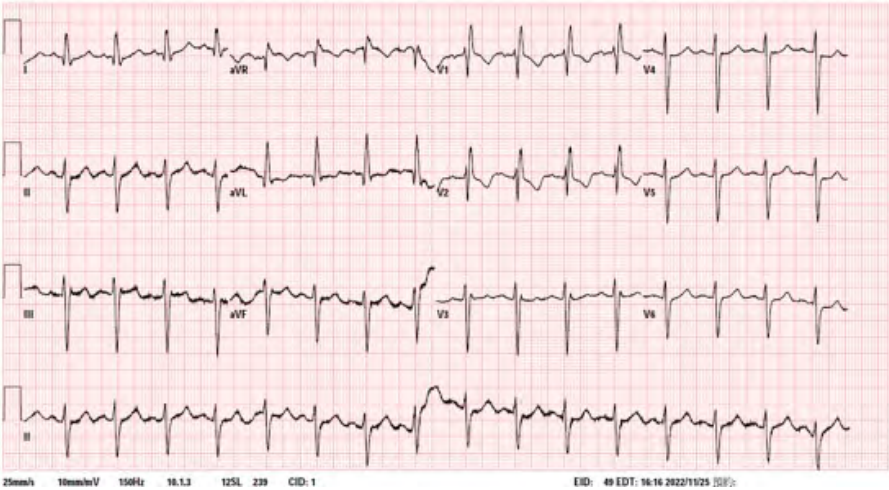


- EKG in 2021 showed RBBB and left anterior fascicular block (bifascicular block).

## Figure 7.

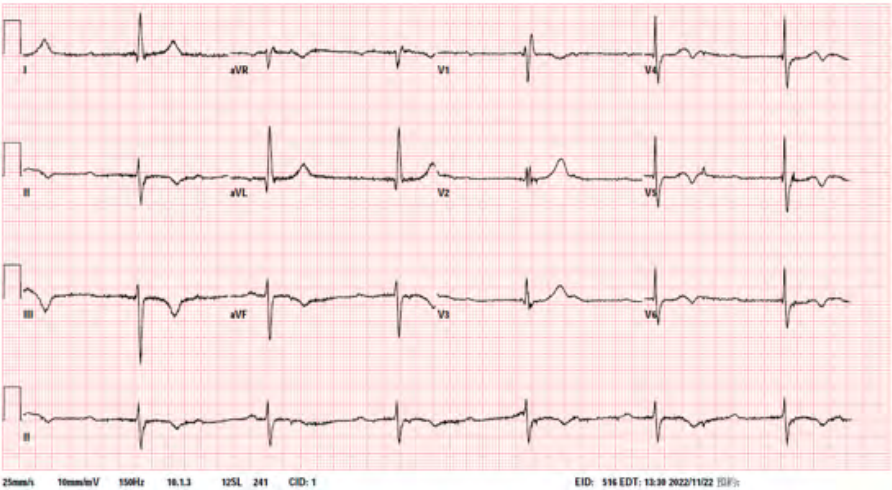


- EKG performed in emergency department (in 2022) showed high degree AV block, complete RBBB with junctional bradycardia.

## *Brain magnetic resonance imaging*

Figure 8-13.

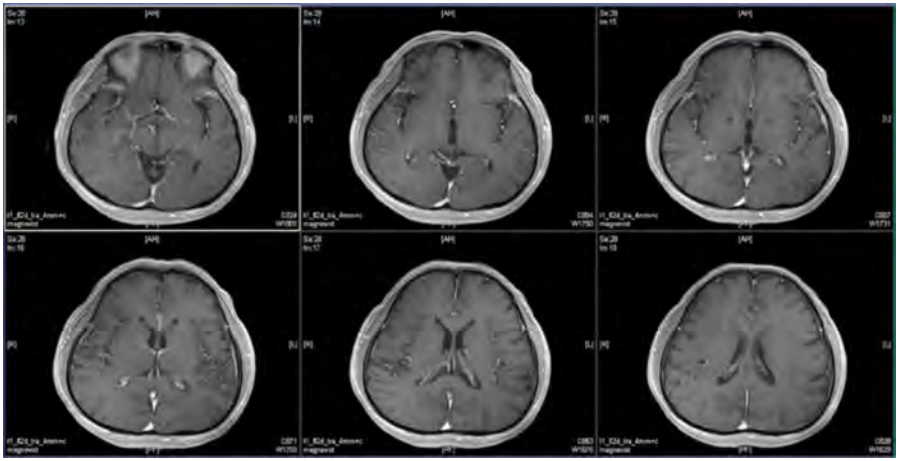

Brain MRI in 2022.

- Atherosclerotic tandem severe stenosis at the right high neck and cranial internal carotid artery.
- Possible congenital hypoplasia of the left neck and cranial vertebral artery.
- No brain lesion suggestive of Fabry disease.

## *Cardiac echography*

Figure 14.

| Systemic | IVSd, mm | LVEDd, mm | LVPWd, mm | LV mass, gm | EF, % |
|---|---|---|---|---|---|
| Reference | 7-10 | 35-53 | 8-13 | | 50%-80% |
| 2013 | 13 | 48 | 11-14 | 213 | 78% |
| 2017 | 14 | 51 | 13 | 286 | 80% |
| 2018 | 15 | 47 | 12 | 251 | 71% |
| 2019 | 14 | 49 | 11 | 240 | 82% |
| 2020 | 15 | 43 | 13 | - | 67% |

- Mild ventricular wall thickening
- No significant change observed in left ventricular volume after the initiation of ERT in 2017.

Figure 15-24.

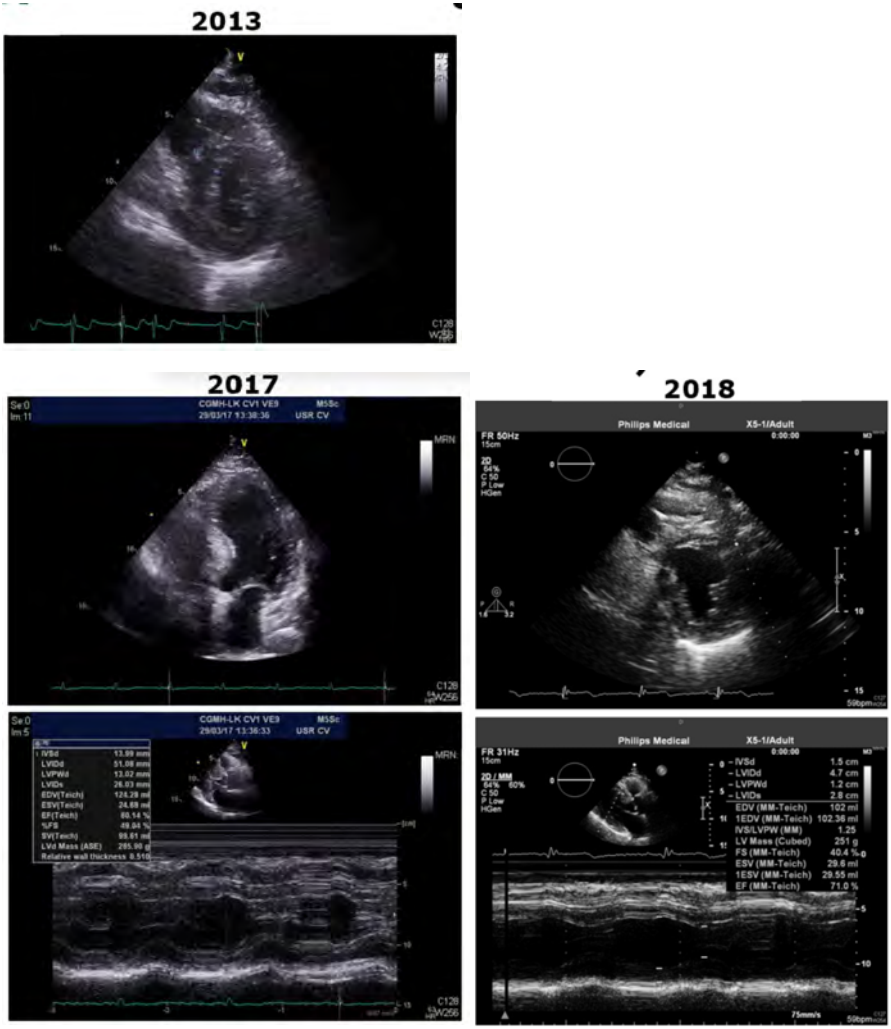
2013
2017
2018
Philips Medical
X5-1/Adult
FR 50Hz
FR 31Hz
IVSd 1.5 cm
LVIDd 4.7 cm
LVPWd 1.2 cm
LVIDs 2.8 cm
EDV (MM-Teich) 102 ml
1EDV (MM-Teich) 102.36 ml
IVS/LVPW (MM) 1.25
LV Mass (Cubed) 251 g
FS (MM-Teich) 40.4 %
ESV (MM-Teich) 29.6 ml
1ESV (MM-Teich) 29.55 ml
EF (MM-Teich) 71.0 %
75mm/s

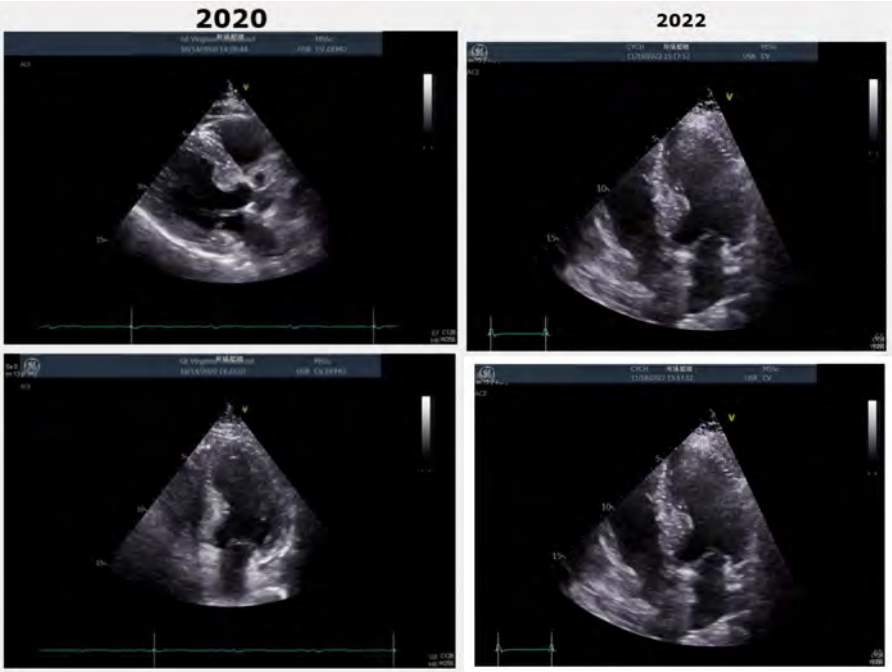


| Systemic | IVSd, mm | LVEDd, mm | LVPWd, mm | LV mass, gm | LVMi, g/m$^2$ | EF, % |
|---|---|---|---|---|---|---|
| **Reference** | 7-10 | 35-53 | 8-13 | | <125 (Male) | 50%-80% |
| **2023 (Jan.)** | | 44 | 6 | **144** | | **79%** |

- Cardiac echography from 2017 to 2022 showed mild LVH, more prominent in septal wall.

## *Cardiac magnetic resonance imaging*

Figure 25.

Cardiac MRI in 2023 (T1 mapping sequence is not available)

- Diffuse hypertrophic changes in both left and right ventricular walls.
- Ill-defined LGE present in the lateral wall of the left ventricle, primarily in the interventricular septum.

## Cardiac biopsy

Electron microscopic findings:

- Expanded myocytes characterized by central vacuolization with remaining myofibrils at the periphery were observed.
- Notable aggregates or clusters of electron-dense laminated myelin-like bodies were present within the vacuolated myocytes.
- These are typical findings commonly associated with Fabry disease.

## Discussion

- Several studies have demonstrated that brain MRI findings in stroke patients with cardiac variant Fabry disease closely resemble those found in classic Fabry disease. However, solely relying on brain MRI images makes it challenging to definitively attribute the stroke to Fabry disease. As a result, in this patient, we could not conclusively determine whether the early stroke was a result of Fabry disease or other underlying diseases.
- Although cardiac variant Fabry disease is generally considered less likely to cause stroke, our hospital has documented cerebrovascular events in some patients with a confirmed diagnosis of this variant. Furthermore, many patients who experienced early-onset stroke events were incidentally found to be positive for Fabry disease. Currently, there is a lack of available data concerning the epidemiology of stroke events specifically linked to IVS4 Fabry disease. Consequently, it remains impossible to demonstrate whether this specific subtype of Fabry disease is associated with angiopathy. Further studies are needed to ascertain whether the IVS4 mutation warrants classification as "cardiac variant" or "cardiovascular variant" Fabry disease.
- The frequency of conduction disorders in cardiac variant Fabry disease differs depending on the type of disorder and patient sex. RBBB occurs in up to 38.8% of males, but only 8.5% of females; left anterior fascicular block is seen in 45.5% of males and 10.3% of females; bifasicular block presents in 25.3% of males and 5.7% of females; and complete AV block occurs in 12.7% of males and 1.6% of females. The mean age of diagnosis for male patients is 60 ± 7 years, consistent with the age of the patient in this case. However, the rationale underlying these sex-based difference remains unclear.
- A short PR interval on the EKG is an early clinical presentation of conduction disorders in Fabry disease. In the later stages of the disease, AV block, bundle branch blocks, and bifascicular block may manifest, potentially necessitating pacemaker placement in cases of common bradycardia at rest or chronotropic incompetence.

- The severity of LVH does not demonstrate a correlation with conduction disorders in patients with cardiac Fabry disease. Conversely, the presence of conduction disorders does not always indicate Fabry disease or require immediate intervention. For instance, in patients with bifascicular block, Fabry disease screening may not be necessary if no LVH is observed. Considering the general population, only 3%–5% of these patients would be expected to progress to complete AV block in long-term observation. Thus, no further investigation is required in the absence of syncope.

## *References*


1. Lee HJ, et al. Am J Neuroradiol. 2016;37(6):1044-9.
2. Lee HJ, et al. BMC Neurol. 2017;17:25.
3. Azevedo O, et al. Int J Mol Sci. 2021;22(9):4434.

# Fabry Disease Case Book

## Case 14:

A patient of cardiac variant Fabry disease with allergic reactions to ERT

黃偉春醫師

## *Clinical pearls*

- Clinicians should be aware of patients presenting with asymmetric hypertrophy and consider Fabry disease screening.
- Syncope can be a potential symptom of Fabry disease.
- ERT plays a crucial role in improving patient symptoms. However, allergic reactions can occur, and may impact patient compliance.
- In cases of allergy to agalsidase beta, premedication, shifting to agalsidase alpha, and desensitization may be considered as potential strategies.

## *Patient profile*

### Case presentation

- A 67-year-old male patient, with a history of hypertension and obesity (BMI 30.5 $kg/m^2$).
- In September 2019, the patient presented to our cardiology clinic because of uncontrollable dyspnea while walking for four years and occasional syncope of unknown etiology.
- Fabry screening was conducted, and in February 2020, the patient received a final diagnosis of Fabry disease with concentric nonobstructive LVH.
- ERT with agalsidase beta was initiated in May 2020. However, the patient experienced severe skin itching after ERT, despite the use of symptom relief medication. Consequently, ERT with agalsidase beta was discontinued in August 2020.
- In October 2020, ERT was re-initiated with agalsidase alfa. No allergic reactions have been reported since the medication change.
- The patient is currently classified as functional class I to II, undergoing regular follow-up.

### Family history

This patient's father had history of ischemic stroke.

## *Laboratory panels*

### Table 1.

| Item | WBC | RBC | HGB | HCT | MCV | MCH | MCHC | RDW | Platelet |
|---|---|---|---|---|---|---|---|---|---|
| Unit | K/uL | M/uL | g/dL | % | fl | pg | g/dL | % | K/uL |
| Data | 5.0 | 4.73 | 15.6 | 46.2 | 97.6 | 32.9 | 33.7 | 13.3 | 207 |
| **Item** | **BUN** | **CREA** | **Na** | **K** | **UA** | **eGFR** | **IgG** | **IgA** | **IgM** |
| **Unit** | **mg/dL** | **mg/dL** | **mmol/L** | **mmol/L** | **mg/dL** | **ml/min/1.73** | **mg/dL** | **mg/dL** | **mg/dL** |
| Data | 19 | 1.41 | 143 | 4.6 | 7.3 | 53.13 | 1520 | 249 | 39.6 |
| **Item** | **A/G** | **ALB** | **Alpha-1** | **Alpha-2** | **Beta** | **Gamma** | **β2-M.G.** | **BNP** | |
| **Unit** | | **%** | **%** | **%** | **%** | **%** | **ug/L** | **pg/mL** | |
| Data | 0.8 | 45.3 | 2.3 | 13.4 | 12.7 | 26.2 | 2305 | 68.4 | |

- An autoimmune related disorder was excluded.
- The BNP level was within the normal range.

### Table 2.

| Systemic: | Reference | Date 1 (baseline) |
|---|---|---|
| Hb | 12-17 g/dL | |
| DBS Lyso-Gb3 | <0.31 ng/mL | |
| GAL-a enzyme activity | >15.3 μmol/L/h | |
| GLA mutation | -- | **GLA: c.640-801G>A** |

Fabry disease was diagnosed based on the high lyso-Gb3 level and GLA mutation.

## *Electrocardiography*

### Figure 1.

EKG in September 2019 showing LVH strain pattern.

## *Cardiac echography*

Figure 2.

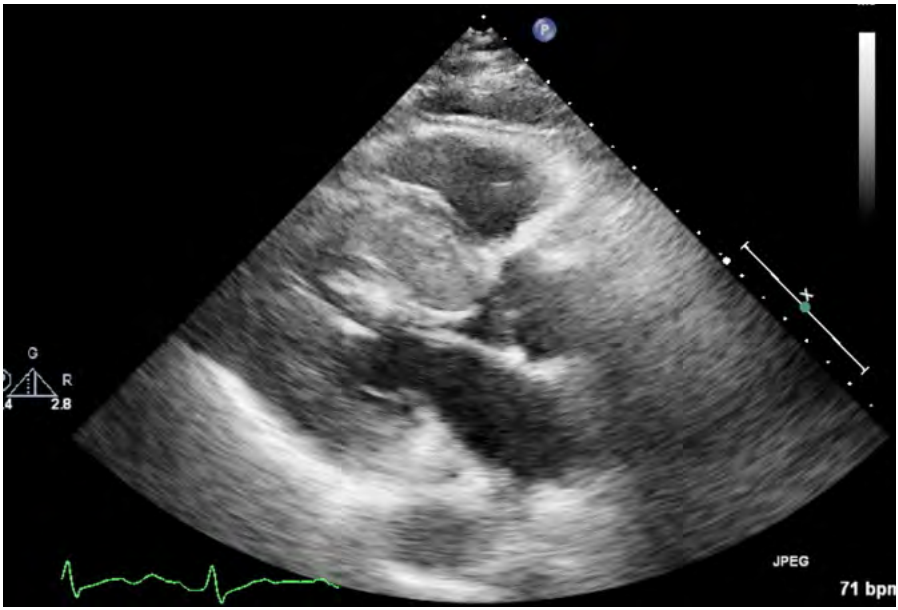


Cardiac echography in September 2019 demonstrates significant interventricular septum thickening (approximately 4 cm).

## *Cardiac magnetic resonance imaging*

Figure 3-7.

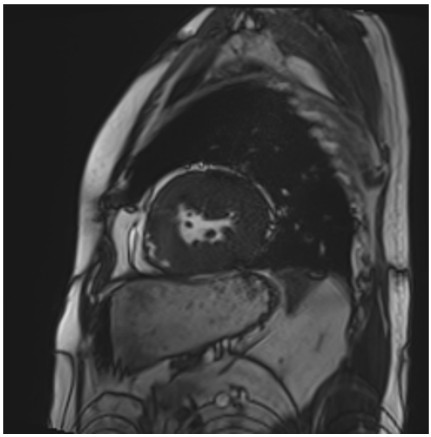

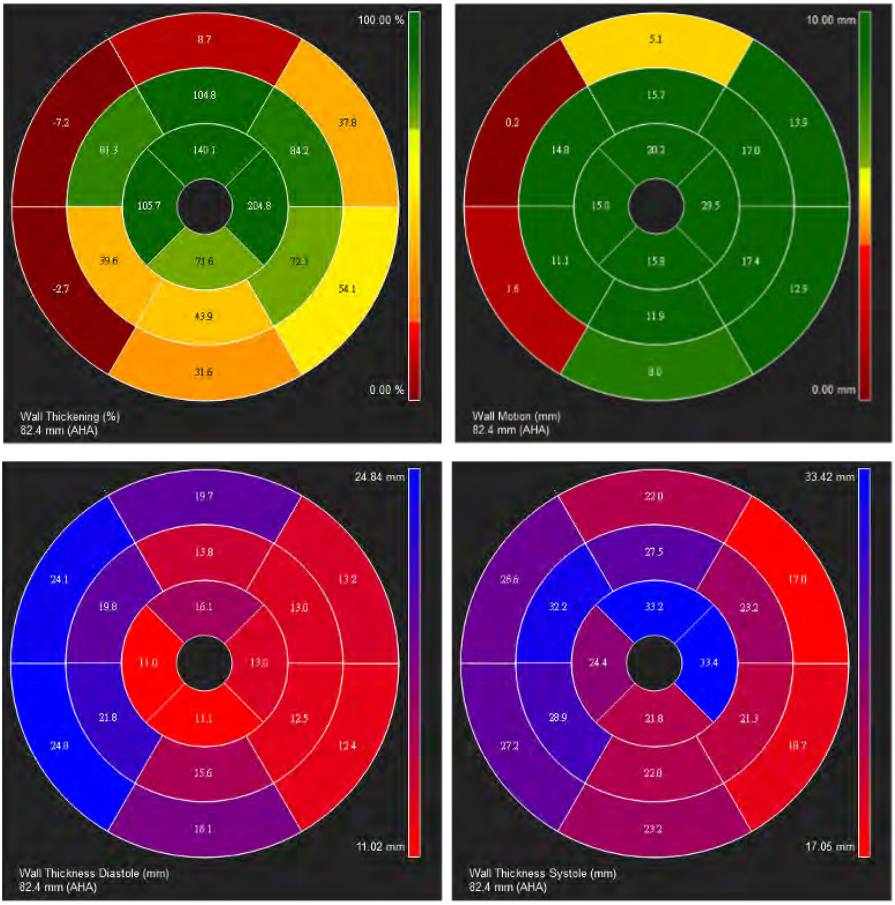


Cardiac MRI in October 2019

- Asymmetrical hypertrophy with a septal thickness of 38 mm.
- Prominent papillary muscles with low T1 and LGE.
- Several areas exhibited low T1 values (approximately 1130 ms), consistent with Fabry Gb3 deposits.
- Multifocal LGE was evident in the middle layer of the myocardium, indicative of fibrosis.
- An area with a high T2 value (50 ms), suggestive of inflammation.

## *Cardiac biopsy*

Figure 8.

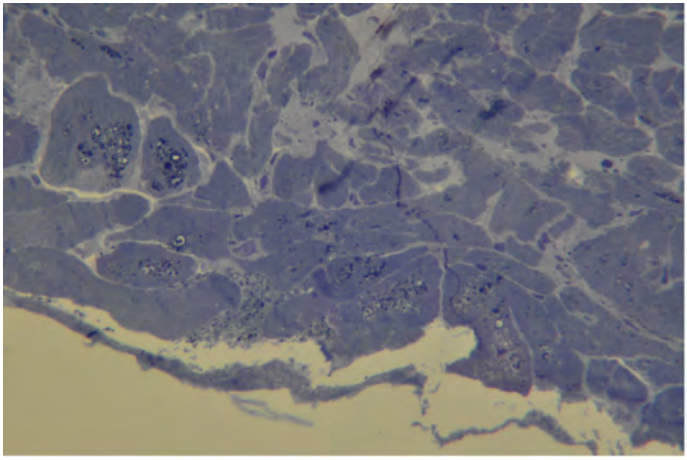

Toluidine blue-stained section of the myocardium showing accumulation of osmophilic material within the myocyte cytoplasm.

Figure 9.

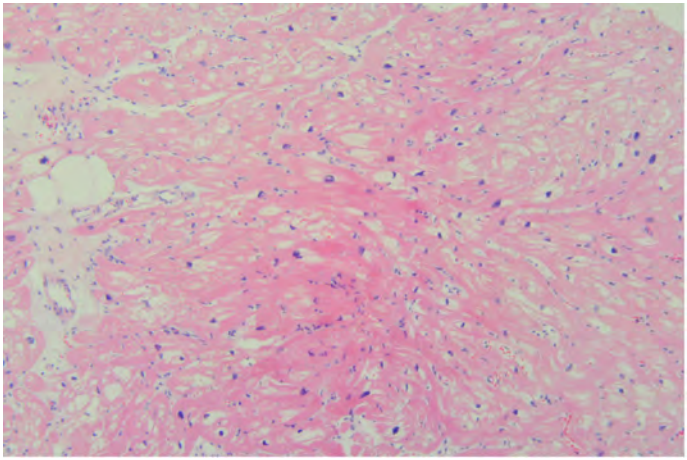

H&E-stained section of the myocardium indicating enlarged, hypertrophic myocytes with extensive vacuolar change in the cytoplasm.

Figure 10.

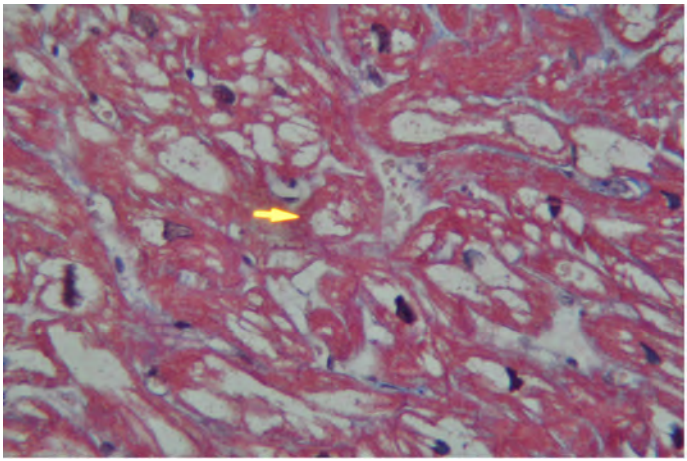

Trichrome stain of the myocardium highlighting the loss of myofibrils (arrow).

Figure 11.

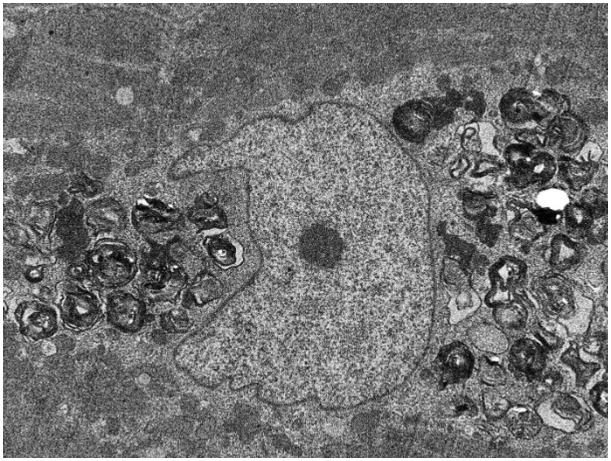

Electron microscopy of the myocardial tissue revealed many concentric lamellar bodies.

## *Pedigree*

Figure 12.

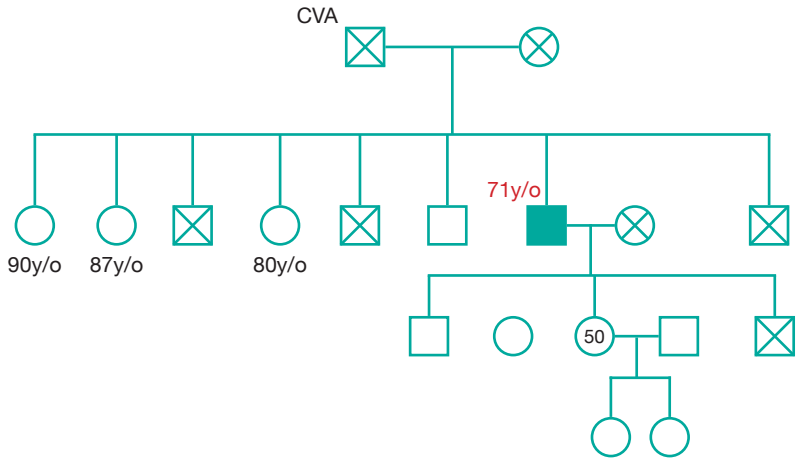


Family screening was not conducted due to the patient’s poor relationship with their family.

## *Physical examination (skin)*

Figure 13.

Allergic reaction on the trunk after ERT with agalsidase beta. ERT was subsequently discontinued.

Figure 14.

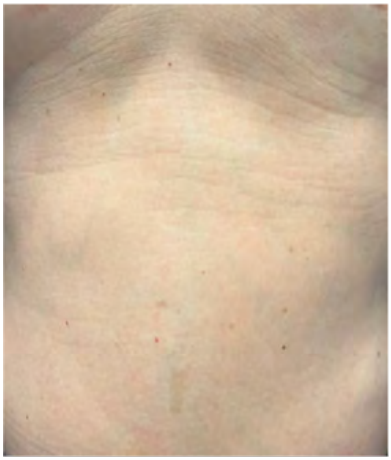

ERT was re-initiated with agalsidase alfa. No allergic reaction has been reported since the medication shift.

## *Discussion*

- The Fabry Outcome Study registry reported that the incidence of reactions to agalsidase alfa is 13% in all patients, with 17% of males and 6% of females experiencing reactions. Although ERT infusion reactions typically occur in male Fabry disease patients with a null mutation and specific IgG antibodies, the underlying pathogenesis remains unknown. Differences in absolute protein infusion doses may account for the varying rates of antibody formation between agalsidase alpha and beta.
- ERT-induced allergic reactions can occur at various time points. In some instances, reactions soon after treatment initiation can be effectively managed through premedication strategies, such as paracetamol, antihistamines, and corticosteroids, or by slowing the infusion rate. Most reactions tend to dissipate after subsequent infusions. Only 6% of patients experience severe reactions, and ERT discontinuation due to infusion reactions is rare.
- IgE is typically undetectable in patients experiencing ERT-related reactions, while IgG antibodies generally develop at approximately 3 months. After 12–18 months of therapy, approximately 83% of patients receiving agalsidase alfa no longer exhibit of IgG antibodies, and 30% of antibody-positive patients may develop immunological tolerance.

- Both agalsidase alpha and beta can induce allergic reactions. One case report described a successful desensitization procedure using skin prick tests and intradermal tests with agalsidase alfa (1:100 and 1:10 dilutions to undiluted solutions).
- Allergic reactions can significantly impact patients' treatment compliance. In this patient, despite the administration of symptom relief medications, he declined agalsidase beta three months after treatment. While no infusion reactions were reported after the medication shift, it remains uncertain whether it was due to agalsidase alfa or simply a consequence of the drug interruption period.
- In certain cases, infusion reactions to ERT may be severe. Another case report described a patient who received agalsidase alfa for over three years. Initially, his infusion reactions were mild and could be easily managed, but progressed regardless of very slow infusion rate and extended use of prophylactic medications. The patient experienced facial edema, flushing, throat tightness, headache, and joint pain 4-36 hours after most infusions; subcutaneous adrenaline treatment was required, and the patient was monitored in the intensive care unit for several days. Switching agalsidase alfa to beta did not mitigate the reactions, leading to ERT cessation at the five-year mark. Despite this, due to worsening clinical symptoms related to Fabry disease, the patient underwent tracheostomy to facilitate ERT administration. Two years later, the patient's clinical condition improved with regular agalsidase beta, administered at an attenuated dose and slow infusion rate.
- Syncope in Fabry disease may arise from dynamic LVOT obstruction or arrhythmia. In this patient, EKG and 24-hour Holter results did not reveal arrhythmias that could account for the syncope. Therefore, echocardiography should be considered to exclude LVOT obstruction as a potential cause.

## *References*


1. Aydin O, et al. J Investig Allergol Clin Immunol. 2013;23(5):367-8.
2. Nicholls K, et al. JIMD Rep. 2012;5:109-12.

# Fabry Disease Case Book

## Case 15:

A patient of cardiac variant Fabry disease with ventricular arrhythmias

林恆旭醫師

## *Clinical pearls*

- VT are not frequently observed in Fabry disease; however, they may lead to poor outcomes if they do occur.
- VT burden may decrease significantly under ERT.
- Patients with Fabry disease frequently experience Atrial fibrillation (Af); however, Af is not always a consequence of Fabry disease. Comprehensive investigation is needed to determine the specific factors that trigger Af in each case.
- Hyperthyroidism is a common side effect of amiodarone that can worsen preexisting arrhythmias.

## *Patient profile*

Case presentation

- A 55-year-old male with hypertension and paroxysmal Af taking valsartan 80 mg and amiodarone 200 mg per day.
- The patient had a cardiac arrest with VT/VF in November 2019 and completely recovered without sequelae after prompt cardiopulmonary resuscitation and implantation of ICD.
- HCM was diagnosed during admission and his medication was changed to valsartan 80 mg, bisoprolol 1.25 mg, and amiodarone 200 mg per day.
- The patient was transferred to our hospital in February 2021 because of recurrent VT/VF and frequent ICD shocks.
- He was diagnosed as Fabry disease with cardiac variant in March 2021, and ERT was initiated in October 2021.
- No additional VT/VF events or ICD shocks occurred since ERT was initiated. The patient's left ventricular mass and LVMI decreased slightly after the initiation of ERT.
- The patient visited our emergency department in September 2022 due to a symptomatic Af with RVR attack.
- His Af subsided after amiodarone infusion in the emergency department. A detailed examination revealed that the patient had hyperthyroidism, which was suspected to be amiodarone-induced thyrotoxicosis.
- Thus, amiodarone was discontinued and we increased bisoprolol dosage. Thereafter, the patient's thyroid function recovered and no additional Af or ventricular arrhythmia occurred thereafter.

## *Laboratory panels*

### Figure 1-3.

| Cardiac | Reference | 2021/03/21 | 2022/08/28 |
|---|---|---|---|
| Troponin T | <14.0 ng/L | N/A | 59.4 |
| NT pro-BNP | <125 pg/dL | N/A | 540 |

| Enzyme | | Lyso-Gb3 | | Gene |
|---|---|---|---|---|
| **2.1 µmol/L/h** | Rf: >15.3 µmol/L/h | **8.2 ng/ml** | Rf: <1.8 ng/ml | IVS4+919G>A |

| Others | |
|---|---|
| · Microalbuminuria | · 0.18 mg/dL |
| · A/C Ratio | · 2 mg/g |
| · eGFR | · *73* ml/min/1.732 |
| · SGOT | · *normal* |

- In March 2021, this patient was diagnosed with cardiac variant Fabry disease based on low enzyme level, high lyso-Gb3 concentration and IVS4 mutation.
- Baseline cardiac enzyme level was not available, and higher enzyme levels were still noted after ERT.
- No other organ involvement.

## Figure 4.

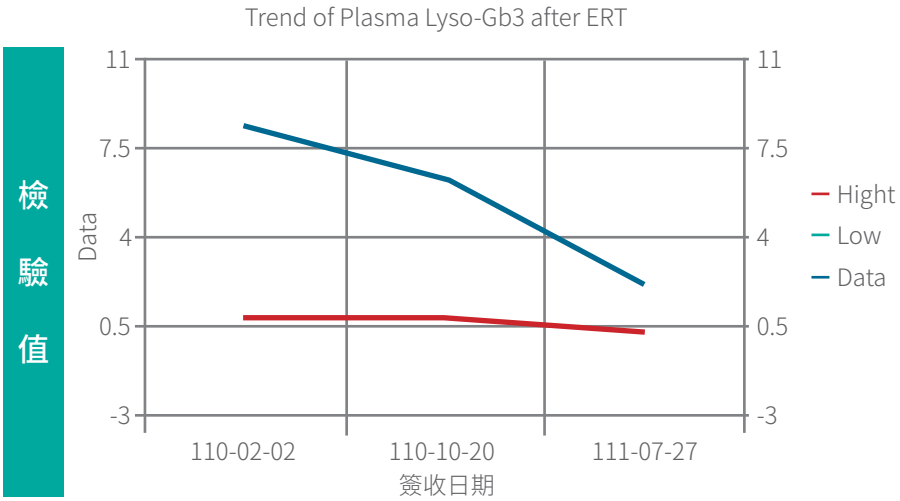


Plasma lyso-Gb3 level kept decreasing after ERT.

## Figure 5.

| Cardiac | Reference | 2022/10/12 | 2022/12/30 |
|---|---|---|---|
| TSH | 0.4~4 ulU/mL | **0.007** | 0.02 |
| Free T4 | 0.8~2 ng/dL | **3.67** | 1.49 |

The laboratory data revealed hyperthyroidism.

## *Electrocardiography*

### Figure 6.

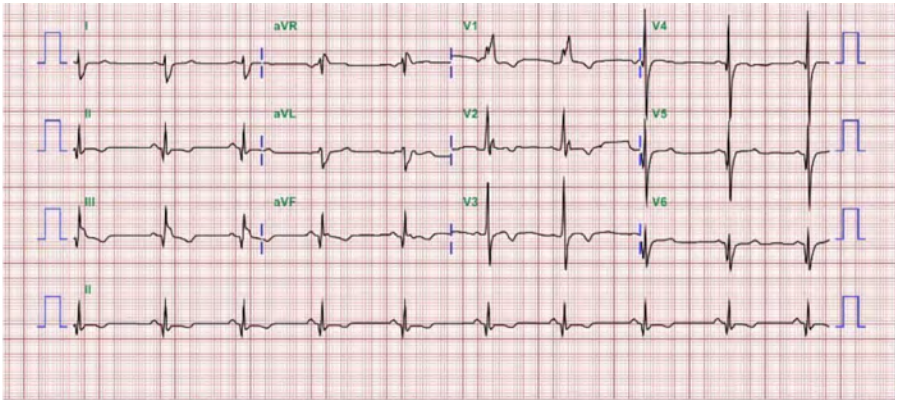


EKG in March 2021

- LVH
- RBBB
- Shortened PQ interval in V1, V4-V6
- Prominent pathological Q waves in lead II, III, aVF and V4-6

### Figure 7.

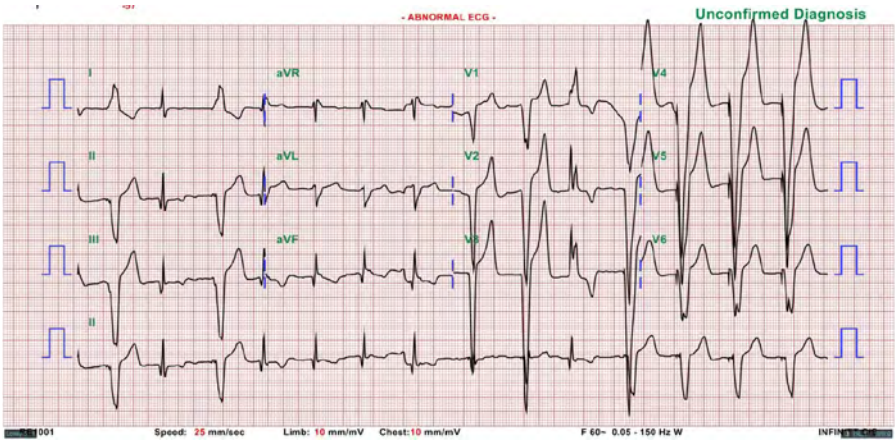


EKG in emergency department (September 2022) found Af attack.

## Figure 8.

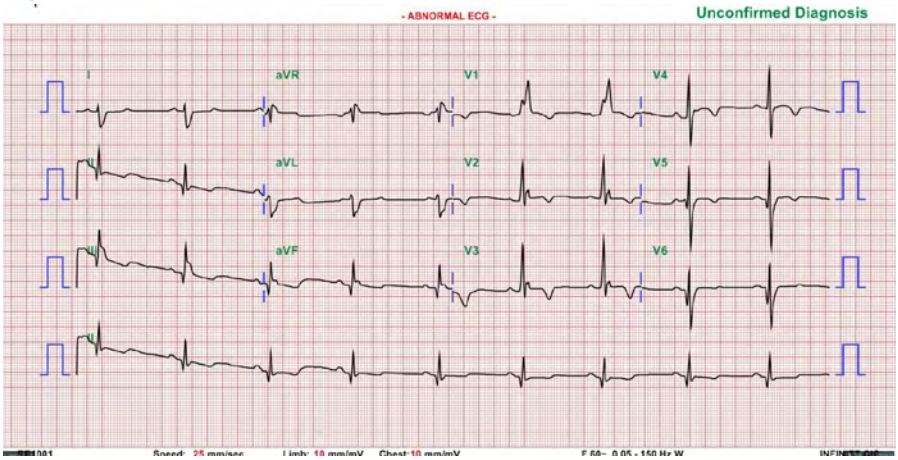


After amiodarone infusion (September 2022), this patient’s EKG morphology returned to baseline (2021).

## *Cardiac echography*

### Figure 9-11.

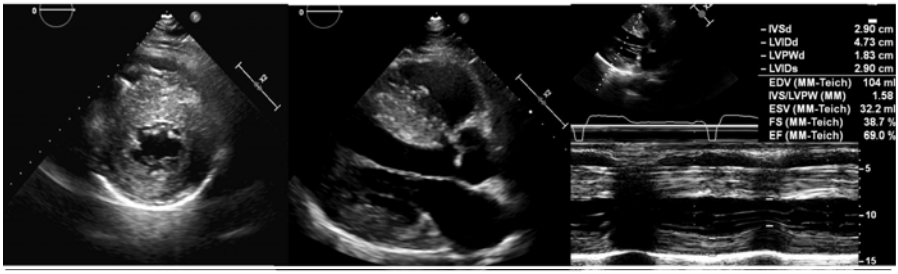


Cardiac echography in March 2021

- Significant left ventricular wall thickening
- Left ventricular mass: 608 g; LVMI: 298 g/m$^2$
- Normal LVEF, no LVOT obstruction

### Figure 12.

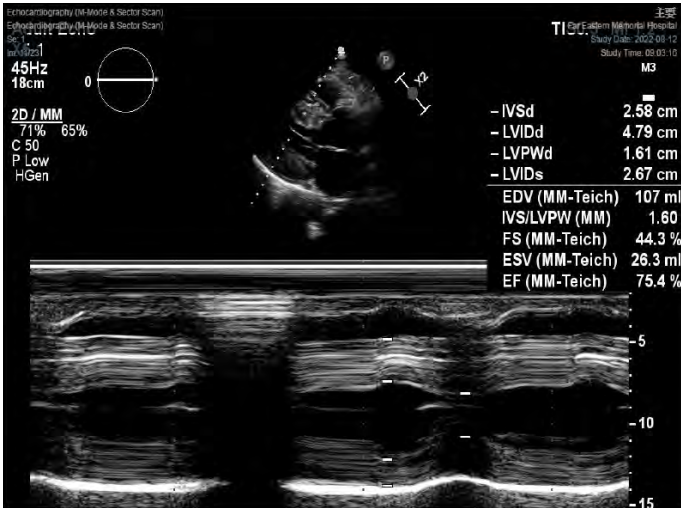


Cardiac echography in August 2022 revealed mild improvement on LVH.

## *24-hour Holter*

### Figure 13-15.

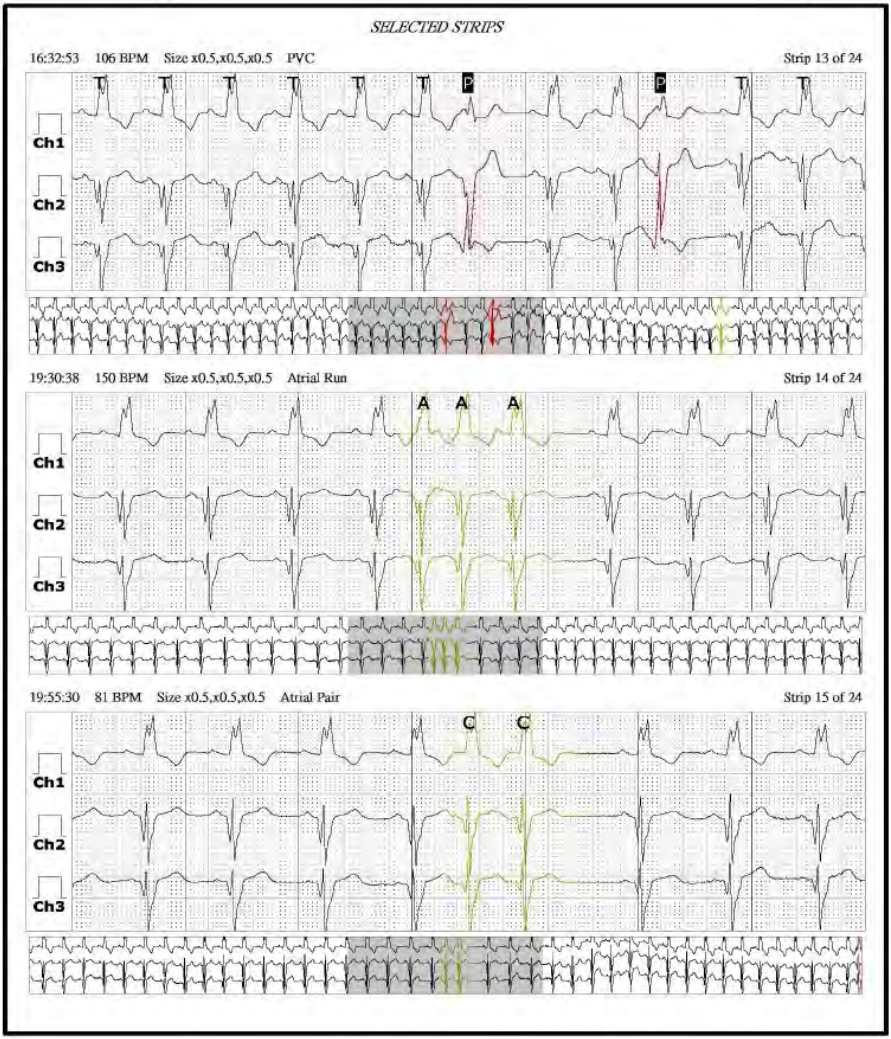


Holter results in 2022 showed no significant abnormality, except some occasional VPCs.

## *Cardiac biopsy*

- Diffuse cytoplasmic vacuolization in hypertrophic myocardium is seen.
- Compatible with Fabry disease.

## *Pedigree*

**Figure 16.**

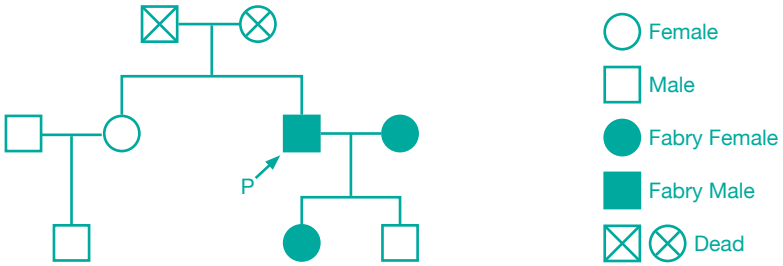


- All family members listed underwent screening.
- Only this patient' s daughter was detected positive for IVS4 mutation. Because her enzyme level, cardiac echography, EKG and 24-hour Holter results were all normal, she only attends to our clinic for regular follow-up annually.

## *Discussion*

- The patient showed some EKG defects frequently observed in patients with Fabry disease, including changes related to LVH, short PR intervals, and bundle branch blocks.
- According to a Taiwanese study, approximately half of male patients with the c936+919G>A mutation test positive for LVH in their fifth decade of life.
- Ventricular arrhythmias are not rare in Fabry disease. However, non-sustained VT can occur in 21% of cases, whereas sustained VT affects only 1% of patients. Sudden death is even more rarely observed. In a 1.9-year-follow-up study, only one of 78 patients died suddenly. A systematic review study indicated that the incidence of sudden death events in patients with Fabry disease ranges from 0.34% to 1.4% per year. Thus, sudden death with VT/VF as the first clinical presentation of Fabry disease, as observed in this case, is uncommon.
- Previous studies have indicated that patients with a high baseline LVMI may experience an increased decline in left ventricular mass after the first year of ERT. In the present case, the patient' s baseline LVMI was extremely high, and his LVH improved after ERT was initiated.
- Recent guidelines recommend that amiodarone should be avoided in Fabry disease because of concerns regarding the induction of lysosomal dysfunction. However, the patient in this case had been taking amiodarone for several years and showed good rhythm-control. In addition, no significant side effects or interactions with ERT were noted. Further studies are needed to determine the exact clinical effect of amiodarone in Fabry disease and to identify other appropriate antiarrhythmic agents that are sufficiently potent for the treatment of patients with Fabry disease.
- There are two main forms of amiodarone-induced thyrotoxicosis: type I and type II. Type I usually involves the abnormal thyroid glands and is the result of excessive iodine-induced hormone synthesis and release. Type II is a destructive thyroiditis that leads to the release of preformed (stored) thyroid hormones from damaged thyroid follicular cells. Although not mentioned in the laboratory panel section, no thyrotropin receptor antibody was detected in the present case, indicating that the amiodarone-induced thyrotoxicosis was more likely to be type II.

## *References*


1. Shah JS et al. Am J Cardiol 2005;96:842–6.
2. Sheth KJ, Thomas Jr JP. J Electrocardiol 1982;15:153–6.
3. Baig S et al. QJM 2019;112:3–9.
4. Yokoyama A et al. Br Heart J 1987;57:296–9.
5. Efthimiou J et al. Postgrad Med J 1986;62:285–7.
6. Namdar M et al. Front Cardiovasc Med 2016;3:7.
7. Ikari Y et al. Br Heart J 1992;68:323–5.
8. Pieroni M et al. J Am Coll Cardiol 2021;77:922–36.
9. Azevedo O et al. Int J Mol Sci 2021;22:4434.
10. Arends M et al. J Med Genet 2018;55:351-8.

# Fabry Disease Case Book

## Case 16:

A patient with IVS4 variant Fabry disease and chest pain

陳柏升醫師

## *Clinical pearls*

- Atypical Chest Pain in Fabry Disease: Patients with Fabry disease may be misdiagnosed with CAD or ACS because of chest pain, with or without elevated serum troponin levels and/or ST-T abnormality on ECG, all caused by LVH.
- Considering Fabry Disease in Differential Diagnosis: When patients present with ACS or CAD symptoms, but coronary angiography reveals no evidence of obstruction, Fabry disease should be considered in the differential diagnoses for potential underlying cause in patients with LVH.

## *Patient profile*

### Case presentation

- A 78-year-old man experienced chest pain for 2 hours and visited emergency department at another hospital in April 2022.
- Based on his symptom of chest pain, ST-T changes on EKG, and elevated cardiac enzyme levels on laboratory examination, ACS was strongly suspected. However, no stenotic lesions were detected on coronary angiography.
- Echocardiography revealed LVH without other significant structural abnormalities. Considering the patient's age, unexplained LVH, and no history of hypertension, further investigation for Fabry disease was conducted.
- A diagnosis of Fabry disease with IVS4 variant and concentric nonobstructive LVH was confirmed in August 2022, and the patient was referred to our hospital for further treatment.
- Upon detailed medical history review, the patient reported exertional dyspnea, persisting for 2–3 years, with progressive worsening of the condition over six months before the chest pain episode. However, he did not seek medical help.
- ERT with agalsidase beta (1 mg/kg once every other week) was initiated from December 2022, starting with the lowest infusion rate of 15.5 mg/h and the total infusion time of 4.5 hours.
- No infusion-related reactions have been reported at low infusion rates. Thus, the infusion rate was gradually increased to 40 mg/h with a total infusion time of one hour and 45 min in June 2023. The patient tolerated ERT well, under the current infusion rate.
- Annual follow-up examinations, including laboratory tests and functional evaluation, will be conducted over the next 2–3 months.

## Medical history and personal history

- Occupation: farmer.
- No smoking or alcohol consumption.
- No history of systemic disease, including hypertension, diabetes, dyslipidemia, CKD.

## Physical examination

No obvious Fabry-related finding.

## *Laboratory panels*

### Figure 1.

| Systemic: | Reference | 2022-08-02 |
|---|---|---|
| Hb, g/dL | 12-17 | 12.9 |
| Plasma Lyso-Gb3, ng/mL | <1.8 | 6.6 |
| GAL-a enzyme activity, μmol/L/h | >15.3 | 0.86 |
| GLA mutation | | c.6402-810G>A (IVS4+919G>A) |

This patient was diagnosed with IVS4 variant Fabry disease at other hospital based on high lyso-Gb3 level, low GAL-a enzyme activity, and positive for GLA mutation (IVS4+919G>A).

### Figure 2.

| | Reference | 2022-04-02 |
|---|---|---|
| CK-MB, ng/mL | ≤4.9 | 16.0 |
| Troponin T, pg/mL | ≤0.014 | 89.7 |

Laboratory data obtained at other hospital (in April 2022) revealed elevated levels of cardiac enzymes.

## Figure 3—4.

| Renal | Reference | 2022-09-12 |
|---|---|---|
| eGFR, mL/min | ≥60 | 76.8 |
| Proteinuria, mg/mg | <15 | 8 |
| ACR, mg/g | <30 | 2.8 |

| Cardiac | Reference | 2022-09-12 |
|---|---|---|
| Troponin T, pg/mL | <0.014 | 40.7 |
| NT pro-BNP, pg/mL | <125 | 1308 |
| 6MWT, m | | 220(2022-11-2) |

Laboratory data obtained in this patient' s first visit to our hospital (in September 2022):

- Normal renal function with no proteinuria.
- Still elevated troponin T and NT-proBNP at several months after the chest pain episode.
- Poor result of 6MWT because of this patient' s inability to follow the instructions of test.

## *Chest radiograph*

Figure 5.

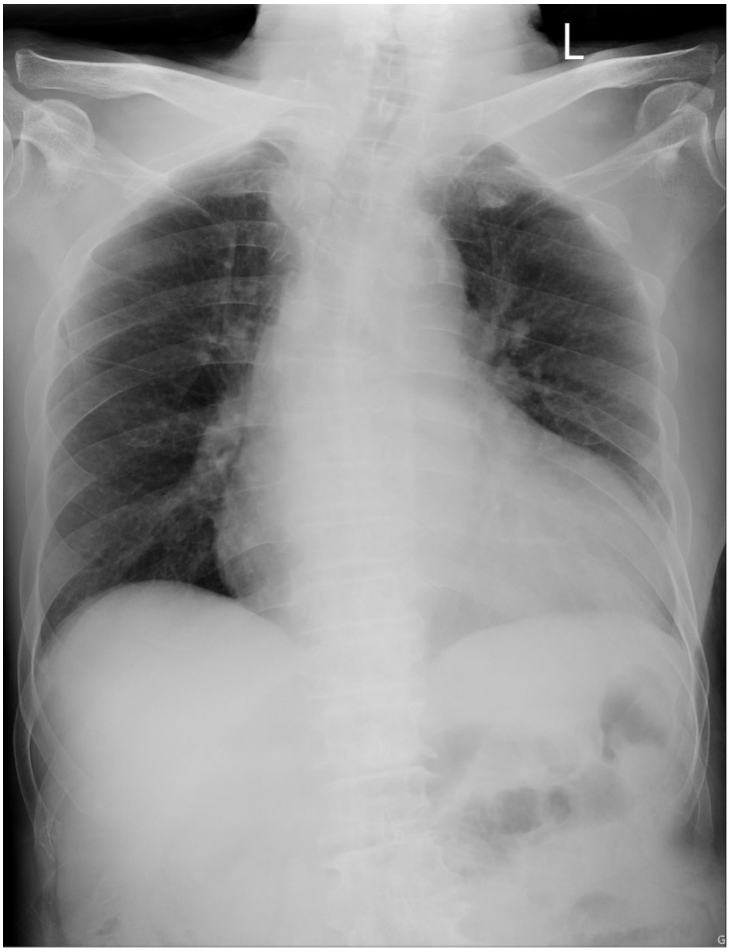


Chest radiograph obtained at other hospital (in April 2022):

- Obvious cardiomegaly.
- Slightly bilateral pulmonary congestion.

## *Electrocardiography*

### Figure 6.

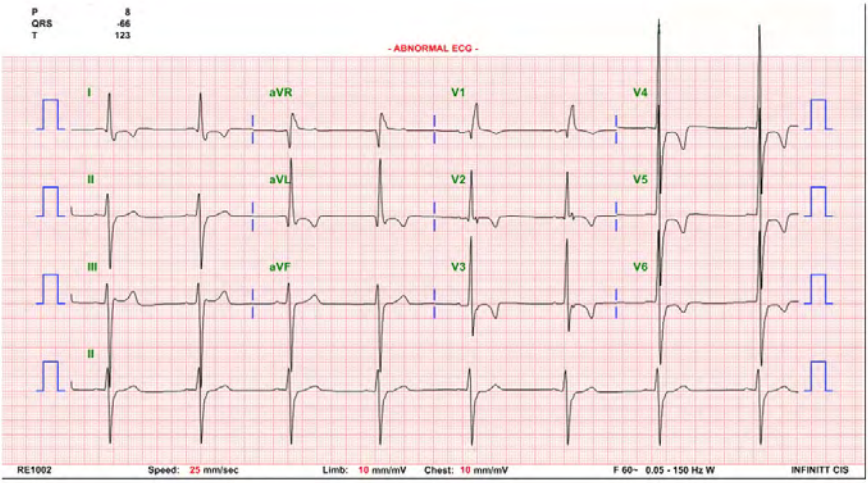


EKG obtained at other hospital (in April 2022):

- Sinus bradycardia.
- RBBB and left anterior fascicular block.
- LVH with strain pattern.

## *Cardiac echography*

### Figure 7—10.

| | Reference | 2022-04-08 |
|---|---|---|
| IVSd, mm | 6-12 | 25.2 |
| LVIDd, mm | 40-60 | 42.5 |
| LVPWd, mm | 6-12 | 23 |
| EF, % | 50-80% | 80.4 |
| LVd mass ind, g/m$^2$ | 49-115 | 336 |

Transthoracic echocardiography (A) long-axis view (B) 4-chamber view (C) M-mode of this patient. Cardiac echography performed at other hospital (in April 2022) showed marked LVH with thickened IVS (thickness 25.2 mm).

## *Coronary angiography*

### Figure 11—14.

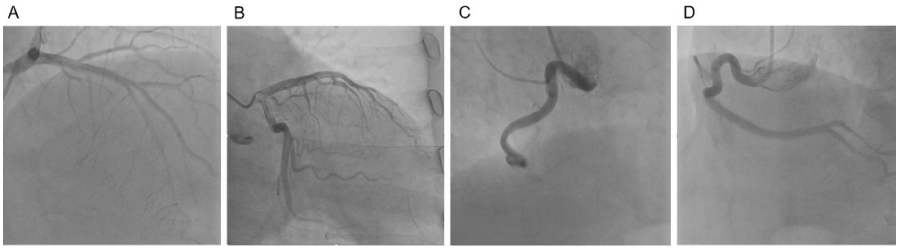


Coronary angiography performed at other hospital (in April 2022). (A) and (B) left coronary artery, (C) and (D) right coronary artery. No stenotic lesion suggesting ACS was observed.

## *Cardiac magnetic resonance imaging*

Figure 15—17.

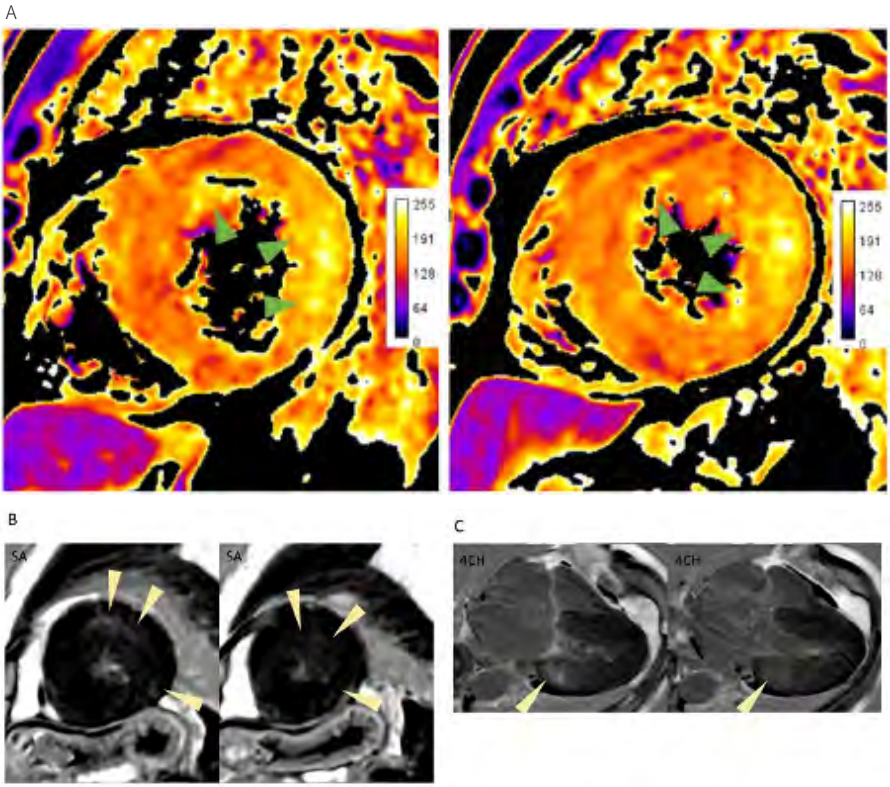


Magnetic cardiac resonance (in July 2022) showed (A) T2 map demonstrated myocardial edema (green arrowheads) in the mid-wall of LV and LGE (B) short-axis and (C) 4CH view showed ill-defined and infiltrative myocardial fibrosis (yellow arrowheads) in the mid-wall of LV.

## *Pedigree*

Figure 18.

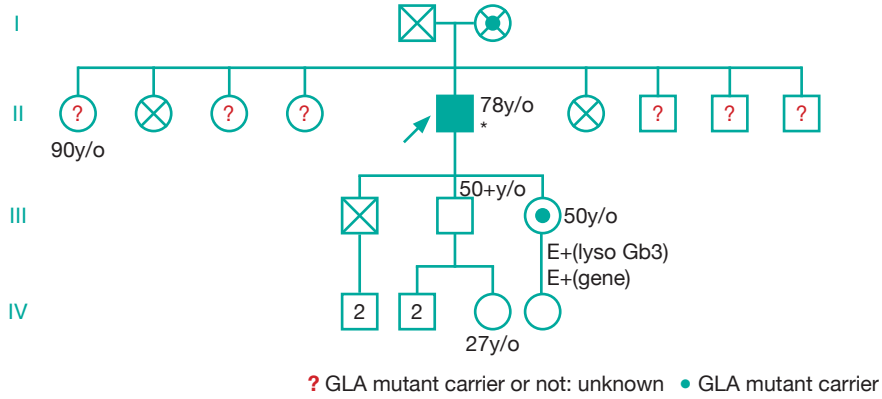


- This patient' s siblings were asked to undergo Fabry screening but ignored.
- Both children underwent Fabry screening, and the daughter was identified as carrying a GLA mutation; however, she had not visited our hospital for screening.

## *Discussion*

- The patient had marked LVH, progressive exertional dyspnea in the last 6 months, and elevated cardiac enzyme levels; therefore, ERT should be considered based on recommendations of modest guidelines. Both agalsidase alfa and beta were considered as ERT options for this patient.
- Chest pain may occur in some patients with Fabry disease and may lead to misdiagnosis of ACS, if accompanied by old age, ST-T changes on EKG, or elevated cardiac enzyme levels. In patients with Fabry disease, elevated serum troponin levels are attributed to cardiomyocyte damage resulting from Gb3 accumulation, and ST-T abnormalities on the EKG are caused by LVH.
- In clinical practice, if patients with LVH present with symptoms indicative of CAD with or without elevated cardiac enzyme levels, implying myocardial damage, and if no culprit lesion of the coronary artery accounts for the clinical scenario, comprehensive investigation should be performed to determine the underlying disease.

# Fabry Disease Case Book

## Case 17:

Classic Fabry disease coexisting with systemic lupus erythematosus

賴志泓醫師

## Clinical pearls

- Classic Fabry disease is an uncommon disease that affects multiple organs and has variable clinical manifestations, particularly in female patients.
- Very few cases of Fabry disease coexisting with SLE have been reported. Given that SLE and Fabry disease share similarities in the organ systems involved, timely diagnosis of Fabry disease in a patient with SLE is difficult.
- Diagnosis of Fabry disease in a patient with SLE can be delayed, leading to inexplicable progression of organ damage despite the administration of adequate treatment for the underlying disease.
- Considering the overlaps in organ system involvements in SLE and Fabry disease, Fabry disease-specific presentations, such as HCM or neuropathic pain, may be appropriate as markers of disease activity. Markers of SLE activity should be monitored as well.

## Patient profile

### Case presentation

- A 38-year-old female who was diagnosed with SLE 25 years ago.
- Despite undergoing aggressive therapy, including use of disease-modifying antirheumatic drugs (hydroxychloroquine and azathioprine) and prednisolone, since May 2019, the patient’s proteinuria persisted and progressed, while her SLE was generally inactive.
- She was referred to our cardiology clinic in 2021 due to progressive shortness of breath.
- Review of the patient’s history revealed that she had experienced episodes of shortness of breath and had been diagnosed with heart failure at another hospital in 2019.
- CAD was excluded based on the patient’s past laboratory data and cardiac stress imaging findings. Pulmonary hypertension was suspected because of her SLE history. However, her EKG morphology (LVH with strain pattern) did not suggest pulmonary hypertension.
- HCM with HFpEF was diagnosed based on her echocardiography findings, even though these conditions do not commonly occur in SLE.
- Under the presumption that the patient had infiltrative cardiomyopathy with an inherent tendency (the father had HCM), whole exome sequencing of the

genetic HCM panel and cardiac MRI were performed.

- The cardiac MRI images were inconclusive for establishing a diagnosis except for severe LVH. However, whole-exome sequencing revealed no SRC mutation but returned positive results for the GLA: c.1228A>G mutation. Thus, the patient was diagnosed with classic Fabry disease based on the information in the existing literature.
- Comprehensive ophthalmic, auditory, and neurological examinations were performed for complete evaluation of the signs and symptoms of classic Fabry disease. No ophthalmic manifestation, stroke, or conductive abnormalities of the peripheral nerves were observed; only bilateral symmetric high-frequency hearing impairment was detected. The patient’s FOS-MISSI was 32 (including cardiac and renal scores of 18 and 4, respectively), indicating moderate disease severity.
- After explaining all the treatment options to the patient, she opted for agalsidase alpha rather than migalastat owing to her heavy caffeine consumption.
- The patient underwent ERT once every other week for the treatment of Fabry disease, and was taking a SGLT2 inhibitor, MRA and β-blocker for the management of the HFpEF.
- After six months of treatment, there was no significant change in SLE disease activity. However, her GLS on cardiac echography and neuropathic pain improved significantly (GLS, from -8% to -13%; FOS-MISSI, from 4 to 3 and 6 to 2 for the general and neurological domains, respectively).

## Family history

The patient's father, who had ESRD and stroke, passed away at the age of 38 years due to sudden cardiac death.

## Physical examination

- Skin: recurrent malar rash; papules and macules on the lower legs.
- Neurological: heat intolerance with burning sensation, especially in the morning.
- Hearing/visual defects: no clinically significant hearing or visual defects; only intermittent tinnitus was reported.

## *Laboratory panels*

### Figure 1.

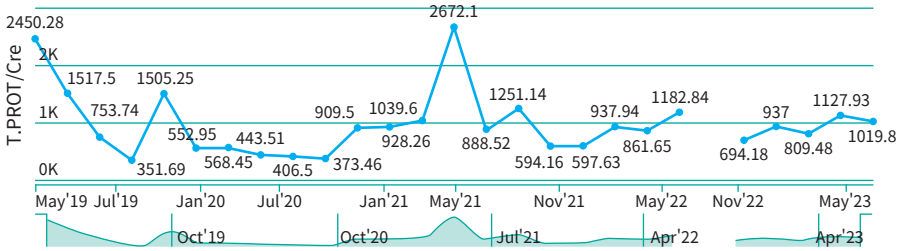


Severe and progressive proteinuria from 2019 to 2013 despite medical treatment.

### Figure 2.

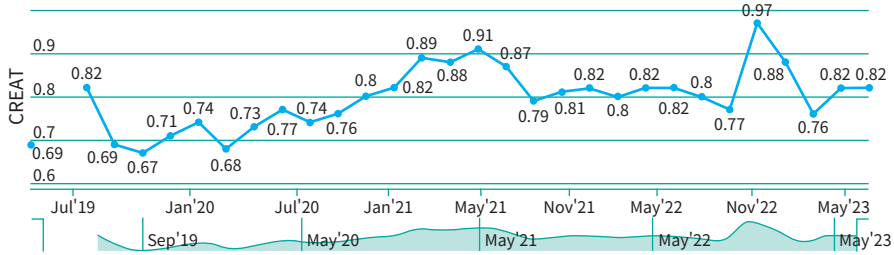


Compared to significant proteinuria, this patient’s creatinine level was acceptable.

## Figure 3-4.

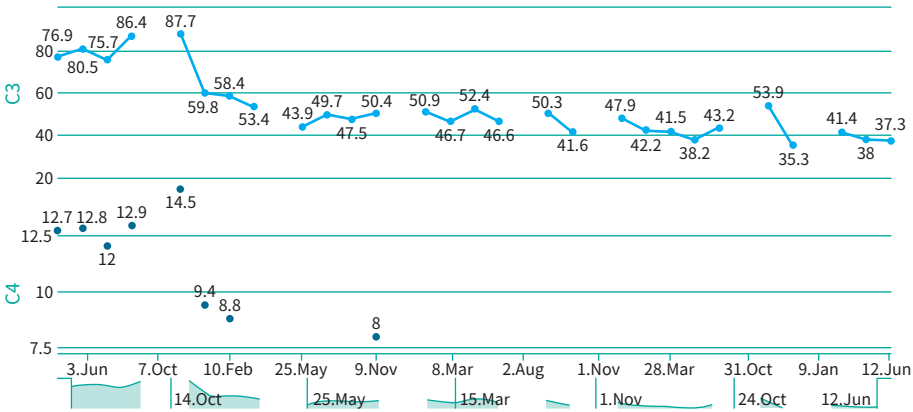


Based on C3 and C4 level, this patient's SLE was generally under control between 2019 and 2023.

## Figure 5.

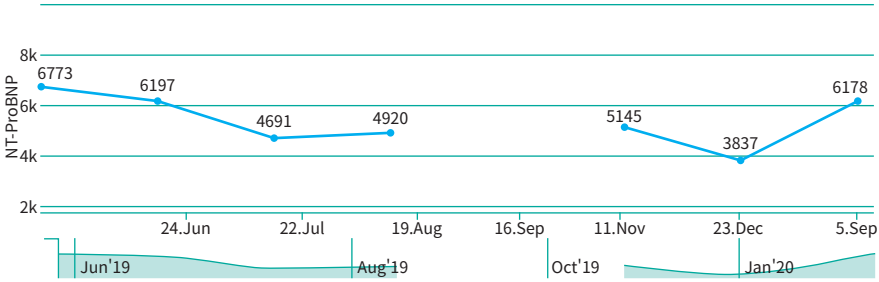


Persistently elevated NT-proBNP level was noted from 2019 to 2022.

## Figure 6.

| Systemic: | Reference | Date 1 (baseline) | Date 2 |
|---|---|---|---|
| Hb | 12-17 g/dL | 11.5 | |
| DBS Lyso-Gb3 | <0.31 ng/ml | 0.86 ↑ | |
| GAL- enzyme activity | >1.53 umol/L/h | 1.59 | |
| GLA mutation | -- | **GLA: c.1228A>G** | SRC(-) |

- Classic Fabry disease was diagnosed by GLA mutation.
- Mild elevation of lyso-Gb3 level was also noted, while GLA-a enzyme activity was within normal range.

## *Chest radiograph*

## Figure 7-9.

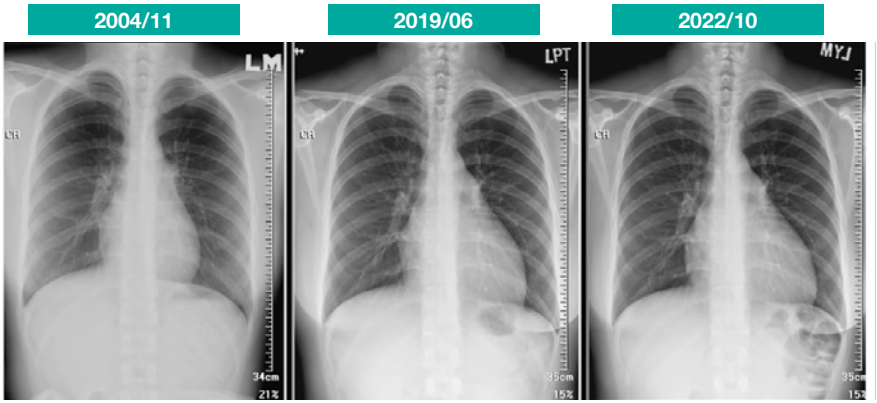


Chest radiograph images from 2004 to 2022 showed progressive cardiomegaly.

## *Cardiac thallium scan*

Figure 10-11.

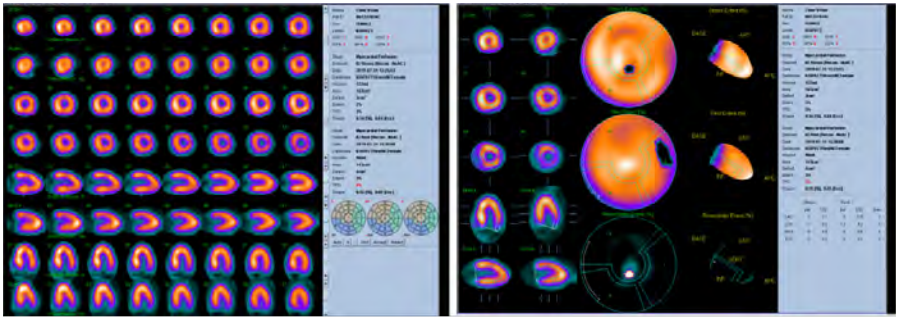

Thallium scan in 2019 revealed no evidence of CAD.

## *Electrocardiography*

Figure 12.

EKG in 2022 showed LVH with ST depression.

## *Cardiac echography*

Figure 13-19.

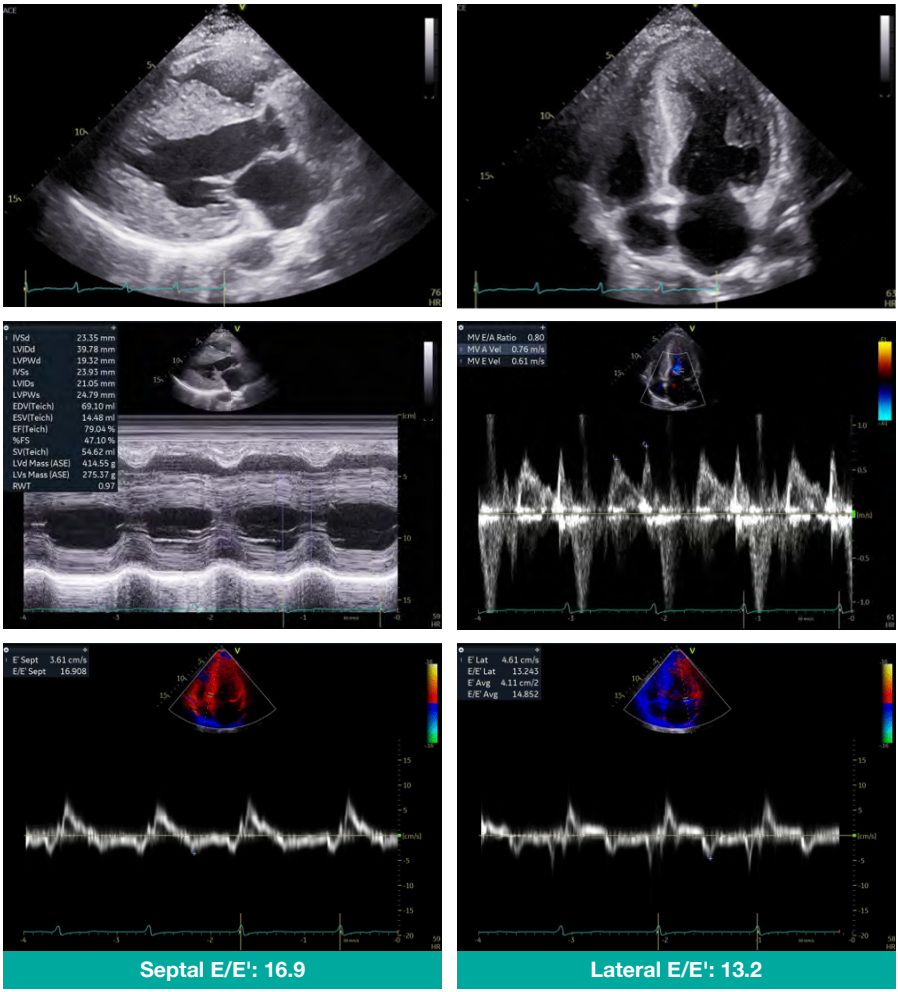


**Septal E/E': 16.9** | **Lateral E/E': 13.2**

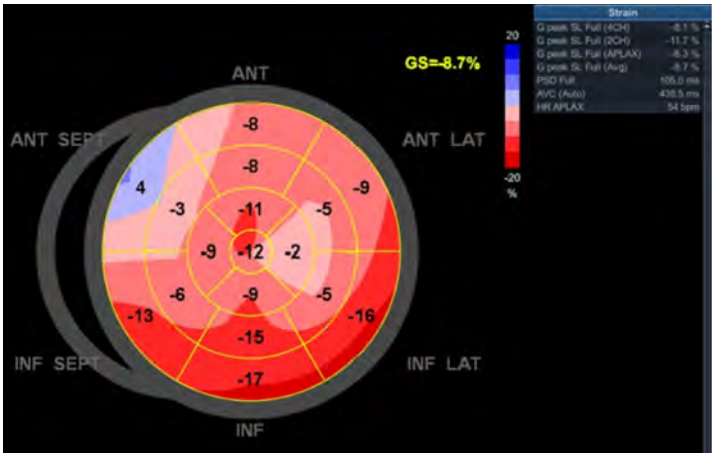


Baseline cardiac echography before ERT (in 2022).

- Marked concentric LVH (23, 19 mm) with mild SAM (Tran LVOT peak/mean pressure gradient: 29/23 mmHg).
- LVEF 56%.
- Left atrial dilation (42mm); left ventricular chamber (4.0, 2.1 cm)
- Mitral diastolic dysfunction (E/E’ septal: 16.9, E/E’ lateral: 13.2).
- Low GLS: -8.7%, more significant in anterior septal region.

Figure 20.

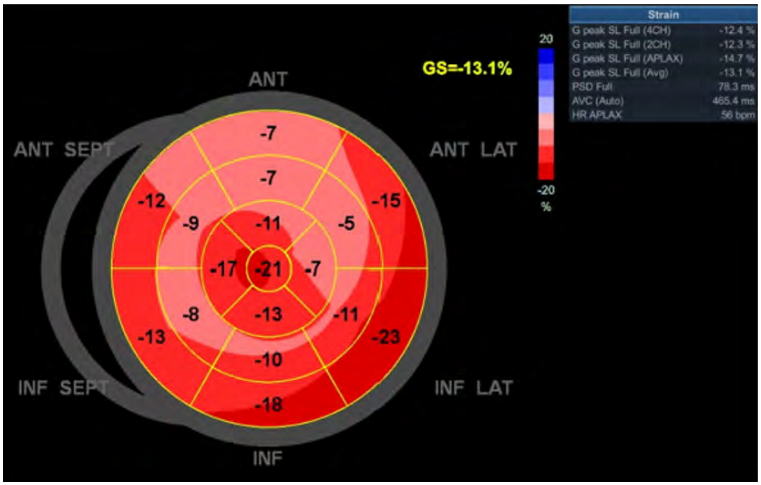


Cardiac echography after six-month ERT showed significant improvement of GLS (from -8% to -13%).

## *Cardiac magnetic resonance imaging*

Figure 21-23.

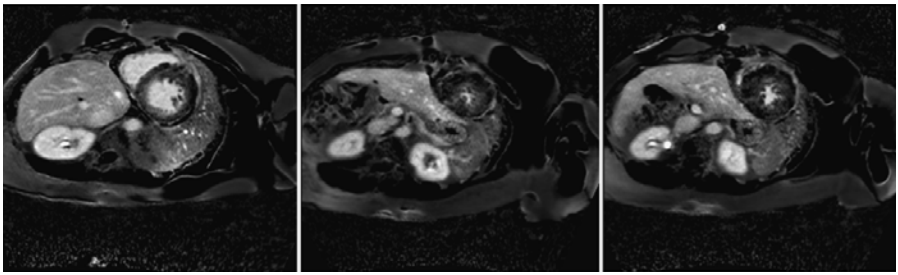

Cardiac MRI showed LVH with mild patchy LGE (AHA segment 9) at inferior septal wall of mid left ventricular chamber (12-26 mm, septum 24-26 mm).

Figure 24-25.

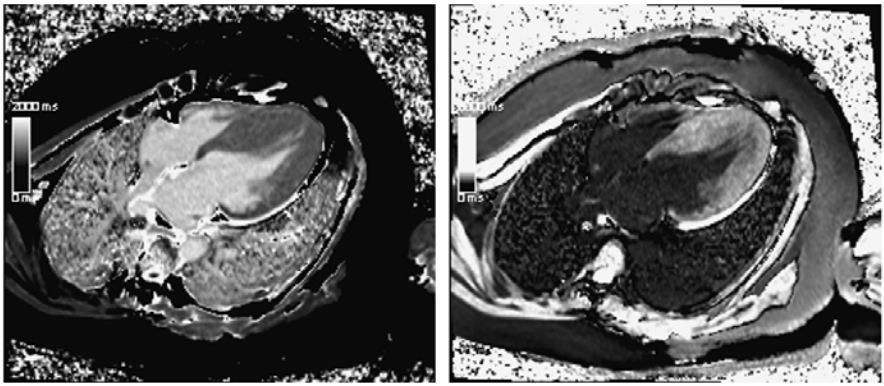

Pre-contrast native T1 mapping.
4ch T1 mapping showed mild elevated native T1 value (approximately 1000-1100 ms)

## *Pedigree*

Figure 26.

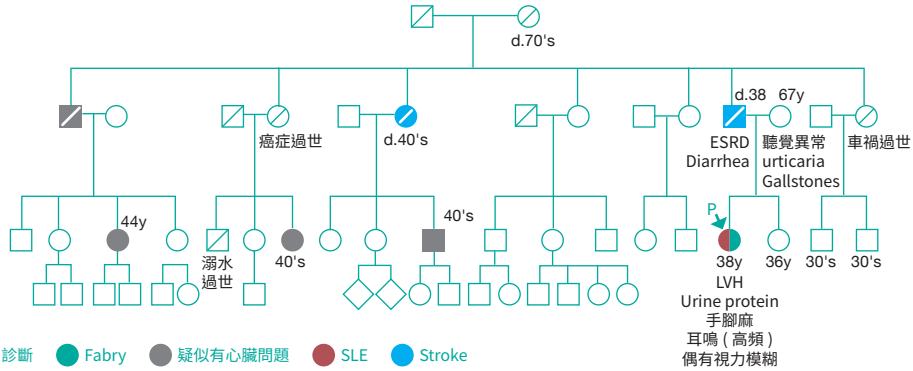


- This patient's younger sister carries heterozygous GLA: c.1228A>G mutation, but no clinically significant symptom or sign was found by comprehensive laboratory and image examinations.
- No further Fabry screening was done for paternal family members because loss of contact after this patient's father's death.

## *Discussion*

- GLA: c.1228A>G is classified as a pathogenic mutation in Fabry disease. However, the correlation between this mutation and Fabry disease has been discussed in only six articles, two of which are reports of studies conducted in Taiwan. One of the articles is the report of a study of pediatric patients with the GLA: c.1228A>G mutation who presented with HCM and neuropathic pain. Another article reported the results of Fabry screening in male patients with ESRD, one of whom tested positive for the GLA: c.1228A>G mutation and was diagnosed with classic Fabry disease. The patient also had a history of ESRD, HCM, neuropathic pain, and stroke at the age of 40 years.
- Very few cases of SLE coexisting with Fabry disease have been reported. In addition, most of the reported cases were diagnosed incidentally after kidney or cardiac biopsies. In females, the prevalence of SLE is from approximately 8 to 14/10,000, whereas the prevalence of Fabry disease is lower than 4/40,000. Owing to similarities in the organs involved in these two multisystem disorders and the heterogeneous clinical presentation of Fabry disease in female patients, timely diagnosis of Fabry disease in the present case was difficult.
- Both SLE and Fabry disease may involve the neurological, cardiac, dermatological, and renal systems. According to a Fabry Outcome Study, approximately 25% of patients with Fabry disease are misdiagnosed with rheumatological diseases, neuropsychological diseases, orthopedic diseases, and "others," including renal and coronary artery diseases.
- There is some overlap in organ system involvements in SLE and Fabry disease. In a study of 74 young patients with SLE, GLA mutation was not detected in any patient. However, a certain proportion of patients with Fabry disease may carry antinuclear antibodies (21%) or antiphospholipid antibodies (45%) due to abnormal glycosphingolipids accumulation-induced autoimmune reactions.
- Although cardiac involvement can be observed in patients with Fabry disease or SLE, the clinical presentation in each disease varies. More than 50% of patients with SLE show cardiac involvement, and the lesions can be observed in the pericardium, myocardium, endocardium, valve, conduction system, and coronary arteries. The pericardium is typically the first site to be involved. Pericardium involvement occurs in 11–54% of SLE cases. Myocarditis is the most typical feature of myocardial involvement in SLE and can progress to ventricular dysfunction, dilated cardiomyopathy, and heart failure. CAD is the most common cause of death in patients with late-onset or long-term SLE.
- HCM has not been clearly linked to SLE to date. In addition, cases of SLE

complicated with HCM are rare; only 10 cases have been reported so far. One of the possible causes of the occurrence of HCM in patients with SLE is the co-occurrence of other diseases with the HCM phenotype, such as severe hypertension or SRC mutation. Another probable cause is long-term use of medications such as immunosuppressants and chloroquine or hydroxychloroquine.

- In the present case, the patient's heat/cold intolerance, neuropathic pain, HFpEF, severe concentric LVH, increased plasma lyso-Gb3 levels, and elevated NT-proBNP levels were likely caused by Fabry disease, whereas her significant proteinuria may have been primarily caused by SLE. Presence of severe concentric LVH, unexplained progressive proteinuria despite adequate immunosuppressant therapy, and family history can aid the identification of the coexistence of Fabry disease and SLE.
- ERT (agalsidase alpha and beta) and migalastat were possible treatment options in this case. Migalastat is an oral medication with advantages of convenience and not-too-much side effects, but limited using experience. In addition, there is no data on its safety in pregnancy, and patients need to refrain from caffeine consumption two hours before and after taking the medication. There is solid evidence on the efficacy of ERT and its safety in pregnancy; in addition, no food or drink limitations need to be considered when taking the drug. However, the dosing schedule for ERT is inconvenient, and infusion-related reactions and anti-drug antibodies may develop. After sharing the above-mentioned drug information with the patient in the present case, she chose to receive agalsidase alpha because she is a tea lover. In addition, as migalastat needed to be taken every other day, she was concerned that she may miss a dose.

## *References*


1. Clin Genet 2003;63:205–209.
2. Kidney Blood Press Res 2018;43:1636–1645.
3. Lupus 2013;22:1070–1076.
4. Sci Rep 2021;11:5631.
5. Nat Rev Dis Primers 2016;2:16039.
6. J Med Genet 2009;46:540–552.
7. Orphanet J Rare Dis 2022;17:238.
8. Arch Rheumatol 2020;35:7-12.
9. Case Rep Cardiol 2021;2021:6633085.
10. J Inherit Metab Dis 2007;30:365-369.

# Fabry Disease Case Book

## Case 18:

A patient with Fabry disease experienced sudden cardiac death

徐千彝醫師

## Clinical pearls

- Patients with Fabry disease may have cardiac manifestations other than LVH at initial presentation. High-risk screening for Fabry disease is important, and cardiologists should pay attention to patients with conduction problems.
- Fabry disease can progress and present with different clinical symptoms at different ages in the same patient, and the progression rate may differ.
- Early diagnosis and treatment are critical for patients with Fabry disease.

## Patient profile

### Case presentation

- A 59-year-old male with a history of hypertension and arrhythmia under medication control underwent regular follow-up and health examinations at other hospitals.
- The patient experienced cardiac arrest while showering at night in December 2021. He was immediately transported to our hospital in a state of out-of-hospital cardiac arrest and underwent CPR in an ambulance and endotracheal intubation in the emergency room.
- After the ROSC, the patient was admitted to the ICU for hypothermia therapy.
- CAD and intracranial hemorrhage were ruled out using coronary angiography and brain CT. Echocardiography revealed HCM, and Fabry disease or transthyretin amyloidosis was considered the differential diagnosis.
- The 24-hour Holter monitor did not detect VT, VF, or long pauses, and no VT was induced during the electrophysiological study. Thus, no definitive conclusion can be drawn regarding the direct cause of the patient's sudden cardiac death.
- Loop recorder implantation was suggested; however, the patient was hesitant. Endocardial biopsy revealed hypertrophic myocardial tissue with a Fabry-like presentation, fatty infiltration in the myocardium, and degenerated changes in myocytes. Amyloidosis was excluded through special stains.
- Screening was performed under the suspicion of Fabry disease, and a diagnosis of cardiac variant Fabry disease was confirmed in January 2022.
- A careful examination of the patient's medical history revealed that he experienced a syncope episode during mountain climbing in 2017. At that time, he was sent to another hospital where echocardiography revealed mild LVH, with no other clinically relevant findings.

- At that time, no specific intervention was performed because of the impression of vasovagal syncope.
- Due to a policy change, the patient’s approval of ERT was delayed. Electron microscopy was performed to expedite the submission process, and myelin bodies were observed.
- Unfortunately, the patient collapsed after showering in March 2022 during the non-treatment period. EKG upon arrival at the emergency room revealed a high-degree AV block with severe bradycardia (heart rate, < 20/min) and a long pause.
- Consequently, a PPM was implanted to prevent repeated cardiac arrests. ERT with agalsidase beta was initiated in April 2022.
- No allergic reactions occurred in the first six months of treatment, and premedication was no longer required during the third infusion course. The ERT infusion time was gradually decreased and shortened to 120 min during the 30th course of administration.
- Following PPM implantation, no additional arrhythmias were recorded, although intermittent SVTs were observed. As a result, all previous medications were discontinued, and the only antiarrhythmic drug was switched to diltiazem.
- One year after ERT, the patient’s lyso-Gb3 level significantly decreased, and no new arrhythmia was detected.

## Past medical history

Hypertension and arrhythmia were controlled by 10 mg of propranolol once daily, 100 mg of amiodarone once daily, and 1.25 mg of bisoprolol once daily.

## *Laboratory panels*

### Figure 1-2.

| Item | Reference | 2021/12/27 PM |
|---|---|---|
| BUN | | 2.3 |
| Cr | | 1.1 |
| Na | | 135 |
| K | | 4.1 |
| Glucose | | **247** |
| ALT | | 65 |
| Lactate | 4.5--19.8 mg/dL | **66.2** |
| NT-proBNP | | 1798 → **5688** |
| CPK | | 219 → **1739** |
| CK-MB | | 84 → **103** |
| hsTnT | | 0.076 → **1.120** |

| Item | Reference | 2021/12/28 AM |
|---|---|---|
| T.Chol | | 152 |
| TG | | 55 |
| HDL | | 83 |
| HbA1c | | 5.5% |
| ACTH | 7.9-47.1 pg/mL | 40.3 |
| Cortisol | 6.2-19.4 ug/dL | **26.2** |
| TSH | | 0.38 |
| T3 | 80-200 | **58** |
| fT4 | 0.93-1.70 | **1.87** |

Laboratory data obtained while cardiac arrest and on the next day

- Elevated cardiac enzymes.
- Increased lactate level due to profound hypoperfusion induced tissue hypoxia.
- No significant endocrinologic abnormality; acceptable thyroid and cortical functions.

## Figure 3.

| 日期 | 2021/12/28 | 2022/01/19 | |
|---|---|---|---|
| 篩檢項目 | ( 男性 ) 法布瑞氏症篩檢 | 複篩全血法布瑞氏篩檢<br>Lyso-Gb3 test / GLA gene | |
| **Reference** | - Normal > 1.5<br>- Borderline : 0.6 ~ 1.5<br>- 陽性 < 0.6 | <0.8 | GLA gene mutation |
| **Test** | **1.25 umol/hr (Borderline)** | **3.22 ng/mL** | **[c.640-801G>A] hemizygous** |

Fabry screening in 2021 showed borderline results, but repeated whole blood screening confirmed the diagnosis of cardiac variant Fabry disease by high lyso-Gb3 level and positive for c.640-801G>A mutation.

## Figure 4-5.

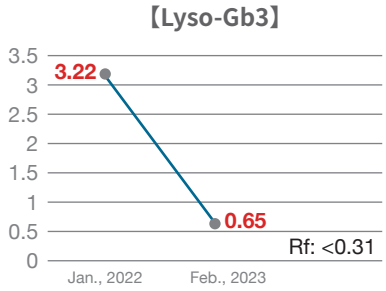


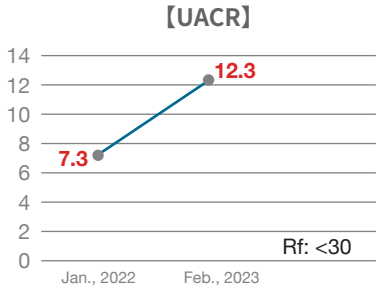


After one year of ERT, this patient's lyso-Gb3 level decreased significantly, and no proteinuria occurred.

Figure 6-7.

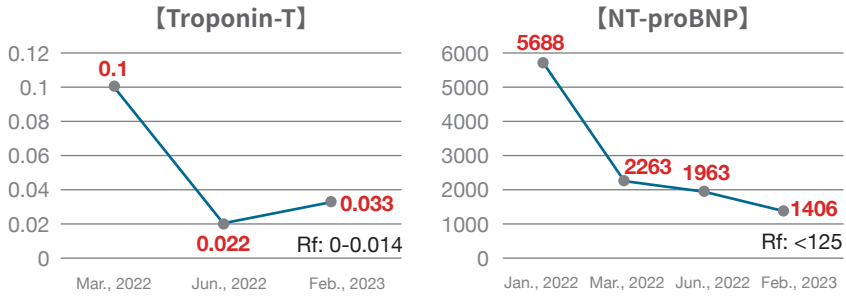


This patient's troponin T and NT-proBNP gradually decreased along with ERT, but still higher than reference level because of LVH.

## *Chest radiograph*

Figure 8.

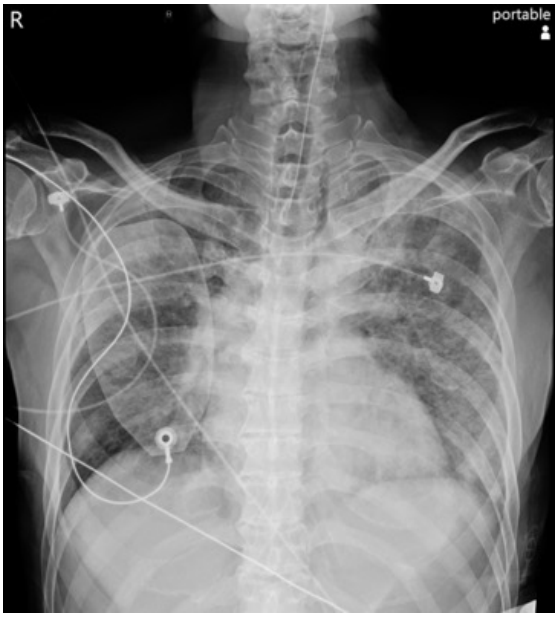


Chest radiograph after CPR (in 2021) showed congestive pulmonary edema; endotracheal intubation and transcutaneous pacing were in place.

Figure 9.

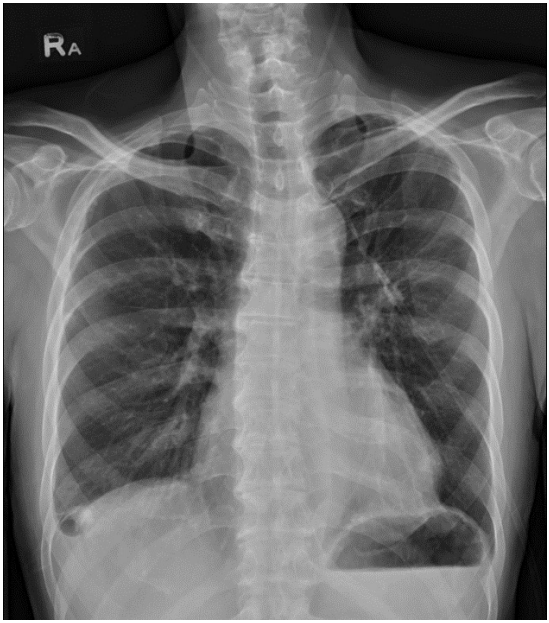


Chest radiograph after receiving three to four-week treatment in the first admission (in January 2022) revealed resolved pulmonary edema and decreased cardiac volume.

Figure 10-15.

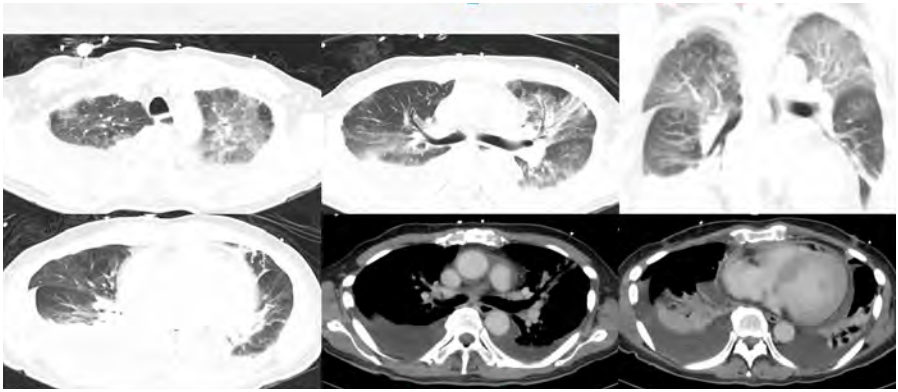

Chest CT images after CPR (in 2021)

- Patchy ground-glass opacity with interstitial thickening in both lungs.
- Passive atelectasis of bilateral lower lobes with moderate bilateral pleural effusion. Pulmonary edema was suspected.
- Mild pericardial effusion.

## *Electrocardiography*

Figure 16.

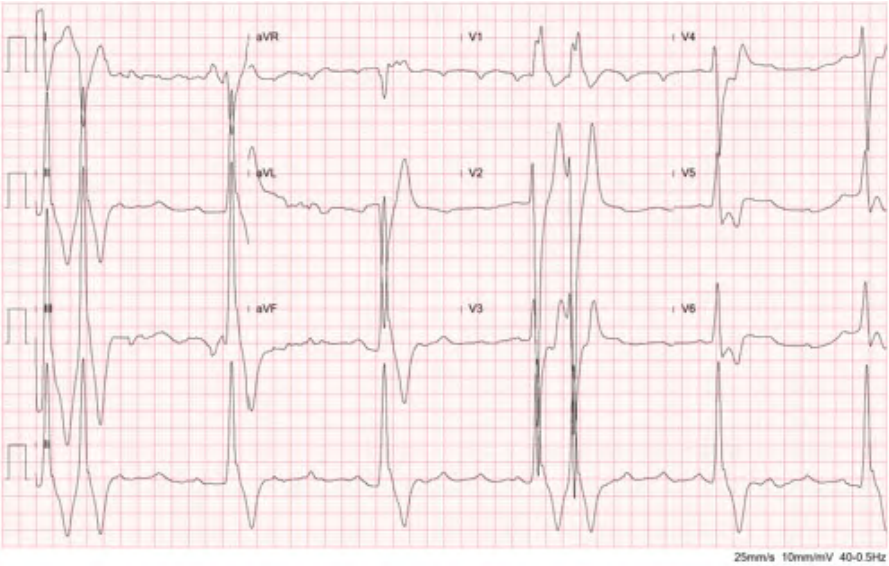


EKG right after CPR (in 2021) showed unstable rates, supraventricular rhythm with AV dissociation and RBBB pattern.

## Figure 17.

EKG after the first ROSC (in 2021) revealed sinus supraventricular tachycardia with RBBB pattern.

## Figure 18.

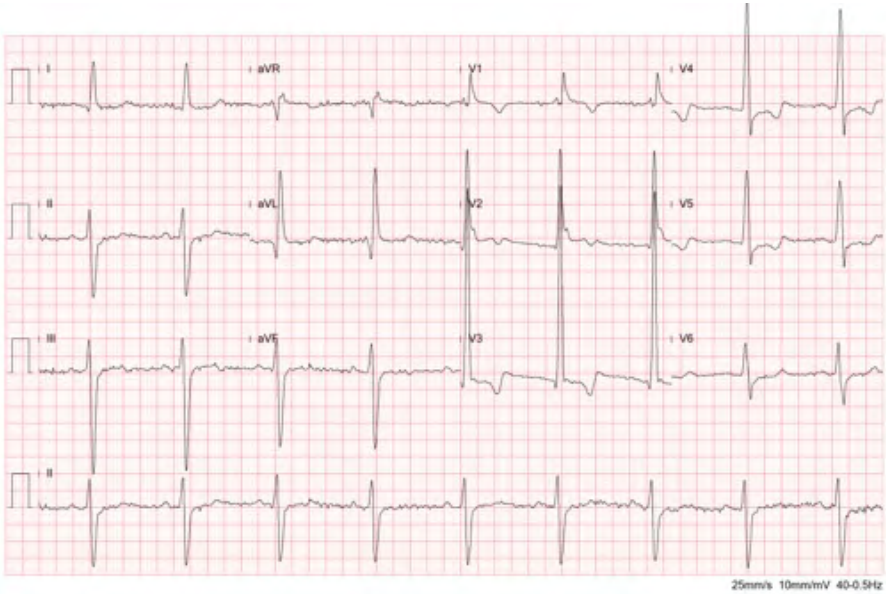


Follow-up EKG on the next day of the first ROSC (in 2021)

- Sinus rhythm.
- Left axis deviation with RBBB.
- Mild early transition pattern and increased QRS voltage.
- Secondary ST-T changes on lateral walls.

## Figure 19.

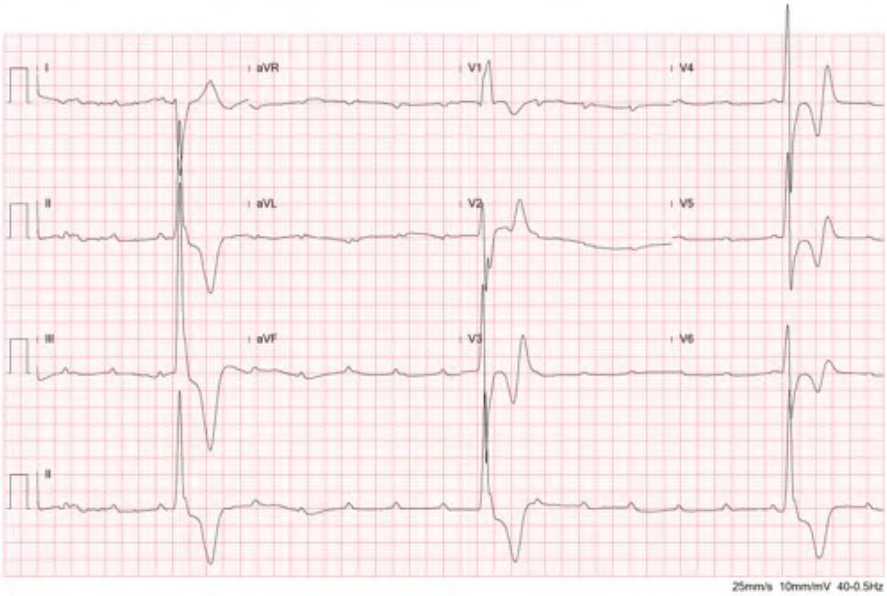


EKG right after the collapse episode (in 2022) showed high degree AV block, ventricular escape rhythm, similar with the morphology right after previous CPR.

## Figure 20.

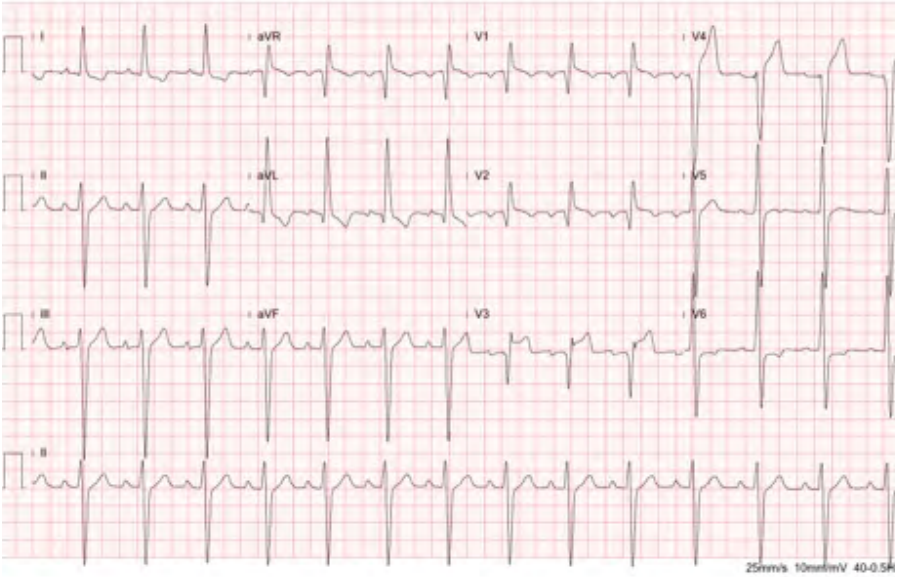


EKG after the second ROSC (in 2022) revealed resolution of high degree AV block.

## Figure 21.

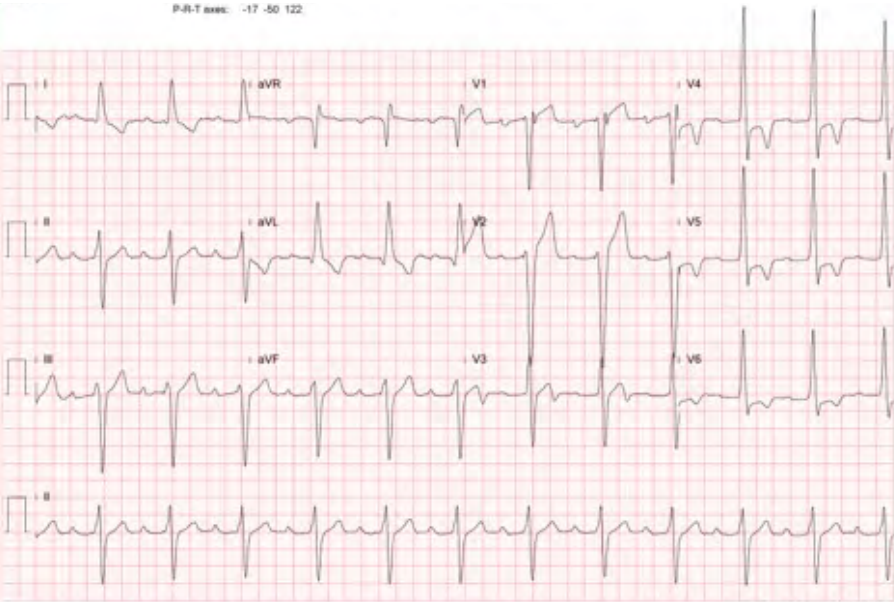


Follow-up EKG after ERT and PPM implantation (in February 2023) showed secondary repolarization abnormality as before and good pacemaker function.

## *24-hour Holter*

Figure 22-26.

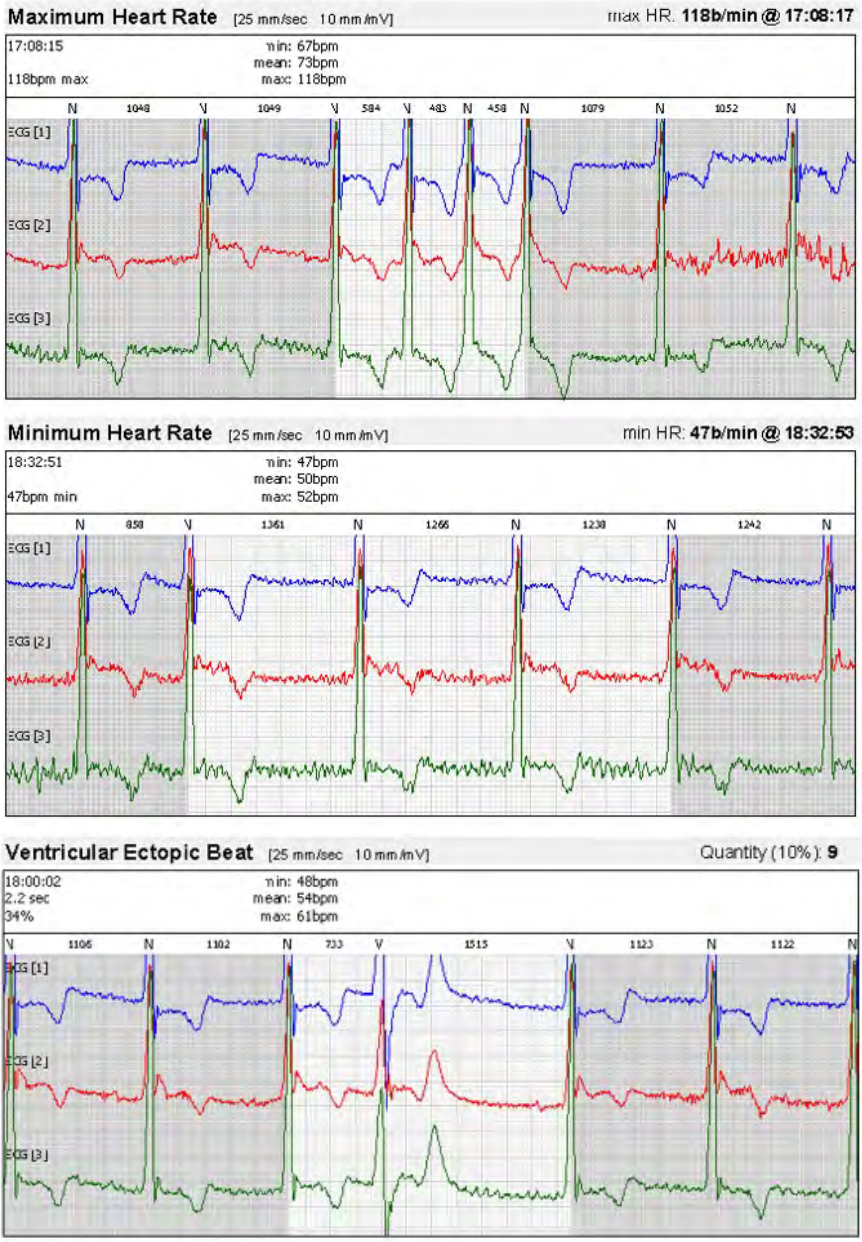

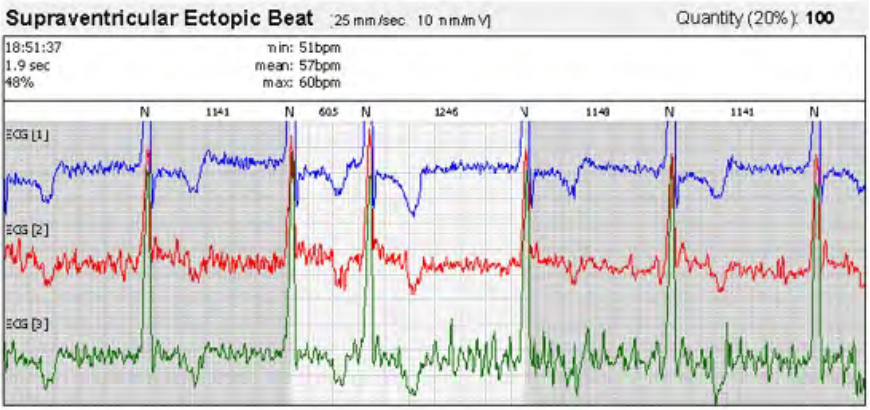


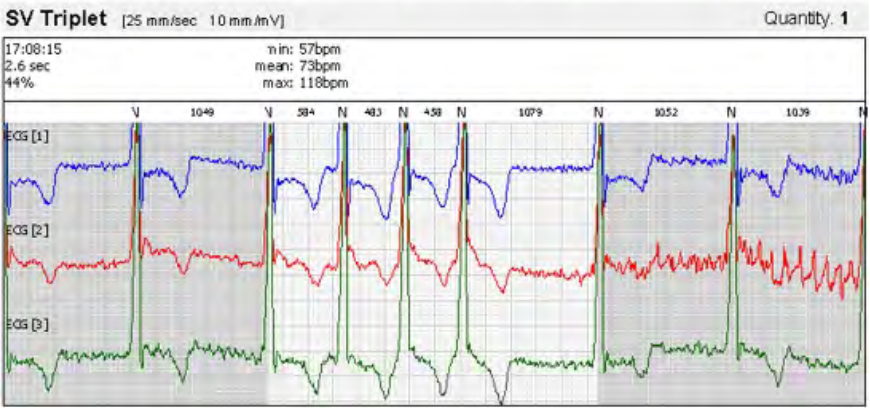


24-hour Holter in ICU after the first ROSC (in 2021)

- Baseline heart rate average was approximately 60 beats per minute.
- No significant ventricular arrhythmia was noted except intermittent supraventricular ectopic beats.
- No VT, VF or long pause was found.

## Figure 27-29.

| General | |
|---|---|
| Beats | 97467 |
| V beats | 4 (0.00%) |
| SV (normal) beats | 73 (0.07%) |
| Paced beats | 97390 (99.92%) |
| | CH1:V5 CH2:V2 CH3:II |
| AFib/AFL | 0/0 |
| AFib/AFL% | 0%/0% |
| Artefacts% | 2.58% |

| Heartrate and HRV | |
|---|---|
| Min. HR | 58 at 06:22:16 |
| Max. HR | 107 at 07:50:07 |
| Average HR | 74 |
| Average HR Day | 78 |
| Average HR Night | 67 |
| #Beats in Tachy | 19 (100 bpm) 0.0% |
| #Beats in Brady | 0 (45 bpm) 0% |
| Longest Pause | --- at --- |
| Longest QTc | --- / QTc: --- at --- |

| Ventricular Events | |
|---|---|
| V ectopic beats | 4 |
| Couplets | Mono: 0 Poly: 0 |
| Triplets | 0 |
| Isolated V | 0 |
| Bigemini | 0 |
| Trigemini | 0 |
| VT | 0 |
| Most severe VT | --- (---) at --- |
| NSVT | 0 |
| Salvo | 0 |
| IVR | 0 |

| Supraventricular Events | |
|---|---|
| Pause | 0 |
| Tachycardia | 1 |
| Most severe SVT | 10.4 Sec (defined by length) with 107 Bpm at 07:50 |
| Bradycardia | 0 |
| Most severe Brady | --- Sec (defined by length) with --- Bpm at --- |
| SV Couplet | 0 |
| SV Triplet | 0 |
| PSVT | 0 |
| Irreg. Rhythm | 0 |
| SV Ectopic beats | 42 |

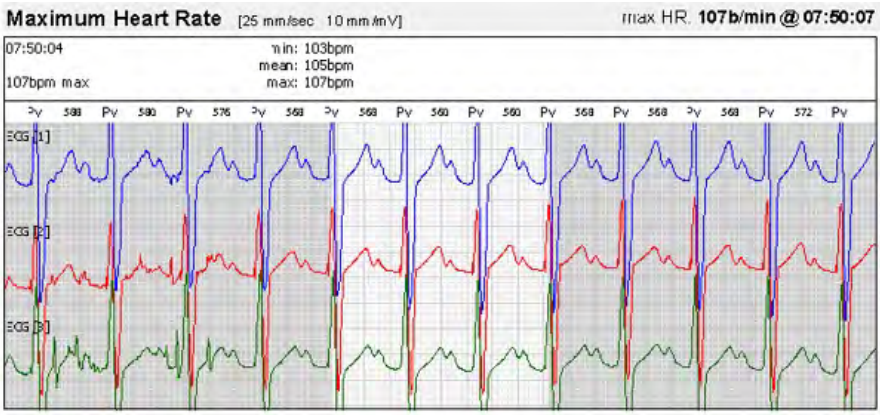

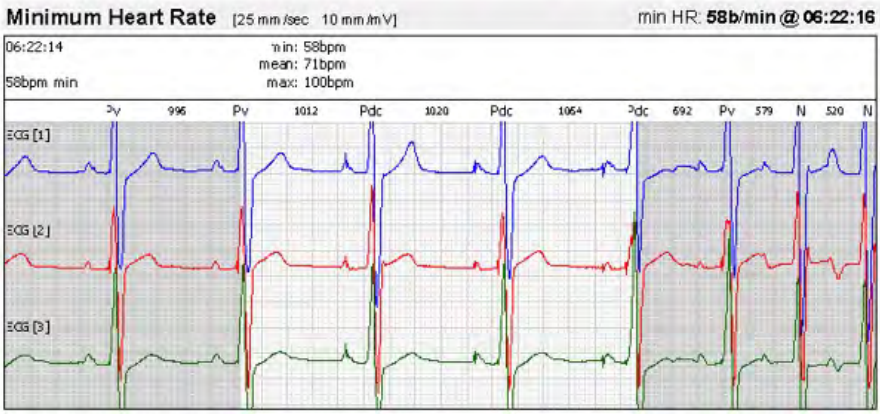


No pause was seen by 24-hour Holter after PPM implantation.

Figure 30-34.

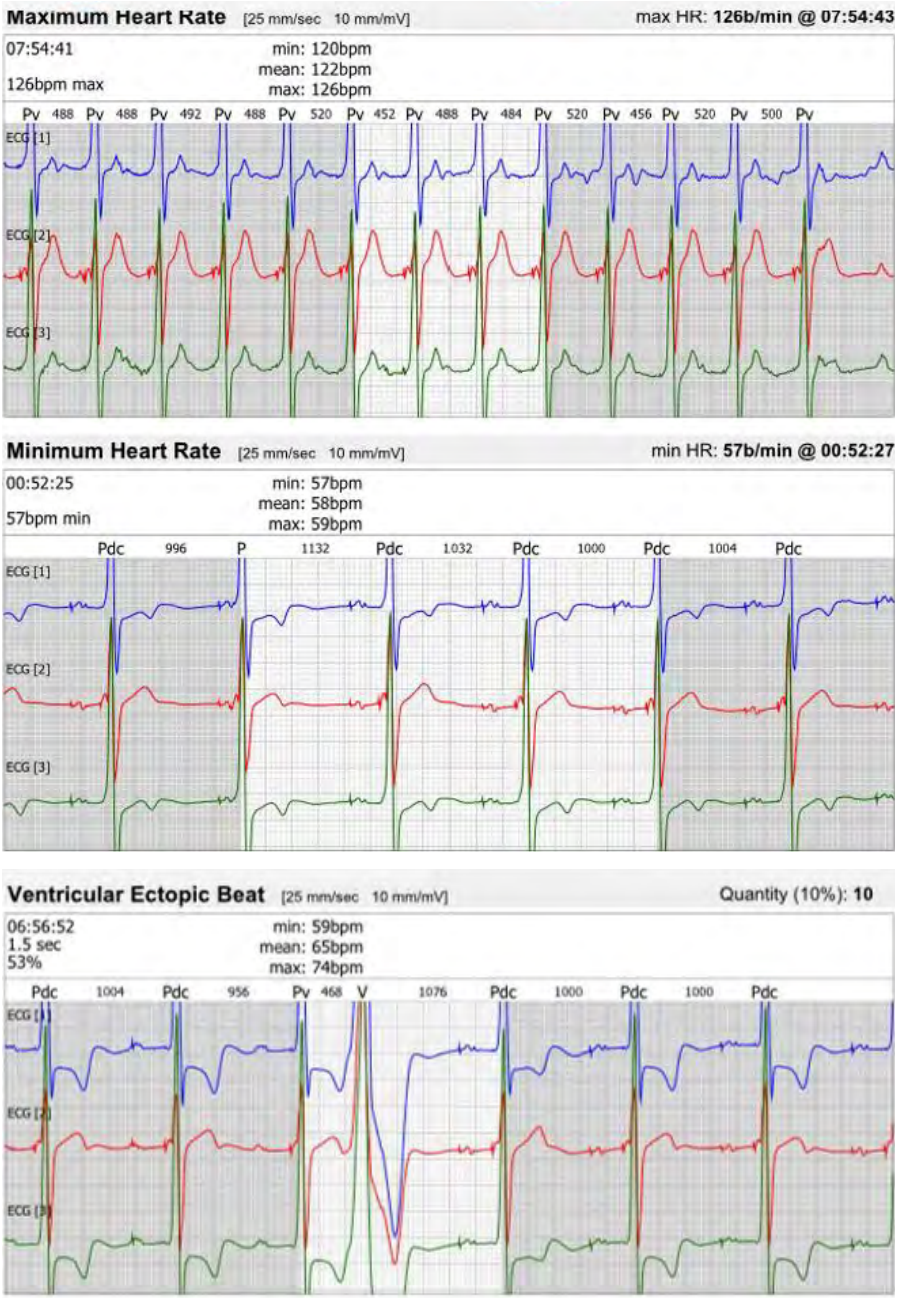
Maximum Heart Rate [25 mm/sec 10 mm/mV]
max HR: 126b/min @ 07:54:43
07:54:41
126bpm max
min: 120bpm
mean: 122bpm
max: 126bpm
Pv 488 Pv 488 Pv 492 Pv 488 Pv 520 Pv 452 Pv 488 Pv 484 Pv 520 Pv 456 Pv 520 Pv 500 Pv
ECG [1]
ECG [2]
ECG [3]
Minimum Heart Rate [25 mm/sec 10 mm/mV]
min HR: 57b/min @ 00:52:27
00:52:25
57bpm min
min: 57bpm
mean: 58bpm
max: 59bpm
Pdc 996 P 1132 Pdc 1032 Pdc 1000 Pdc 1004 Pdc
ECG [1]
ECG [2]
ECG [3]
Ventricular Ectopic Beat [25 mm/sec 10 mm/mV]
Quantity (10%): 10
06:56:52
1.5 sec
53%
min: 59bpm
mean: 65bpm
max: 74bpm
Pdc 1004 Pdc 956 Pv 468 V 1076 Pdc 1000 Pdc 1000 Pdc

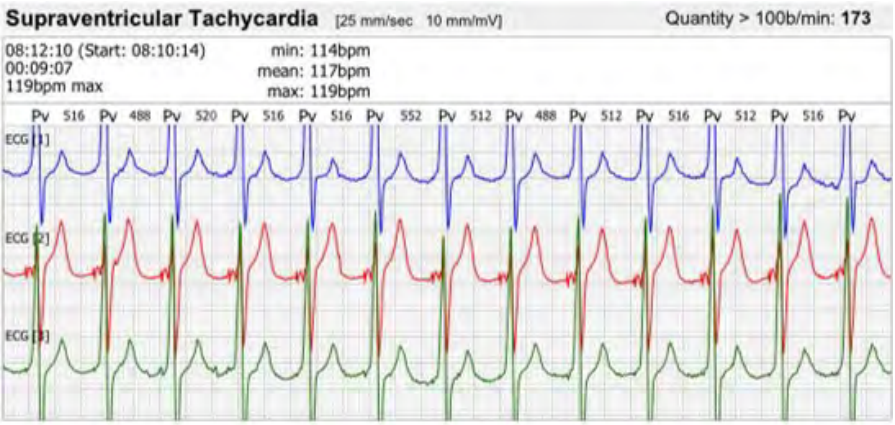

Follow-up 24-hour Holter after ERT (in February 2023) showed no new ventricular arrhythimia.

## *Cardiac echography*

Figure 35-36.

Cardiac echography after syncope episode while mountain climbing (in 2017) found mild LVH (thickness between 10 and 20 mm).

Figure 37-45.

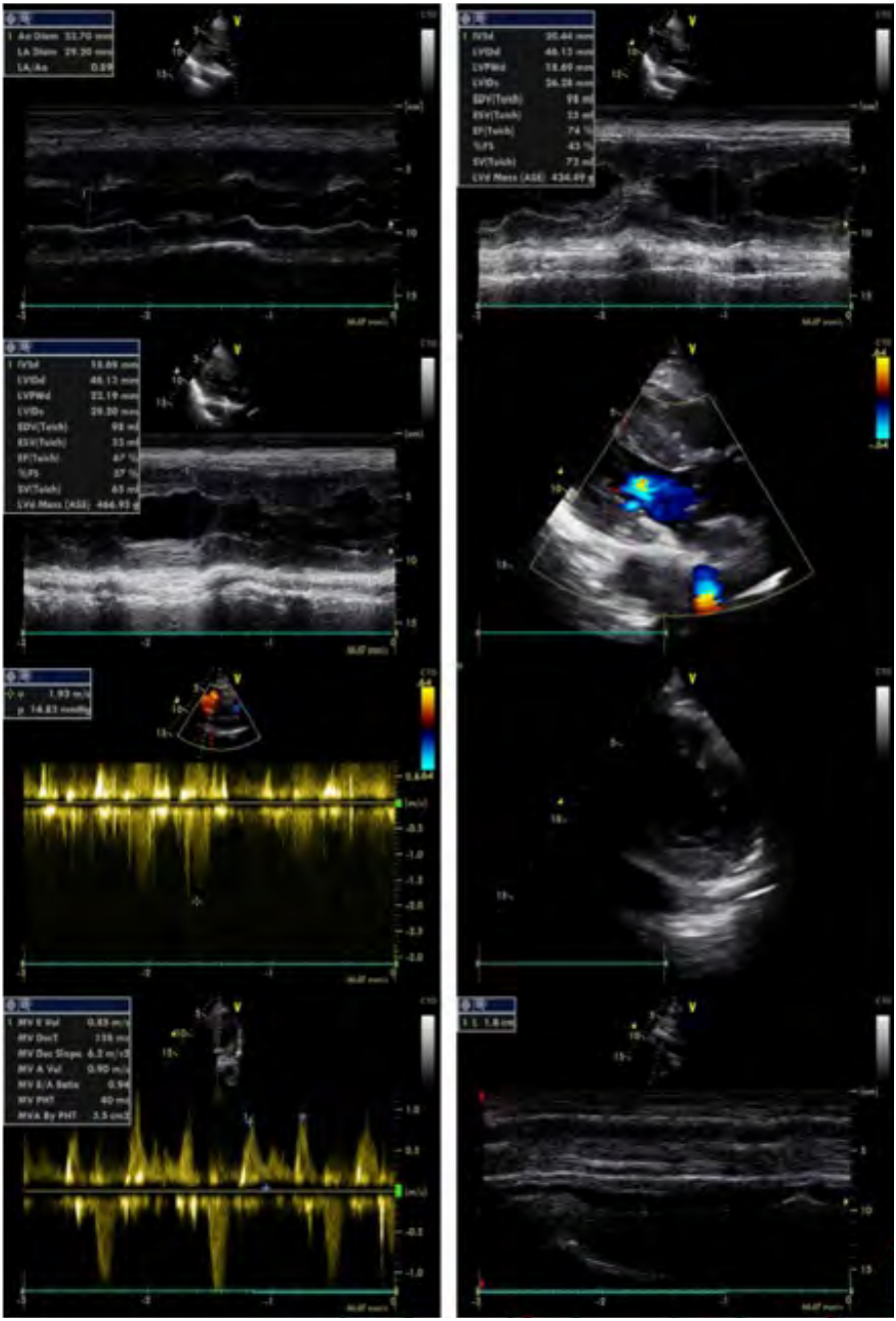

| Item | value |
|---|---|
| IVSd (mm) | 20.44 |
| LVIDd (mm) | 46.13 |
| LPWd (mm) | 18.69 |
| LVIDs (mm) | 26.28 |
| EF (%) | 74 |
| LVd Mass (gm) | 434.49 |

Cardiac echography after the first ROSC (in 2021)

- Marked concentric LVH with preserved systolic function; no trans-LVOT pressure gradient. Non-obstructive HCM is suspected.
- Further surveillance for possible infiltrative heart disease is needed, such as Fabry disease or transthyretin amyloidosis.

## Figure 46-53.

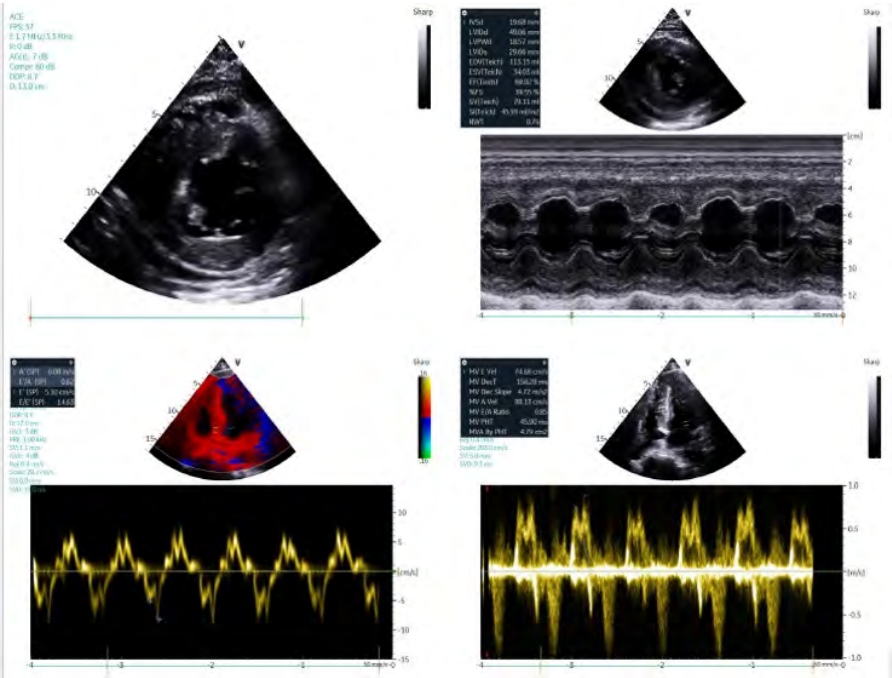

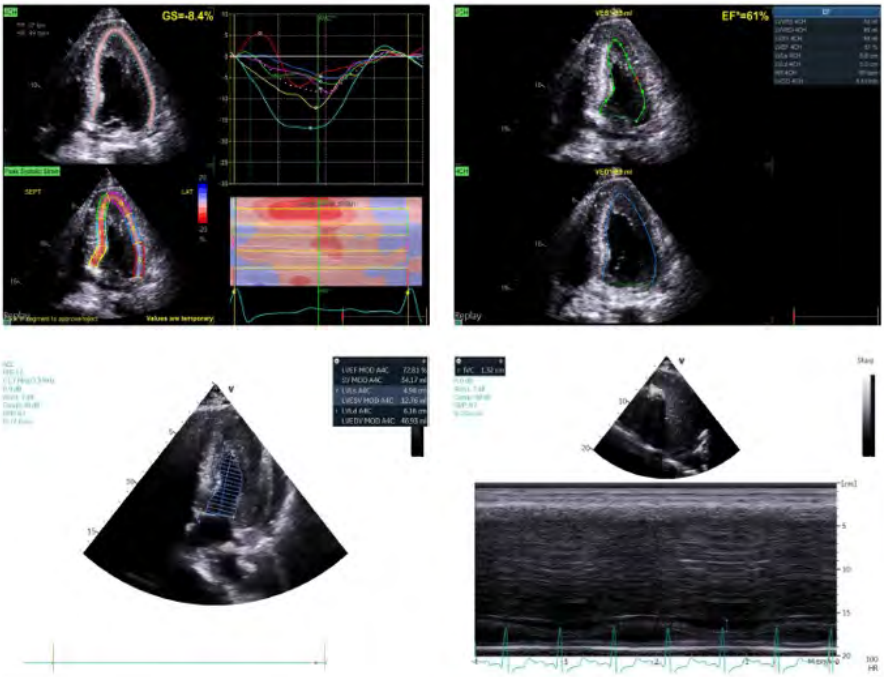


The results of follow-up cardiac echography 20 days after the first ROSC (in January 2022)

- Marked concentric LVH with normal left ventricular systolic function (EF 72%).
- No obvious trans-LVOT pressure gradient.
- Non-obstructive HCM was confirmed.

Figure 54-66.

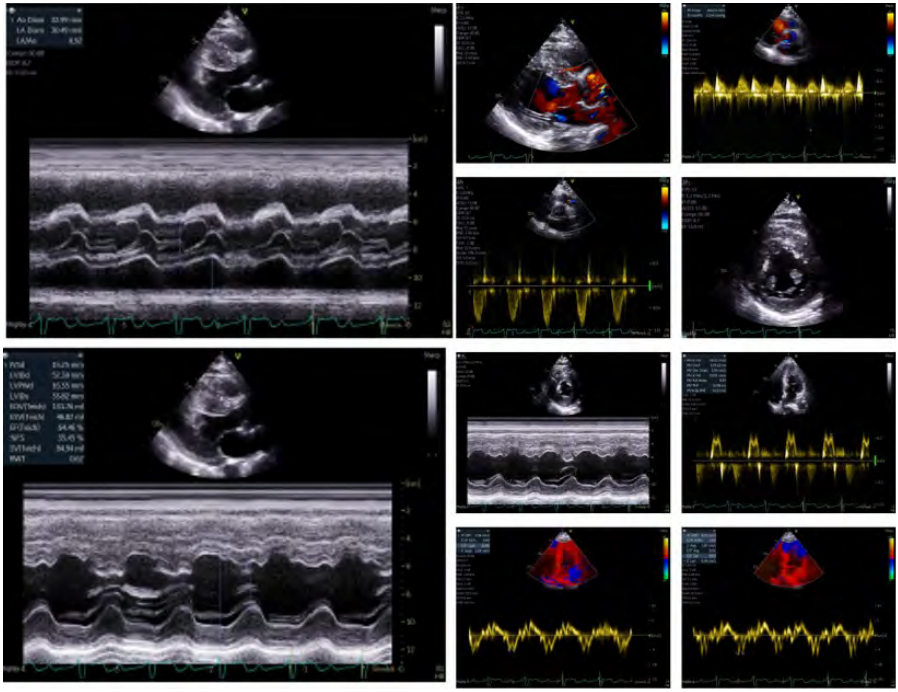

| Item | Feb.,2022 | Jun.,2022 | Feb.,2023 |
|---|---|---|---|
| IVSd (mm) | 20.44 | 17.2 | 15.7 |
| LVIDd (mm) | 46.13 | 53.9 | 50.7 |
| LPWd (mm) | 18.69 | 16.8 | 16.0 |
| LVIDs (mm) | 26.28 | 30.8 | 33.3 |
| EF (%) | 74 | 61 | 56 |
| LVd Mass (gm) | 434.49 | 435.4 | 357.65 |
| LVMi | 255.64 | 256.1 | 210.4 |

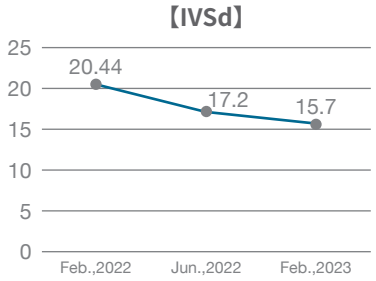


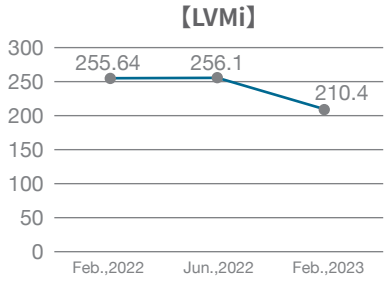


Follow-up cardiac echography after ERT and PPM implantation (in February 2023) revealed gradually decreasing left ventricular mass. The drop of IVSd thickness may be resulted from inter-observer variability.

## *Cardiac magnetic resonance imaging*

Figure 67-80.

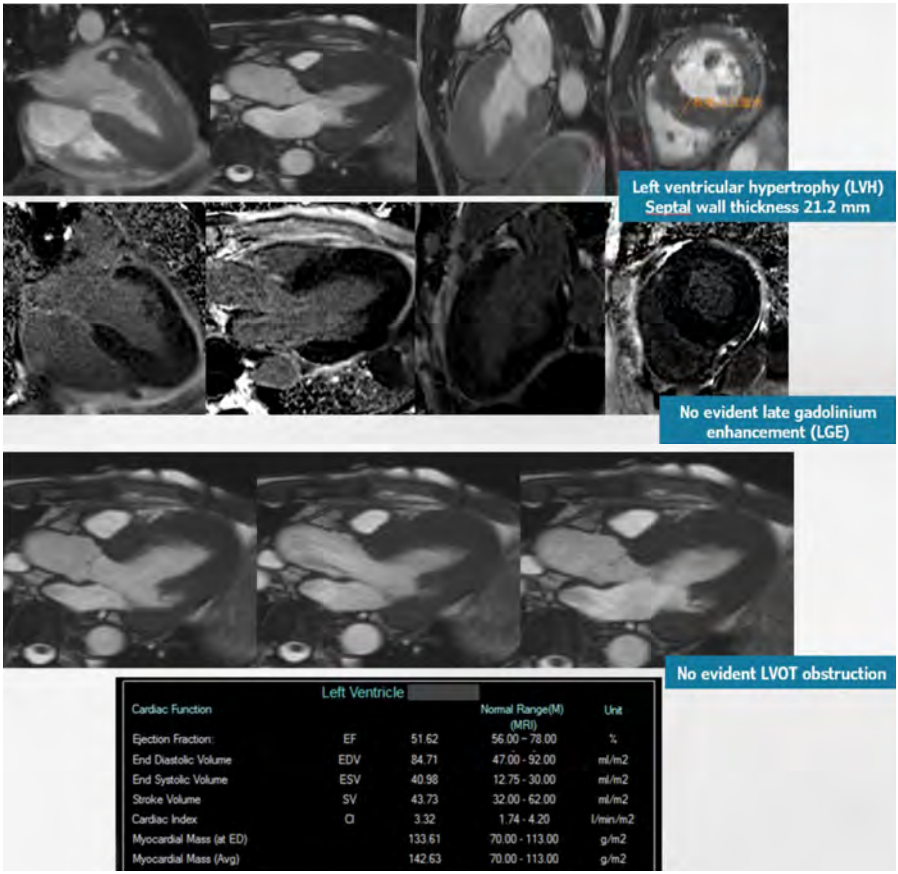


Left Ventricle

| Cardiac Function | | | Normal Range(M) (MRI) | Unit |
|---|---|---|---|---|
| Ejection Fraction: | EF | 51.62 | 56.00 – 78.00 | % |
| End Diastolic Volume | EDV | 84.71 | 47.00 - 92.00 | ml/m2 |
| End Systolic Volume | ESV | 40.98 | 12.75 - 30.00 | ml/m2 |
| Stroke Volume | SV | 43.73 | 32.00 - 62.00 | ml/m2 |
| Cardiac Index | CI | 3.32 | 1.74 - 4.20 | l/min/m2 |
| Myocardial Mass (at ED) | | 133.61 | 70.00 - 113.00 | g/m2 |
| Myocardial Mass (Avg) | | 142.63 | 70.00 - 113.00 | g/m2 |

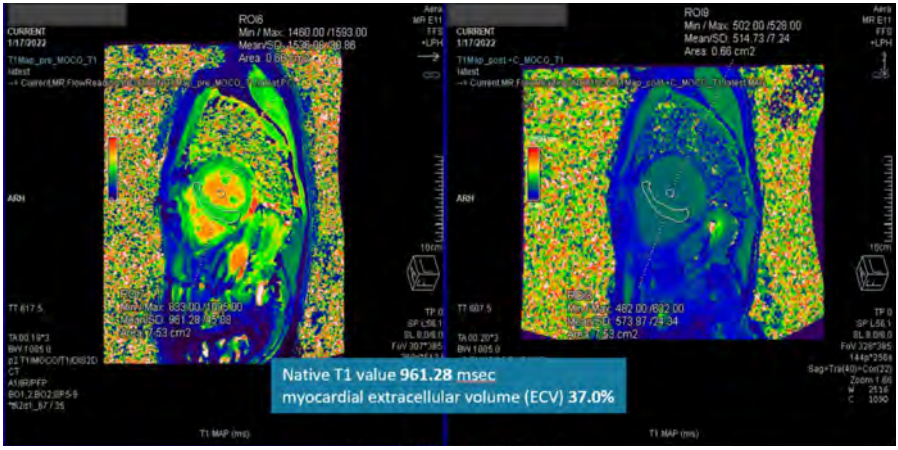


Cardiac MRI during the first admission (in January 2022)

- Hypertrophic change of left ventricular wall (septal wall thickness 21.2 mm, consistent with findings of cardiac echocardiography).
- No evidence of LGE or abnormal native T1 value (961 ms), ECV 37%.
- No evidence of LVOT obstruction, in favor of concentric HCM.

## *Coronary angiography*

Figure 81-86.

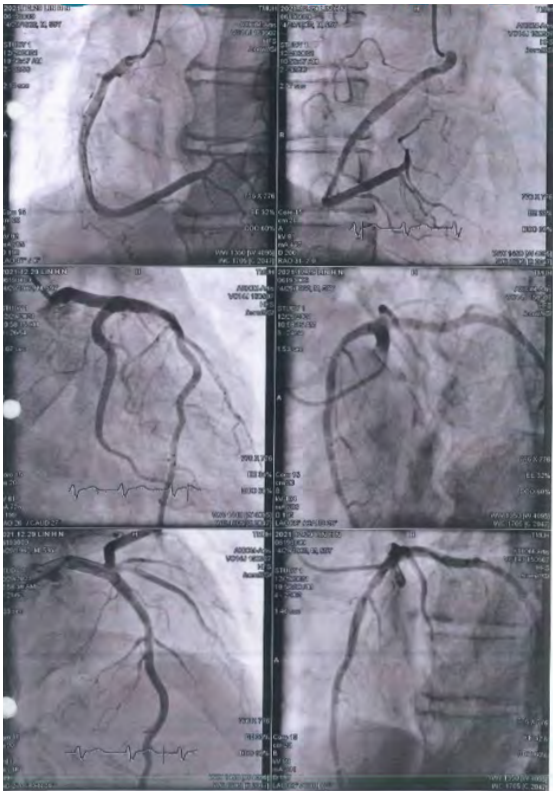

Coronary angiography after hypothermia therapy (in 2021) found no evidence of CAD.

## *Pedigree*

Figure 87.

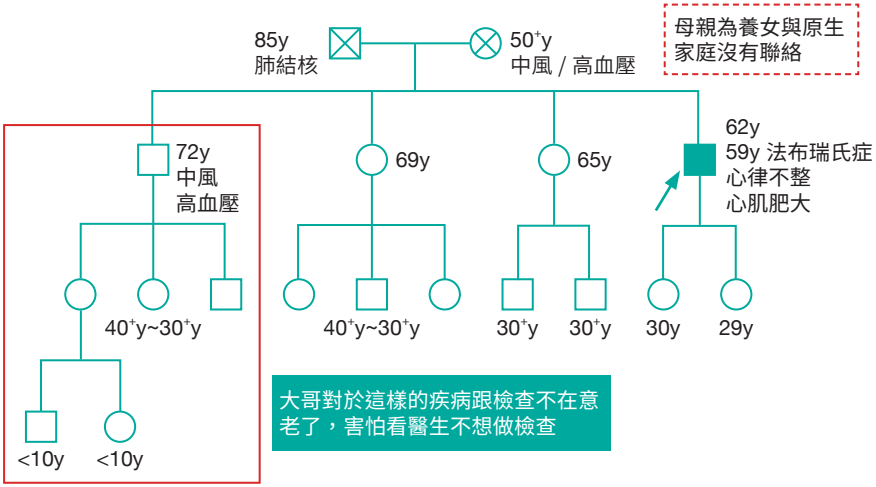


This patient's elder brother refused to undergo screening; thus, no further action was taken for this family.

## *Discussion*

- Early cardiac involvement in patients with Fabry disease usually presents as a conductive disorder or LVH. Late-onset sudden cardiac death in patients with Fabry disease as an initial presentation is very rare. However, the incidence of sudden cardiac death in Fabry disease may be underestimated due to misdiagnosis or delayed diagnosis.
- According to a systematic review, 75% of all mortalities due to Fabry disease result from cardiovascular problems, with the majority being sudden cardiac deaths (62% of reported deaths). The average prevalence of VT was 15.3%. Thus, although Fabry disease affects multiple systems in terms of mortality, death is mainly attributable to sudden cardiac events.
- Typical cardiac MRI characteristics suggestive of Fabry disease include a low native T1 value, which is the iconic feature to be differentiated from HCM or amyloidosis. LGE may be observed in the inferior, lateral, and basal areas, indicating fibrotic changes. However, in this patient, the T1 value was nearly normal and no LGE was found. Although 24-hour Holter and electrophysiological examinations could not determine the direct cause of this patient’s sudden cardiac death, it may have resulted from Fabry disease-related conduction dysfunction.
- Due to the rarity of this disease, the incidence of pacemaker implantation varies among studies. In the late-onset phenotype with predominant cardiac involvement, 12.7% of male patients required pacemaker implantation for conduction diseases.
- The patient’s initial clinical presentation of Fabry disease was a conduction problem with only mild concurrent LVH. A previous long-term observational study reported that not every patient with Fabry disease has LVH. While most males may develop LVH early in life, some female patients may never develop LVH but may still show positive results for LGE on cardiac MRI, indicating myocardial fibrosis, which may lead to diastolic dysfunction or conduction problems. Therefore, cardiologists should pay more attention to these high-risk groups and conduct Fabry disease screening as clinically indicated.
- Symptomatic VT, VF, and high-degree AV block are indications for PPM implantation. However, no VT or VF was observed in this patient, and the first documented AV block was possibly associated with CPR, making pacemaker implantation less preferable at that time. After the AV block was documented again following the patient’s collapse, which was more likely a spontaneous rhythm, PPM implantation was indicated.

## *References*


1. Nair V, Belanger EC, Veinot JP. Lysosomal storage disorders affecting the heart: A review. Cardiovasc Pathol. 2019; 39: 12–24.
2. Baig S, Edward NC, Kotecha D, Liu B, Nordin S, Kozor R, et al. Ventricular arrhythmia and sudden cardiac death in Fabry disease: A systemic review of risk factors in clinical practice. Europace. 2018; 20: f153–f161.
3. Chen JY, Lin CC. Late onset sudden cardiac death in Fabry disease. Kaohsiung J Med Sci. 2021; 37(1): 72–73.
4. Azevedo O, Cordeiro F, Gago MF, Miltenberger-Miltenyi G, Ferreira C, Sousa N, Cunha D. Fabry Disease and the Heart: A Comprehensive Review. Int J Mol Sci. 2021; 22(9): 4434.

# Fabry Disease Case Book

## Case 19:

A patient with Fabry disease with poor treatment adherence

王宇澄醫師

## *Clinical pearls*

- The onset and severity of symptoms may differ between males and females with classical Fabry disease.
- Family screening is critical for early diagnosis and treatment of Fabry disease.
- Treatment adherence is essential in patients with Fabry disease and is associated with symptom recurrence and severity.
- Reducing the patient's travel distance by implementing inter-professional collaborative practices between medical institutes may help improve treatment adherence.

## *Patient profile*

### Case presentation

- A 65-year-old female has had severe neuropathic pain (burning, tickling, and pricking over limbs) for over 30 years.
- Severe neuropathic pain-induced depression has also been reported to be associated with suicide attempts. However, the patient did not undergo examination nor received treatment for pain, except for painkillers from local clinics.
- The patient's son also experienced severe neuropathic pain at a young age. He suffered from drug abuse because of this non-relieving pain, sought help at Chang Gung Memorial Hospital, Linkou, and was diagnosed with Fabry disease.
- The patient was asked to undergo family screening, and the diagnosis of Fabry disease was confirmed in 2008.
- ERT was initiated after the diagnosis was confirmed in this patient, but she did not usually attend the infusion appointments as scheduled.
- Patient treatment adherence worsened, with a treatment rate of only 60% during the COVID-19 pandemic (June 2021 to April 2022). The main reasons were fear of COVID-19 infection in the medical institute and the long distance from her home (in Wufeng) to Linkou.
- Due to the loss of regular treatment, her neuropathic pain recurred, adversely impacting her emotions and quality of life.
- After the COVID-19 pandemic, the patient started to receive regular ERT infusions every other week at Asia University Hospital and attended the neurology clinic at Chang Gung Memorial Hospital, Linkou, to treat the neuropathic pain once

every two months. She also received ERT at Chang Gung Memorial Hospital.

- Her adherence to ERT improved to 100% after interprofessional collaborative practice between the Chang Gung and Asia University Hospitals, and her pain subsided after resuming ERT.

## Medical history other than Fabry disease

Hypertension and dyslipidemia, under medication control.

## *Laboratory panels*

### Figure 1.

| Systemic | Reference | 2013/1 | 2018/12 |
|---|---|---|---|
| Hb | 13-17 g/dL | | 13.1 |
| Plasma Lyso-Gb3 | <0.8 ng/ml | | **3.126** |
| a-GAL enzyme activity | 2.05-7.46 μmol/L/h | **1.44** | |
| GLA mutation | -- | **802-805 del TTAG, heterozygous** | |

Laboratory data obtained at Chang Gung Memorial Hospital

- The diagnosis of Fabry disease was confirmed by the presence of a heterozygous GLA mutation in 802-805 del TTAG.
- Lyso-Gb3 level was elevated in 2018.

### Figure 2-3.

| Renal | Reference | 2022 |
|---|---|---|
| eGFR | >60 mL/min/1.73m | 87 |
| UACR | <30 | 28.9 |
| **Cardiac** | **Reference** | **2022** |
| Troponin-T | <0.014 ng/mL | |
| NT-proBNP | <125 pg/mL | 265 |

Laboratory data in the first visit to Asia University Hospital (in 2022)

- eGFR within normal range; no proteinuria was noted.
- Slightly elevated NT-proBNP level; no cardiac symptoms.

## Figure 4-5.

| Systemic | Reference | 2022 | 2023 |
|---|---|---|---|
| Hb | 13-17 g/dL | 13.1 | 13.6 |
| SGPT | <40U/L | 19 | 21 |
| CPK | 30-223 U/L | 64 | 79 |
| Plasma Lyso-Gb3 | <2.6 ng/mL | **3.126(2018)** | **2.8** |
| Troponin-T | <0.014 ng/mL | | -- |
| NT-proBNP | <125 pg/mL | **265** | -- |
| **Renal** | **Reference** | **2022** | **2023** |
| Creatinine | 0.4-1.1mg/dl | 0.68 | 0.60 |
| eGFR | >60mL/min/1.73m | 87 | 100 |
| UACR | < 30ug/mg | 28.9 | 134.9 |

Follow-up laboratory data after receiving ERT at Asia University Hospital (in 2023)

- Elevated lyso-Gb3 level.
- Proteinuria may be related to Fabry disease or hypertension.

## *Chest radiograph*

Figure 6.

Chest radiograph on the first visit to Asia University Hospital (in 2022) showed borderline heart size.

## *Electrocardiography*

### Figure 7.

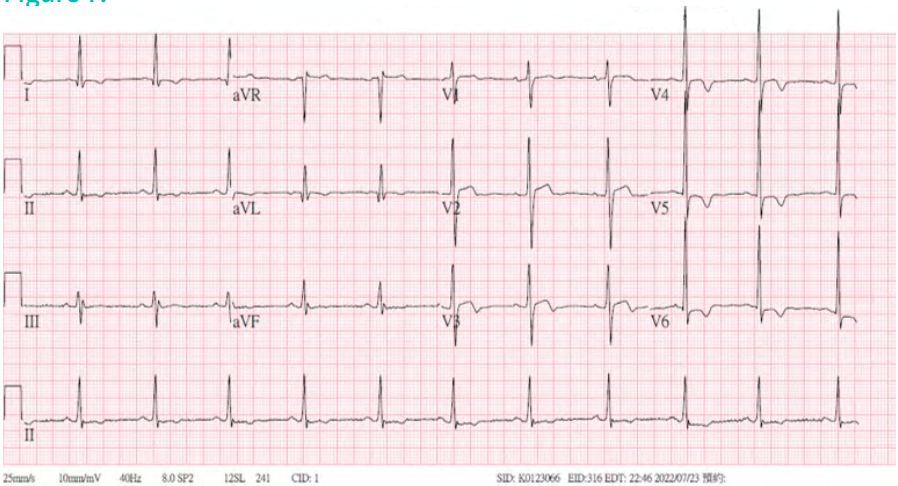


EKG on the first visit to Asia University Hospital (in 2022) revealed LVH voltage changes, inverted T waves, and a PR interval of 156 ms.

### Figure 8.

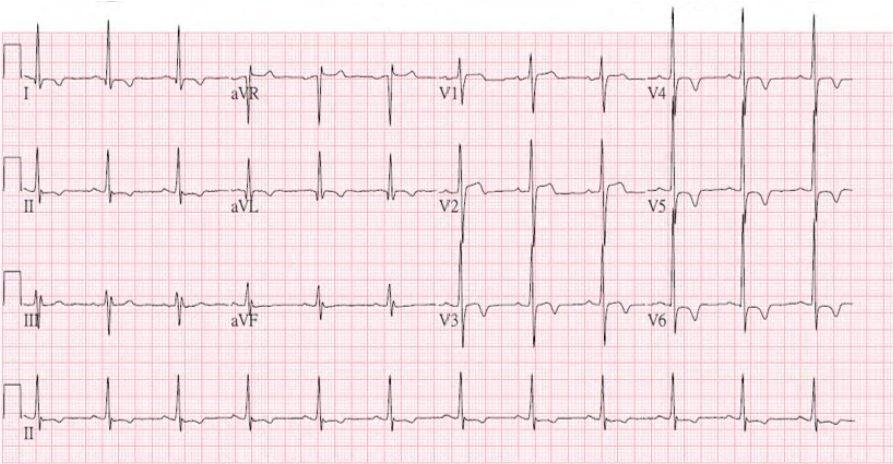


Follow-up EKG after receiving ERT in Asia University Hospital in 2023 showed similar morphology to 2022.

## *24-hour Holter*

### Figure 9.

| Heart Rate Data | |
|---|---|
| Total Beats | : 104072 |
| Min HR | : 54 BPM at 6:51:33 |
| Avg HR | : 72 BPM |
| Max HR | : 122 BPM at 12:31:11 |

| Heart Rate Variability | |
|---|---|
| ASDNN5 | : 38.9 msec |
| SDANN 5 | : 88.7 msec |
| SDNN | : 102.1 msec |

| ST Episode Analysis | | Ch1 | Ch2 | Ch3 |
|---|---|---|---|---|
| Min ST Level | : | - | - | - |
| Max ST Level | : | - | - | - |
| ST Episodes | : | - | - | - |

| Pacer Analysis | |
|---|---|
| Single Paced Beats | : - |
| Dual Paced Beats | : - |
| Fusion Beats | : - |

| Atrial Fibrillation | |
|---|---|
| AFib Beats | : 0 (0.0%) |
| Duration: 0.0 min | Events:0 |

| Ventricular Ectopy | |
|---|---|
| Total VE Beats | : 0 (0.0%) |
| Vent Runs | : 0 |
| Beats | : 0 |
| Longest | : 0 |
| Fastest | : 0 BPM |
| Triplets | : 0 Events |
| Couplets | : 0 Events |
| Single/Interp PVC | : 0/0 |
| R on T | : 0 |
| Single/Late VE's | : 0/0 |
| Bi/Trigeminy | : 0/0 Beats |

| Supraventricular Ectopy | |
|---|---|
| Total SVE Beats | : 106 (0.1%) |
| Atrial Runs | : 1 |
| Beats | : 4 |
| Longest | : 4 Beats at 23:19:57 |
| Fastest | : 146 BPM at 23:19:57 |
| Atrial Pairs | : 1 Event |
| Drop/Late | : 0/0 |
| Longest N-N | : 1.3 sec at 7:06:14 |
| Single PAC's | : 100 |
| Bi/Trigeminy | : 0/0 Beats |

24-hour Holter results in Chang Gung Memorial Hospital showed no long pause and no evidence of AV block.

## *Cardiac echography*

### Figure 10-13.

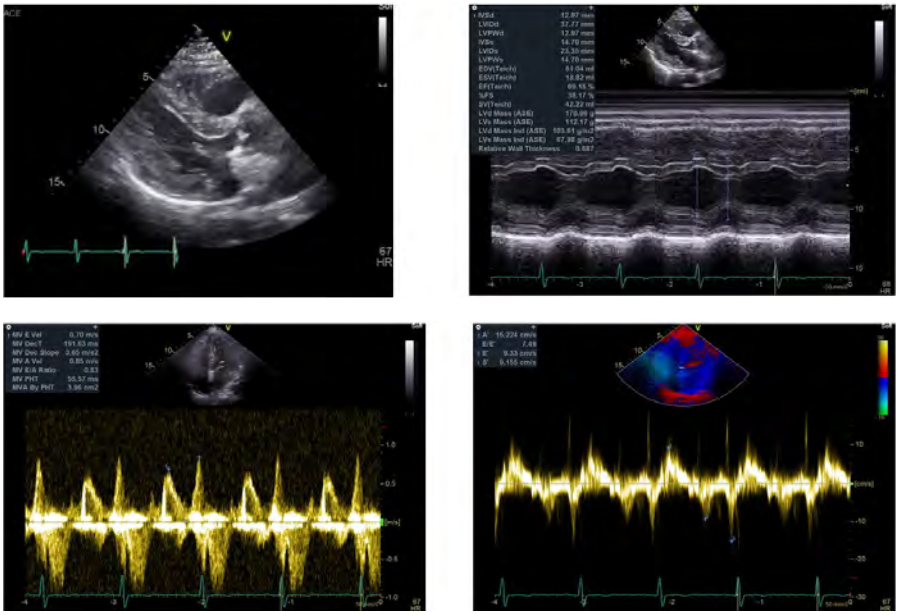

Cardiac echography in the first visit to Asia University Hospital (in 2022)

- Borderline concentric LVH with increased IVS thickness (13 mm) and increased left ventricular posterior wall thickness in diastole (13 mm).
- Mitral inflow: reverse E/A ratio; tissue Doppler: E/E’ :9.33.

## Figure 14-19.

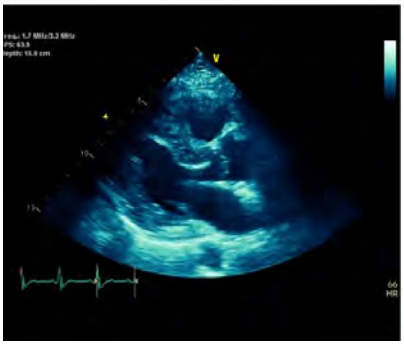

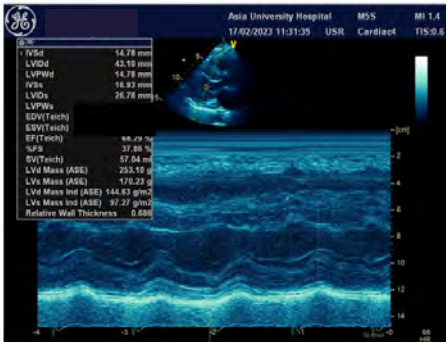


| Date | 112/02 |
|---|---|
| LV MASS (gm) | 253.15 |
| LVMI (g/m$^2$) | 144.57 |
| LVPWd (g/m$^2$) | 14.78 |
| IVSd (mm) | 14.78 |

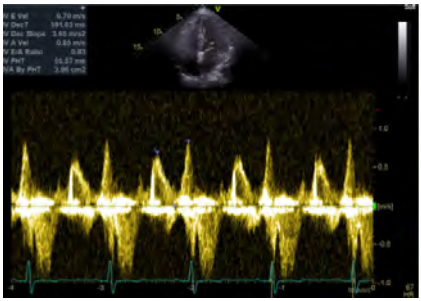

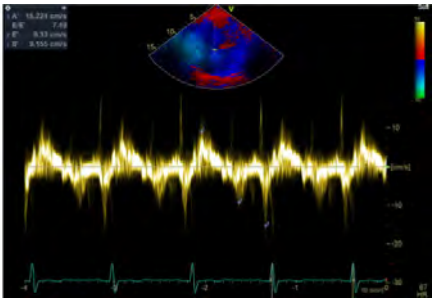

Follow-up EKG after receiving ERT at Asia University Hospital (in 2023)

- Mild increased septal wall thickness (13 to nearly 15 mm).
- Mitral inflow: reverse E/A ratio; tissue Doppler: E/E':19.63.

## *Pedigree*

Figure 20.

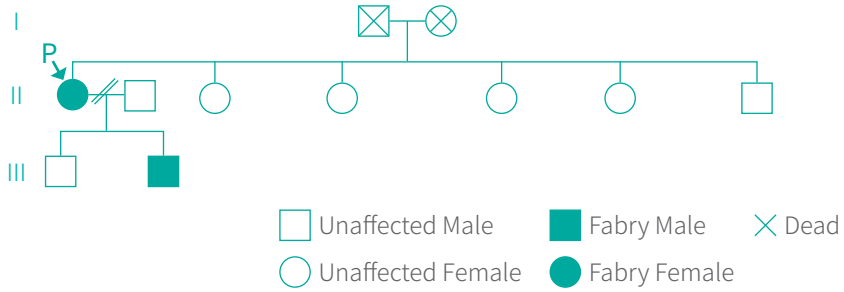


The patient's other son and her siblings were unwilling to undergo Fabry screening because they did not experience any clinical symptoms.

## *Discussion*

- This patient and her son were both diagnosed with classic Fabry disease resulting from the same mutation, but the onset time and severity of their clinical symptoms were different. According to a review article on sex differences presented by the Fabry Registry, signs in all organ systems occur earlier and more frequently in male patients, and their quality of life is significantly worse than that of female patients aged between 18 and 25 years. However, after the age of 25 years, the quality of life of women deteriorates rapidly, while that of male patients remains stable.
- Female patients with Fabry disease reported less pain at younger ages (12–40 years). With increasing age, female patients tended to report increasing scores of "worst pain in the past 24 hours".
- LVH and major cardiovascular events (including significant cardiac procedures, arrhythmia, angina, and congestive heart failure) occurred approximately ten years later in life in females than in males with Fabry disease. The accumulated event rates for any (renal, cardiac, and cerebrovascular) event in female patients gradually increased after the age of 40 years, while the accrued event rates in males started to grow at younger generations.
- Several studies have demonstrated the impact of the COVID-19 pandemic on adherence to therapy. One Turkish study that recruited 58 patients with Fabry disease found that approximately 40% of the patients did not receive ERT regularly during the pandemic because of fear of contagion in the hospital

(62.5%), inability to find a hospital for infusion (25%), and lack of or inability to obtain medication (12.5%). Another study analyzed all patients receiving ERT; the results indicated that 46% of ERT sessions were disrupted during COVID-19, 60% of whom adversely affected by ERT disruption, and two or more missing ERT doses could significantly worsen symptoms. Thus, in patients with Fabry disease, ERT adherence is critical and should be maintained to prevent symptom recurrence.

- This patient's GLA mutation was 802-805 del TTAG, which has been reported in a Korean study as a rare variant of Fabry disease. The four base pair deletion in exon six, with a resultant stop codon at the deletion site, leads to premature termination at the beginning of exon six. Migalastat may help improve patient treatment adherence to its oral formulation, but the amenability of this rare mutation has not been verified.
- Patients with Fabry disease may develop CAD accompanied by LVH. Considering the patient's EKG morphology, slightly elevated cardiac enzyme levels, age, and history of hypertension, further non-invasive evaluation for CAD may be indicated, although no symptoms are currently observed. Cardiac MRI may be used for the detailed surveillance of Fabry disease.

## *References*


1. Mol Genet Metab 93 (2008) 112–128.
2. Orphanet Journal of Rare Diseases 17 (2022) 38.
3. J Pediatr Endocrinol Metab 34 (2021) 539–545.
4. Clin Genet 58 (2000) 228–233.

# Fabry Disease Case Book

## Case 20:

A patient with arrhythmia

朱俊源醫師

## *Clinical pearls*

- Fabry disease is readily detected in high-risk patients. However, early diagnosis relies on screening every patient for symptoms suggestive of Fabry disease.
- Routine screening for Fabry disease is not warranted for all patients who undergo PPM implantation and has proven ineffective.
- When patients exhibit unexplained LVH combined with PPM implantation, Fabry disease should be considered as a potential differential diagnosis.
- Advanced age does not preclude the diagnosis of cardiac variant Fabry disease and should not be a determining factor in the decision to decline ERT.

## *Patient profile*

### Case presentation

- An 80-year-old male with diabetes mellitus, hypertension, and a history of sick sinus syndrome and underwent PPM implantation at another hospital.
- The patient presented our cardiology clinic owing to dyspnea on exertion that persisted for several years and general malaise for one year.
- Based on echocardiography findings, there was a high suspicion of HCM. Consequently, Fabry disease screening was conducted, leading to the diagnosis of a cardiac variant of Fabry disease.
- Morphological analysis of an endomyocardial biopsy revealed characteristics consistent with lysosomal storage disease. Electron microscopy revealed intracytoplasmic inclusion bodies (myelin-like figures and zebra bodies), consistent with Fabry disease.
- Following a comprehensive evaluation of Fabry disease, ERT was approved and initiated in July 2021. Initially, the infusion time exceeded four hours but gradually reduced to one and a half hours within approximately six months.
- After two years of treatment, follow-up assessments, including six-minute walk distance and echocardiography, demonstrated improved exercise tolerance and sustained EF. No additional APC but rare VPCs were recorded during a 24-hour Holter monitoring following ERT.
- The patient’s lyso-Gb3 levels became undetectable after ERT initiation, with no evidence of renal function decline or elevation of cardiac enzymes.
- The patient exhibited good adherence to ERT, and was concurrently prescribed furosemide, valsartan, nebivolol, aspirin, dapagliflozin, amiodarone, and

rosuvastatin, which effectively managed diabetes mellitus, hypertension, HFpEF, and arrhythmia.

## Physical examination (in October 2020)

- Body weight: 81.9 kg
- Height: 160.5 cm
- BMI: 31.79 kg /$m^2$
- Blood pressure: 100 /64 mmHg
- Pulse: 66 /min

## *Laboratory panels*

### Figure 1—4.

| 項目 | 檢體 | 結果值 | 單位 |
|---|---|---|---|
| 收到檢體 | Blood | 1091015 10:9 | |
| WBC | Blood | 10.21 | x1000/uL |
| RBC | Blood | 5.05 | x10^6/uL |
| Hgb | Blood | 14.3 | g/dL |
| Hct | Blood | 44.0 | % |
| MCV | Blood | 87.1 | fl |
| MCH | Blood | 28.3 | Pg |
| MCHC | Blood | 32.5 | g/dL |
| PLT | Blood | 257 | x1000/uL |
| **RDW-CV** | **Blood** | **15.9** | **%** |
| 收到檢體 | Blood | 1091015 10:28 | |
| U-CRE | Urine | 284.16 | mg/dL |
| MicroALB | Urine | 1.0 | mg/dL |
| 收到檢體 | Blood | 1091015 10:19 | |
| GLU(AC) | Blood | 107 | mg/dL |
| GPI(ALT) | Blood | 22 | IU/L |
| Uric acid | Blood | 6.8 | mg/dL |
| **Creatinine** | **Blood** | **1.58** | **mg/dL** |
| K | Blood | 3.8 | m mo/dL |
| CHOL(T) | Blood | 157 | mg/dL |
| **TG** | **Blood** | **301** | **mg/dL** |
| HDL-C | Blood | 35.6 | mg/dL |
| LDL-C | Blood | 55.7 | mg/dL |
| 低密度脂蛋白膽固醇 ( 估算值 ) | Blood | 61.2 | mg/dL |
| 收到檢體 | Blood | 1091015 10:19 | |
| **HbA1C** | **Blood** | **6.6** | **%** |
| CRP( 定量 ) | Blood | 1.58 | mg/dL |
| 收到檢體 | Blood | 1091015 10:19 | |
| BNP | Blood | 71.0 | mg/dL |

Laboratory data at the first visit (in October 2020) indicating mildly elevated creatinine, triglyceride, and HbA1c levels.

## Figure 5—7.

| Test Item | Result | Reference |
|---|---|---|
| ( 限男性 )<br>法布瑞氏症篩檢<br>( 限 7 歲以上使用 ) | 1.23 | Normal > 1.5 μmol/hr;<br>Borderline: 0.6 ~1.5 μmol/hr; 陽性 < 0.6 μmol/hr |

| Test Item | Result | Unit | Reference |
|---|---|---|---|
| Plasma Lyso-Gb3 | 3.61 | ng/mL | N < 0.80 ng/mL |

| 突變區域序列圖譜 | 基因型 |
|---|---|

GTTACCATGTCTTCCCCACTAAAGTGTAAGTTTCATGAGGGC

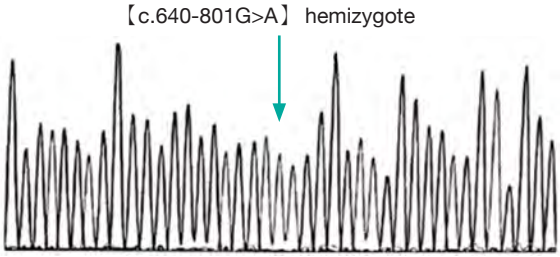


【c.640-801G>A】 hemizygote

IVS4 cardiac Fabry disease diagnosed by lower GAL enzyme activity, increased lyso-Gb3 level, and positive results for IVS4 c.640-801G>A mutation.

## Figure 8.

| | | | |
|---|---|---|---|
| Plasma Lyso-Gb3 | N/A | ng/mL | N < 0.80 |
| Plasma Lyso-GL1 | N/A | ng/mL | N < 3 |
| Plasma Lyso-SM | N/A | ng/mL | N < 8 |

After two years of ERT, the patient’s lyso-Gb3 became undetectable in March 2023.

## Figure 9.

| | 2023/02/27 09:20 | 2022/12/05 08:52 | 2022/05/09 09:56 | 2022/03/07 09:44 |
|---|---|---|---|---|
| Urea N | 20.3 | | **23.5** | |
| Creatinine | **1.42** | | **1.44** | |
| NTproBNP | | 395.3 | | |
| BNP | | | 83.0 | 74.3 |
| CRP（定量） | | | | |

| | 2022/03/07 09:43 | 2021/03/24 15:19 | 2021/01/18 15:22 | 2020/10/15 10:19 |
|---|---|---|---|---|
| Urea N | | **28.9** | **22.6** | |
| Creatinine | | **1.41** | **1.53** | |
| NTproBNP | | | | |
| BNP | | | | 71.0 |
| CRP（定量） | **5.55** | | | 1.58 |

Neither renal function progression nor elevation of cardiac enzymes was observed.

## *Chest radiograph*

Figure 10.

Chest radiography at the first visit (in October 2020) showing well implanted PPM.

## *Electrocardiography*

Figure 11.

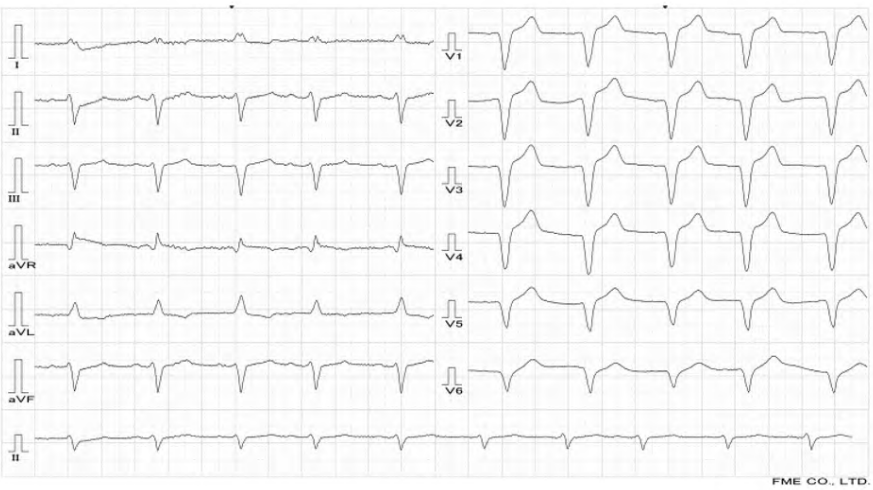


EKG at the first visit (in October 2020) showing pacemaker beats, with no specific findings.

## *24-hour Holter*

Results in January 2021:

- Pacemaker rhythm with a ventricular rate of 55-92/min, with a mean rate of 66/min.
- Moderate to frequent APCs (1208 in total), including repetitive APCs.
- Occasional VPCs (104 in total) with a multiform pattern.
- Pauses exceeding 2.0 s were not observed.
- No entries indicating symptoms were documented in patient’ s diary.

Results in March 2023:

- Pacemaker rhythm with ventricular a rate of 60-110/min and mean rate of 64/min.
- No APCs.
- Rare VPCs (seven in total) with multiform and ventricular couplet.
- No pauses longer than 2.0 s.
- No entries regarding symptoms were documented in the patient’ s diary.

## *Echocardiography*

Figure 12—18.

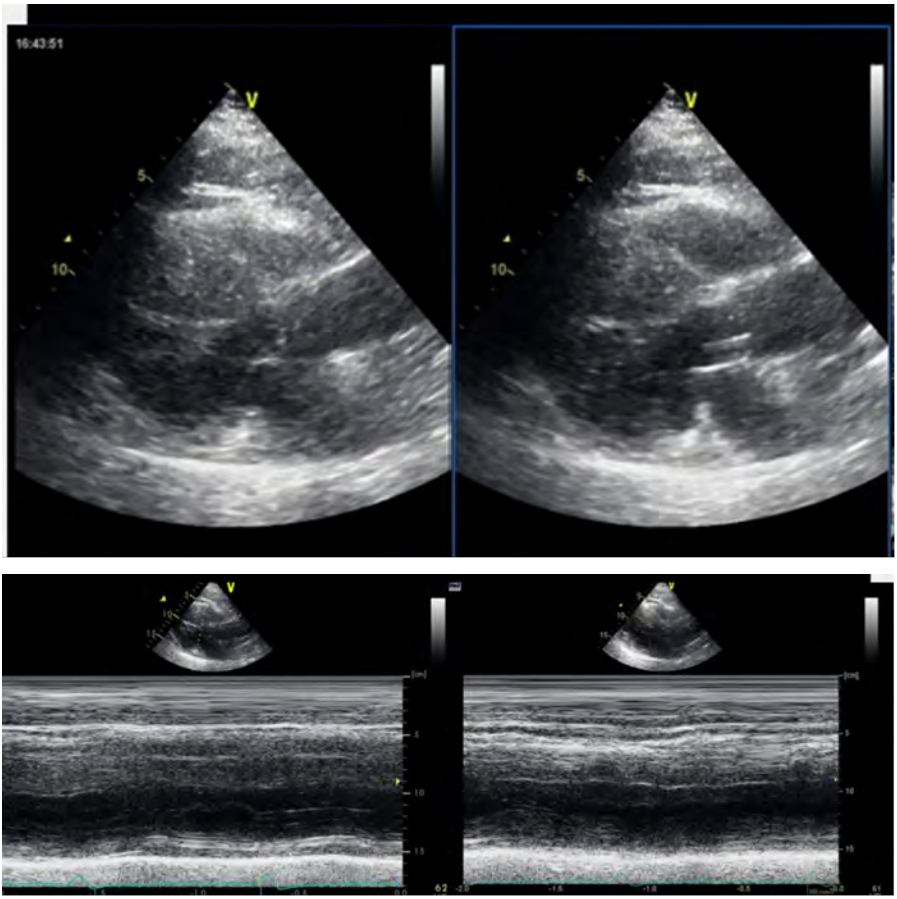

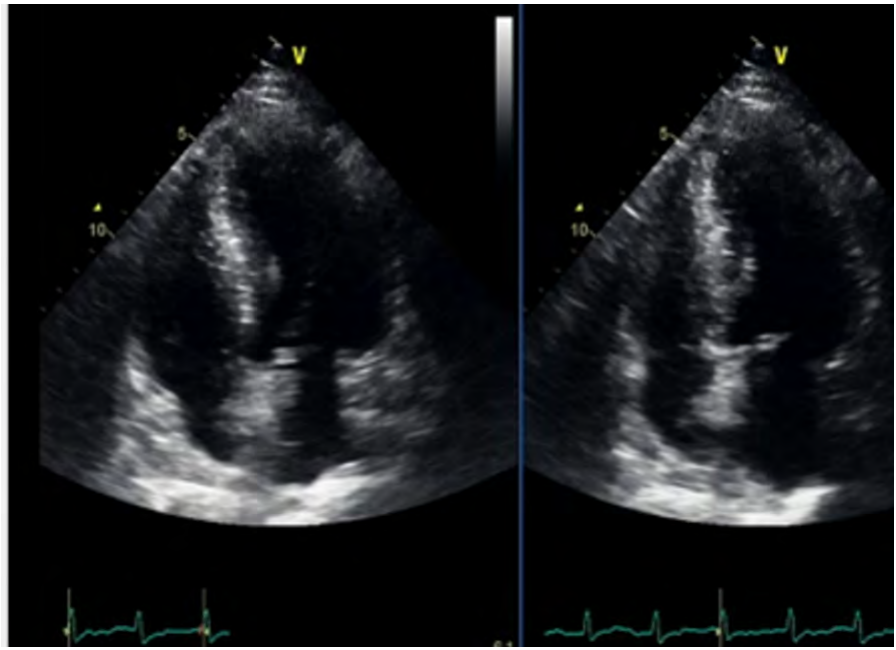
V
5
10
V
5
10

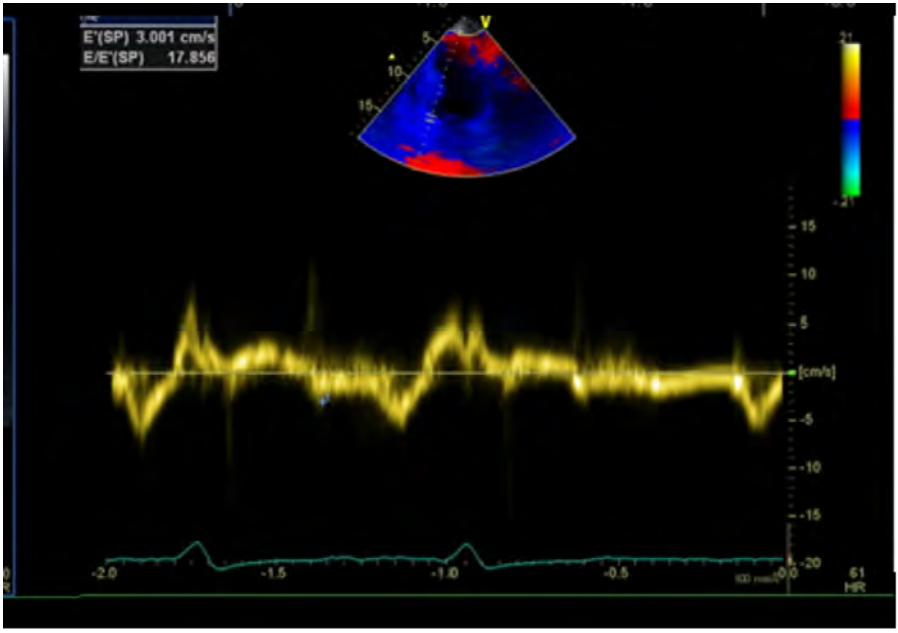
E'(SP) 3.001 cm/s
E/E'(SP) 17.856
V
5
10
15
15
10
5
[cm/s]
-5
-10
-15
-20
-2.0
-1.5
-1.0
-0.5
0.0
61
HR

Echocardiography at the first visit (in October 2020)

- HCM was highly suspected.
- Diastolic dysfunction.
- Mild aortic regurgitation.

Figure 18—19.

Echocardiographic findings in October 2020

| 2D | | | | |
|---|---|---|---|---|
| | **M-Mode** | | **Doppler** | |
| | Ao Diam | 3.32cm | MV E Vel | 0.54m/s |
| | LA Diam | 4.36cm | MV DecT | 320.91ms |
| | AV Cusp | 2.09cm | MV Dec Slope | 1.67m/s² |
| | LA/Ao | 1.31 | | |
| | Ao/LA | 0.76 | MV A Vel | 0.90m/s |
| | RVIDd | 1.53cm | MV E/A Ratio | 0.60 |
| | IVSd | 2.98cm | MV PHT | 93.06ms |
| | LVIDd | 4.96cm | MVA By PHT | 2.36cm² |
| | LVPWd | 1.16cm | IVRT | 152.25ms |
| | IVSs | 3.28cm | E'(SP) | 3.001cm/s |
| | LVIDs | 3.65cm | E/E'(SP) | 17.856 |
| | LVPWs | 2.24cm | E'(LW) | 2.836cm/s |
| | EDV(Teich) | 115.87ml | E/E'(LW) | 18.890 |
| | ESV(Teich) | 56.34ml | AV Vmax | 1.91m/s |
| | EF(Teich) | 51.37% | AV maxPG | 14.57mmHg |
| | %FS | 26.32% | | |
| | SV(Teich) | 59.52ml | | |
| | LVd Mass Index | 346.87g/m² | | |
| | LVs Mass Index | 398.42g/m² | | |

## Echocardiographic findings in March 2023

| 2D | | M-Mode | | Doppler | |
|---|---|---|---|---|---|
| | | Ao Diam | 3.20cm | MV E Vel | 0.83m/s |
| | | LA Diam | 4.40cm | MV DecT | 327.61ms |
| | | AV Cusp | 2.05cm | MV Dec Slope | 2.53m/s² |
| | | LA/Ao | 1.37 | | |
| | | Ao/LA | 0.73 | MV A Vel | 1.07m/s |
| | | RVIDd | 2.09cm | MV E/A Ratio | 0.77 |
| | | IVSd | 1.98cm | MV PHT | 95.01ms |
| | | LVIDd | 4.77cm | MVA By PHT | 2.32cm² |
| | | LVPWd | 1.12cm | IVRT | 175.32ms |
| | | IVSs | 2.53cm | E'(SP) | 3.395cm/s |
| | | LVIDs | 3.28cm | E/E'(SP) | 24.453 |
| | | LVPWs | 1.79cm | E'(Avg) | 3.723cm/s |
| | | EDV(Teich) | 105.97ml | E/E'(Avg) | 22.296 |
| | | ESV(Teich) | 43.47ml | E'(LW) | 4.052cm/s |
| | | EF(Teich) | 58.98% | E/E'(LW) | 20.488 |
| | | %FS | 31.25% | E'(Avg) | 3.723cm/s |
| | | SV(Teich) | 62.50ml | E/E'(Avg) | 22.296 |
| | | LVd Mass | 379.17g | AV Vmax | 1.72m/s |
| | | LVs Mass | 406.70g | AV Vmean | 0.89m/s |
| | | LVd Mass Index | 198.52g/m² | AV maxPG | 11.83mmHg |
| | | | | AV meanPG | 4.92mmHg |

After two years of ERT, marked improvement of IVSd were observed; however, a deteriorated diastolic function was found.

## *Cardiac magnetic resonance imaging*

Figure 20.

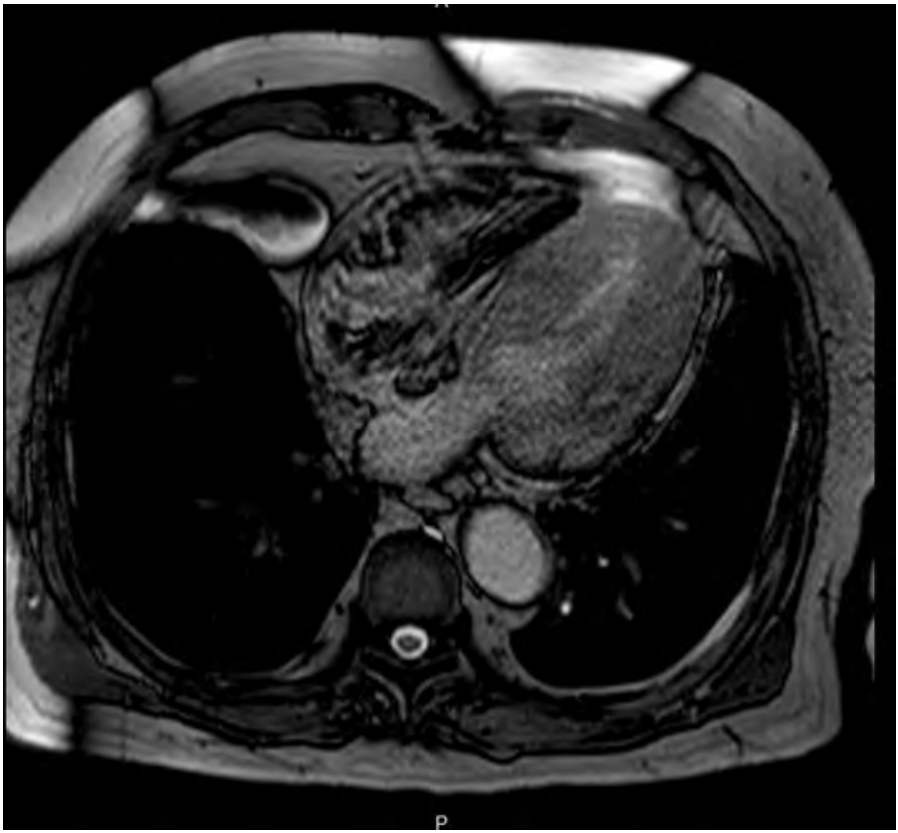


Cardiac MRI in February 2021 indicating marked LVH. However, no other available information due to technical problems.

## Figure 21

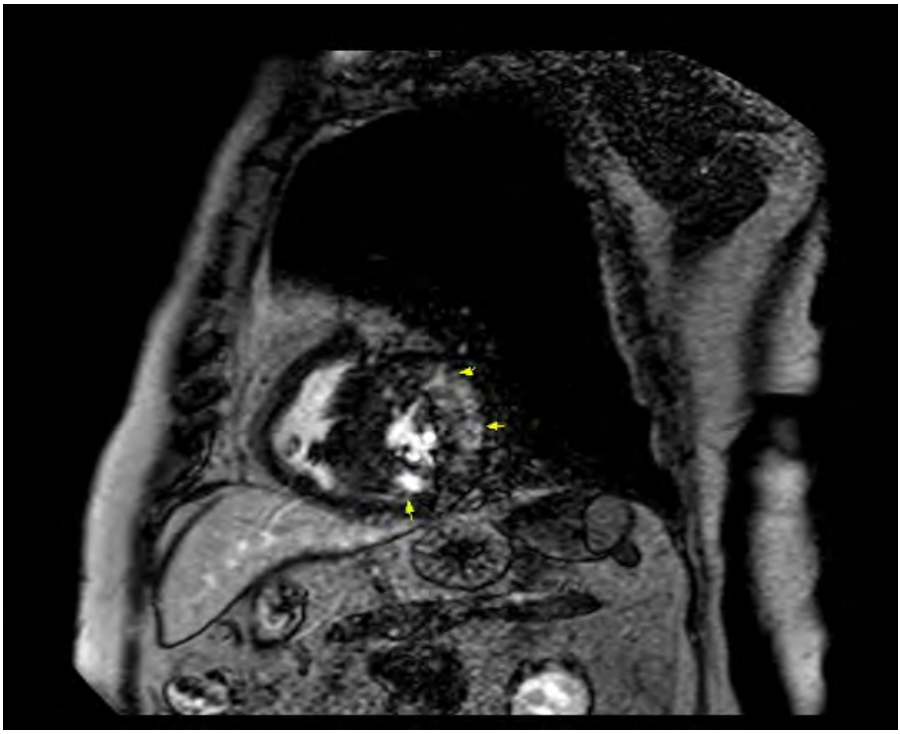

Cardiac MRI in March 2023

- Delayed enhancement with scar formation at the mid-wall of the lateral wall from the basal to the apex, and at the mid-wall of the inferior wall from the mid-to-basal region of the left ventricle.
- The left ventricular EF was 47.1%.

## *Six-minute walk distance*

### Figure 22.

| | HR | SpO2 | Borg scale | BP | FiO2 |
|---|---|---|---|---|---|
| Rest | 91 | 94 | 1 | 158/92 | 21% |
| 1st min | 97 | 93 | 2 | | 21% |
| 2nd min | 100 | 93 | 3 | | 21% |
| 3rd min | 101 | 92 | 4 | | 21% |
| 4th min | 100 | 92 | 4 | | 21% |
| 5th min | 101 | 94 | 4 | | 21% |
| 6th min | 101 | 92 | 4 | | 21% |
| 7th min | 96 | 93 | 3 | | 21% |
| 8th min | 91 | 92 | 1 | 119/64 | 21% |
| Target distance(LLN): | | 363.85 | meters | Pred: | 19.51 |
| 實際行走距離 : | | 71 | meters | Submaximal HR:140 | |
| 行走速率 : | | 0.2 | m/sec | 行走功率 :0.87 | |
| distant saturation production: | | 71 | (m)* 92% = 65.32 | | |
| $SpO_2$<85%: | | 0 | SpO2<90%: 0% | | |
| 使用輔具： ■有 □無 | | | | | |
| 提早終止原因及次數 ( 含休息時間 ): | | | | | |

The six-minute walk distance in January 2021 was relatively poor compared to the patient's age.

Figure 23.

| | HR | BP | RPE | Borg scale | SpO2 | FiO2 |
|---|---|---|---|---|---|---|
| Rest | 61 | 115/75 | 11 | 0.5 | 97 | |
| 4th min | | | | | | |
| 7th min | 69 | 131/53 | 13 | 5 | 97 | |
| Target distance(LLN): | | 259.48 | meters | Pred:30.83% | | |
| 實際行走距離： | | 80 | meters | Submaximal HR: | | |
| 行走速率： | | 0.22 | m/sec | | | |
| 使用輔具： □有 ■無 | | | | | | |
| 提早終止原因及次數 ( 含休息時間 ): | | | | | | |
| ■ dyspnea □ desaturation ■ leg fatigue □ chest pain | | | | | | |

The six-minute walk distance in June 2023 was still poor, but a 12.6% increase was observed after two years of ERT.

## *Discussion*

- According to the article on the diagnosis and evaluation of HCM from the Journal of American College of Cardiology, when HCM is highly suspected, a comprehensive assessment is necessary. This includes EKG, echocardiography, and cardiac MRI to identify the HCM phenotype. Genetic testing may also play a crucial role in excluding certain diseases, such as Fabry disease. Consequently, this patient was screened for Fabry disease.
- Given the elevated prevalence of cardiac variant Fabry disease in Taiwan, genetic screening for all patients with HCM may be considered. However, based on our local data, a consensus has been reached that among patients with HCM, genetic screening for Fabry is strongly recommended for males aged ≥ 40 years and females aged ≥ 50 years.
- Based on the European criteria for the initiation of ERT, patients with non-classic Fabry disease with septal thickness > 12 mm with or without fibrosis or with arrhythmias are eligible for ERT initiation. Thus, the patient in this case underwent ERT.
- In Fabry disease, bradycardia and conduction system abnormalities stem from the abnormal accumulation of glycolipids in the lysosomes of conduction tissues. Hypertrophy and eventual fibrosis create a substrate for persistent conduction abnormalities and ventricular arrhythmias. ERT has demonstrated

its ability to enhance cardiac function and clinical outcomes. In patients with Fabry disease at risk of arrhythmias, the use of pacemakers or defibrillators is pivotal.

- One study involving 82 patients with Fabry disease, revealed that after a median follow-up of 6.9 years, five (6%) patients required PPM implantation. Indications included sick sinus syndrome and advanced AV block. Conversely, another study that screened 484 patients with PPM implantation in the Czech Republic found that 481 (99%) were negative for Fabry disease, suggesting that routine screening for Fabry disease was not required.
- A case reported by the National Cheng Kung University Hospital presented with initial symptoms of palpitations and concentric LVH. Subsequently, the patient developed a 3:1 AV block after eight years. Although pacemaker implantation was performed, the patient’s EF continued to deteriorate. Ultimately, more than a decade after the initial symptoms, the patient was diagnosed with Fabry disease. This case underscores the importance of considering Fabry disease in the differential diagnosis of elderly patients with unexplained LVH, especially after excluding hypertensive heart disease, valvular heart disease, and obesity; other causes such as familial HCM and amyloidosis should also be included in the differential diagnosis.

## *References*


1. Maron BJ, et al. J Am Coll Cardiol. 2022;79(4):372-89.
2. Card Electrophysiol Clin. 2015;7(2):283-91.
3. J Cardiovasc Electrophysiol. 2022;33(5):1072-8.
4. Int J Cardiol. 2023;372:71-5.
5. Yu TP and Chen JY. J Clin Med. 2022;11(12):3522.

## Abbreviations

| | |
|---|---|
| 6 MWT | 6-minute walk test |
| **A** | |
| ACEI | angiotensin converting enzyme inhibitor |
| ACR | albumin-to-creatinine ratio |
| ACS | acute coronary syndrome |
| ADA | anti-drug antibodies |
| Af | atrial fibrillation |
| AHA | American Heart Association |
| APC | atrial premature contraction |
| ARB | angiotensin II receptor blocker |
| AV | atrioventricular |
| **B** | |
| BMI | body mass index |
| BNP | B-type natriuretic peptide |
| BUN | blood urea nitrogen |
| **C** | |
| CAD | coronary artery disease |
| CCB | calcium channel blocker |
| CKD | chronic kidney disease |
| CK-MB | creatinine kinase MB |
| COVID-19 | coronavirus disease 2019 |
| CPK | creatine-phospho-kinase |
| CPR | cardiopulmonary resuscitation |
| Cr | creatinine |
| CT | computed tomography |
| **D** | |
| DBS | dried blood spot |
| DOAC | direct oral anticoagulant |
| **E** | |
| ECV | myocardial extracellular volume |
| EF | ejection fraction |
| eGFR | estimated glomerular filtration rate |
| EKG | electrocardiography |
| ERT | enzyme replacement therapy |
| ESRD | end-stage renal disease |
| **F** | |
| FOS-MSSI | Fabry Outcome Survey Adaptation of the Mainz Severity Score Index |
| **G** | |
| GAL | galactosidase |
| Gb3 | globotriaosylsphingosine |
| GLS | global longitudinal strain |
| **H** | |
| Hb | hemoglobin |
| HbA1c | glycated hemoglobin |
| HBV | hepatitis B virus |
| HCM | hypertrophic cardiomyopathy |
| HFpEF | heart failure with preserved ejection fraction |

| | |
|---|---|
| HFrEF | heart failure with reduced ejection fraction |
| HOCM | hypertrophic obstructive cardiomyopathy |
| hsTnT | high-sensitivity troponin T |
| **I** | |
| ICD | implantable cardioverter-defibrillator |
| ICU | intensive care unit |
| Ig | immunoglobulin |
| IVS | interventricular septum |
| IVSd | interventricular septum end-diastolic diameter |
| **L** | |
| LAA | left atrial appendage |
| LGE | late gadolinium enhancement |
| LVd | left ventricle at end-diastolic phase |
| LVEDd | left ventricular end diastolic diameter |
| LVEDV | left ventricular end-diastolic volume |
| LVESd | left ventricular end-systolic diameter |
| LVH | left ventricular hypertrophy |
| LVIDd | left ventricular end-diastolic internal diameter |
| LVIDs | left ventricular end-systolic internal diameter |
| LVMI | left ventricular mass index |
| LVOT | left ventricular outflow tract |
| LVPW | left ventricular posterior wall |
| LVPWd | left ventricle end-diastolic posterior wall thickness |

| | |
|---|---|
| **M** | |
| MRA | mineralocorticoid receptor antagonist |
| MRI | magnetic resonance imaging |
| MSCT | multi-slice computed tomography |
| **N** | |
| NT-proBNP | N-terminal pro B-type natriuretic peptide |
| **P** | |
| PAF | paroxysmal atrial fibrillation |
| PPM | permanent pacemaker |
| proBNP | pro B type natriuretic peptide |
| PVC | premature ventricular contraction |
| PYP | pyrophosphate |
| **R** | |
| RBBB | right bundle branch block |
| ROSC | return of spontaneous circulation |
| RPR | rapid ventricular response |
| RWT | relative wall thickness |
| **S** | |
| SA | sinoatrial |
| SAM | systolic anterior motion |
| SGLT2 | sodium–glucose cotransporter 2 |
| SLE | systemic lupus erythematosus |
| SVT | supraventricular tachycardia |

| | |
|---|---|
| **T** | |
| TSH | thyroid-stimulating hormone |
| **U** | |
| UA | urinalysis |
| UPCR | urine protein/creatinine ratio |
| **V** | |
| VF | ventricular fibrillation |
| VPC | ventricular premature contraction |
| VT | ventricular tachycardia |

# 法布瑞氏症案例集

## FabryBook – A case based learning module

發行單位：中華民國心臟學會
地址：10491 台北市中山區民權西路 11 號 13 樓之 1
電話：02-2597-6177
傳真：02-2597-6180
網址：www.tsoc.org.tw

---

發行人：陳文鍾
總編輯：吳彥雯、余文鍾
編審委員：吳彥雯、林志展、洪崇烈、莊志明、黃群耀、賴志泓
( 依姓氏筆畫排列 )
案例作者：王宇澄、王朝永、朱俊源、余文鍾、林中行、林志展、林圀宏、林恆旭、施懿恩、徐千彝、高永達、張嘉修、莊文博、郭 泠、陳俊兆、陳柏升、黃偉春、黃群耀、賴志泓 ( 依姓氏筆畫排列 )
醫學影像顧問：郭 泠
腎臟功能顧問：塗坤樺

出版社：臻呈文化行銷有限公司
地址：106082 台北市大安區忠孝東路三段 249 號之一 10 樓
電話：02-2778-7711
傳真：02-2778-7755
網址： www.crossroad.com.tw
出版日期：西元 2024 年 6 月　初版

發行單位：中華民國心臟學會 TAIWAN SOCIETY OF CARDIOLOGY
委託出版社：CROSSROAD 臻呈文化行銷有限公司
9 786269 823857