Dermatologica Sinica

journal homepage: http://journals.lww.com/DERS

Review Article

Taiwanese Dermatological Association consensus on the diagnosis and management of alopecia areata

Chao-Chun Yang[1,2]*, Chih-Chiang Chen[3,4]*, Tzu-Kai Lin[5], Ming-Hsiu Lin[6], Sung-Jan Lin[7,8,9], Ching-Chi Chi[10,11], Ren-Yeu Tsai[12], Cheng-Che Lan[13,14], Wen-Hung Chung[10,11,15]

[1]Department of Dermatology, National Cheng Kung University Hospital, College of Medicine, National Cheng Kung University, Tainan, Taiwan, [2]International Center for Wound Repair and Regeneration, National Cheng Kung University, Tainan, Taiwan, [3]Department of Dermatology, Taipei Veterans General Hospital, Taipei, Taiwan, [4]Department of Dermatology, National Yang Ming Chiao Tung University, Taipei, Taiwan, [5]Department of Dermatology, Hualien Tzu Chi Hospital, Buddhist Tzu Chi Medical Foundation, and Tzu Chi University, Hualien, Taiwan, [6]Department of Dermatology, School of Medicine, College of Medicine, Taipei Medical University Hospital and Taipei Medical University, Taipei, Taiwan, [7]Department of Biomedical Engineering, College of Medicine and College of Engineering, National Taiwan University, Taipei, Taiwan, [8]Department of Biomedical Research and Department of Dermatology, National Taiwan University Hospital, Taipei, Taiwan, [9]Research Center for Developmental Biology and Regenerative Medicine, National Taiwan University, Taipei, Taiwan, [10]Department of Dermatology, Chang Gung Memorial Hospital, Linkou, Taoyuan, Taiwan, [11]School of Medicine, College of Medicine, Chang Gung University, Taoyuan, Taiwan, [12]Department of Dermatology and Skin Laser Center, Taipei Municipal Wan-Fang Hospital, Taipei Medical University, Taipei, Taiwan, [13]Department of Dermatology, Kaohsiung Medical University Hospital, Kaohsiung, Taiwan, [14]Department of Dermatology, College of Medicine, Kaohsiung Medical University, Kaohsiung, Taiwan, [15]Drug Hypersensitivity Clinical and Research Center, Chang Gung Memorial Hospital, Linkou, Taoyuan, Taiwan

Abstract

Alopecia areata (AA), an autoimmune disorder that causes well defined patches of scalp hair loss, significantly impacts the quality of life and mental well being of patients and their families. However, the paucity of treatment guidelines and expert consensus for AA in Taiwan, compared to other dermatological conditions, leads to substantial heterogeneity in the therapeutic strategies employed by clinicians. To discuss strategies for managing AA, address knowledge gaps, and provide a reference for dermatologists and other specialists in Taiwan. The Taiwanese Dermatological Association held Expert Panel meetings between 2023 and 2024, during which experts reviewed existing evidence, shared clinical experiences, and reached consensus on recommendations for clinical classification, diagnosis, severity evaluation, and treatment options for AA. The statements were approved if they received agreement from more than 75% of the committee members. For mild to moderate AA, the consensus suggests that first line therapy may include topical corticosteroids or intralesional corticosteroid injections, with or without adjunctive topical 5% minoxidil. In severe AA cases, initial treatment options include oral or intravenous corticosteroids or oral Janus kinase inhibitors, potentially combined with topical or intralesional corticosteroids. AA not only impacts patients' physical appearance but also their mental and social well-being. Therefore, in addition to hair recovery, it is crucial to address patients' psychological adjustment. Given the diverse treatment options and the varying psychological impacts on AA patients, the most appropriate personalized treatment plan should be established through shared decision making between physicians and patients.

Key words: Alopecia areata, consensus, corticosteroid, diagnosis, Janus kinase inhibitors, treatment

Address for correspondence: Prof. Chao-Chun Yang, Department of Dermatology, National Cheng Kung University Hospital, No. 138 Sheng-Li Rd., North Dist., Tainan 704, Taiwan.
E-mail: yangcc@mail.ncku.edu.tw
Dr. Chih-Chiang Chen, Department of Dermatology, Taipei Veterans General Hospital, No. 201, Sec. 2, Shipai Rd., Beitou Dist., Taipei 11217, Taiwan.
E-mail: docs1.tw@yahoo.com.tw

Submitted: 21-Aug-2024 **Revised:** 05-Nov-2024 **Accepted:** 19-Nov-2024 **Published:** 07-Mar-2025

Access this article online

Quick Response Code:

Website: http://journals.lww.com/DERS

DOI: 10.4103/ds.DS-D-24-00188

This is an open access journal, and articles are distributed under the terms of the Creative Commons Attribution-NonCommercial-ShareAlike 4.0 License, which allows others to remix, tweak, and build upon the work non-commercially, as long as appropriate credit is given and the new creations are licensed under the identical terms.

For reprints contact: WKHLRPMedknow_reprints@wolterskluwer.com

How to cite this article: Yang CC, Chen CC, Lin TK, Lin MH, Lin SJ, Chi CC, *et al*. Taiwanese Dermatological Association consensus on the diagnosis and management of alopecia areata. Dermatol Sin 0;0:0.

Introduction

Alopecia areata (AA) is an autoimmune disease characterized by patches of hair loss with distinct borders on the scalp.[1] AA significantly affects the quality of life and psychological health of patients and their family members, often hindering social interaction and productivity. The onset and severity of AA are believed to be influenced by genetic predispositions and triggered by environmental factors. Although AA may resolve spontaneously in patients with mild symptoms, active treatment is generally recommended owing to its unpredictable nature.[1]

Treatment guidelines and expert consensus for AA are limited compared to those for other dermatological diseases, leading to considerable variability in treatment approaches among physicians. Recent clinical trials and observational studies have provided empirical evidence for the efficacy of AA treatment. Moreover, genome-wide association studies and next-generation sequencing data have highlighted its pathogenesis, identifying genes such as *PTPN22*, *CTLA4*, and *IL2* as being associated with AA.[2] Notably, Janus kinase (JAK) inhibitors have emerged as a new treatment option.[3,4] Therefore, the Taiwanese Dermatological Association (TDA) invited expert physicians specializing in alopecia treatment to formulate this consensus, aiming to provide a reference for the treatment of AA.

To establish a consensus on the diagnosis, classification, and management of AA, the TDA invited nine experienced dermatologists from various regions of Taiwan to form a consensus committee. The recommendations presented in this consensus document were synthesized from a comprehensive review of international guidelines and published literature, specifically considering the healthcare infrastructure and clinical practice patterns unique to Taiwan. All content underwent rigorous scrutiny and received unanimous approval from all consensus members before its inclusion in the final manuscript. The committee discussed key items, including clinical classification, diagnosis, severity evaluation, and treatment options. This content was reviewed and endorsed by experts during the TDA AA consensus meetings held on November 29, 2023, and March 20, 2024. The statements were approved if they received agreement from more than 75% of the committee members. Consensus statements on AA classification, diagnosis, and management are summarized in Table 1.

Epidemiology

Epidemiological studies estimate the lifetime risk of AA at 1.7%–2.1%,[5,6] with various environmental triggers, infections, medications, vaccines, and psychological stressors contributing to its onset or recurrence. However, the cause of a particular episode in an individual is often unknown. Sex differences in AA incidence have been inconsistently reported, and some studies suggest poorer prognoses in male individuals.[7,8] AA affects all age groups; however, 66% of patients experience AA onset before the age of 30 years, with a peak incidence between 25 and 29 years.[1,9] In Asian populations, 85.5% of AA cases manifest before the age of 40.[10] However, a school-based study in Kaohsiung revealed a relatively high prevalence of AA in children and adolescents (0.1%, 95% confidence interval [CI]: 0.099–0.101%).[11] Studies on late-onset AA (≥50 years) in Taiwan have indicated a marked female predominance, with severity generally decreasing with age. The most prevalent presentation in late-onset AA involves multifocal lesions, accounting for 41% of cases.[12]

Associated Diseases and Risk Factors

Previous studies have demonstrated that AA onset before puberty, family history of AA, AA persisting for more than 1 year, nail involvement, and the presence of comorbid atopic dermatitis are associated with a poor prognosis of AA.[13-17] In addition, AA is closely linked to autoimmune conditions, including allergic rhinitis, thyroid disorders, lupus erythematosus, and vitiligo. Emerging research has suggested a strong association between AA and anxiety, depression, and other psychiatric conditions.[18,19]

Patients with AA exhibit a 1.61-fold higher risk of stroke (95% CI: 1.13–2.30).[20] and a 3.18-fold increased risk of sensorineural hearing loss (95% CI: 2.06–4.89, $I^2 = 0\%$) than controls, potentially owing to immune-mediated damage to melanocytes.[21] Although autoimmune diseases generally increase cancer risk, Taiwanese studies have demonstrated a slightly decreased overall cancer risk in patients with AA, with a standardized incidence ratio (SIR) of 0.89 in males.[22] Specifically, patients with AA have significantly lower risks of nonmelanoma skin cancer (SIR: 0.59; 95% CI: 0.38–0.80), upper digestive tract cancer (SIR: 0.70; 95% CI: 0.58–0.82), liver cancer (SIR: 0.82; 95% CI: 0.71–0.94), and uterine and cervical cancer (SIR: 0.84; 95% CI: 0.70–0.97). Conversely, they exhibited increased susceptibility to lymphoma, breast cancer, kidney, and urinary bladder cancer, with SIRs of 1.55 (95% CI: 1.20–1.90), 2.93 (95% CI: 2.64–3.22), and 2.95 (95% CI: 2.41–3.50), respectively. Age-stratified analysis revealed a higher breast cancer risk in female patients with AA aged 50 years or younger (SIR: 3.37; 95% CI: 2.98–3.77).[22]

Clinical Presentation and Classification

The most common clinical presentation of AA is the presence of one or more patches of alopecia on the scalp [Figure 1]. The skin in these patches usually appears normal, with smooth surfaces and minimal skin color changes. By closer inspection or dermatoscopic examination, the hair follicle openings are still visible, indicating the nonscarring property of AA. Some patients may experience dysesthesia of the scalp, pruritus, and tingling sensations at alopecia sites, indicating active disease.[23,24] Patients with AA experience increased hair shedding to varying degrees, which corresponds to the activity level of the disease.

In addition to typical alopecia patches, some patients with AA may develop more challenging forms such as alopecia ophiasis, alopecia totalis, alopecia universalis, or diffuse AA, which are less responsive to treatments [Figure 2].[16,25,26] Chronic

Table 1: Key statements on the classification, diagnosis, and clinical management of alopecia areata

Statements	Consensus rate (%)
Epidemiology and pathogenesis	
AA is an autoimmune disease that significantly impacts the quality of life and psychological health of patients and their family members, disrupting normal social interactions and productivity	100
Various factors contribute to the occurrence and recurrence of AA, including environmental triggers, infections, medications, vaccines, major psychological trauma, and acute stress, although the exact causes often remain unknown	100
Several risk factors predispose individuals to AA, including a family history of AA or other autoimmune diseases and a medical history of autoimmune disease, thyroid disorder, vitiligo, and atopic dermatitis	100
Clinical features and diagnosis	
The classical presentation of AA includes patches of hair loss with distinct borders, easily pluckable hair, broken hair shafts, and black dots on the scalp, particularly the presence of exclamation mark hairs	100
Diagnosing AA primarily relies on physical examination. A skin biopsy is required for a minority of patients with unclear diagnoses	100
Severity evaluation	
The SALT is a standard method for assessing AA severity	100
The entire body (not just the scalp) should be thoroughly examined during evaluation to detect hair loss in other areas. In addition, healthcare providers should assess the speed and duration of alopecia progression	100
When evaluating patients with AA, psychological health and quality of life must also be considered alongside physical examination	100
The severity of AA is classified as follows: Mild (SALT score ≤20%), moderate (SALT score >20% and ≤50%), and severe (SALT score >50%)	100
Chronic AA is defined as AA persisting for >6 months	100
Local treatment	
High-potency and ultra-high-potency topical corticosteroids can be considered in adult patients with AA	100
Intralesional corticosteroid injections are recommended in adult patients with AA	100
Topical corticosteroids are recommended in pediatric and adolescent patients with AA	100
Topical minoxidil can be considered in patients with AA	100
Topical immunotherapy, such as DPCP, can be considered in patients with moderate or severe chronic AA	100
Phototherapy, including ultraviolet, excimer light, or excimer laser, can be considered in patients with severe alopecia	88
Systemic treatment	
Systemic corticosteroids are recommended in adult patients with severe AA	100
Systemic corticosteroids can be considered in pediatric and adolescent patients with AA but should be used with caution	100
Oral JAK inhibitors are recommended in adult patients with severe AA	100
Oral JAK inhibitors are recommended in pediatric and adolescent patients with severe AA	100
Cyclosporine can be considered in adult patients with severe AA	100
Methotrexate can be considered in adult patients with severe AA	100

SALT: Severity of alopecia tool, JAK: Janus kinase, DPCP: Diphenylcyclopropenone

Figure 1: Typical clinical presentation of alopecia areata showing a discrete hair loss patch.

AA is characterized by the persistence of alopecia patches for more than 6 months. Rapid progressive AA, characterized by acute diffuse alopecia affecting almost the entire scalp, is often accompanied by alopecia in other body areas.[27,28] Although pulse steroid therapy in the early stages of rapidly progressing AA can effectively halt the worsening of hair loss and promote hair regrowth, treatment failure and persistent alopecia may still occur.[27] Acute diffuse and total alopecia, another variant of AA with symptoms resembling those of rapidly progressing AA, tends to have a fast recovery and a favorable prognosis.[29,30]

Diagnosis

AA is diagnosed based on the presence of alopecia patches with well-defined boundaries and the presence of broken hair shafts. Trichoscopy is performed to facilitate the detection

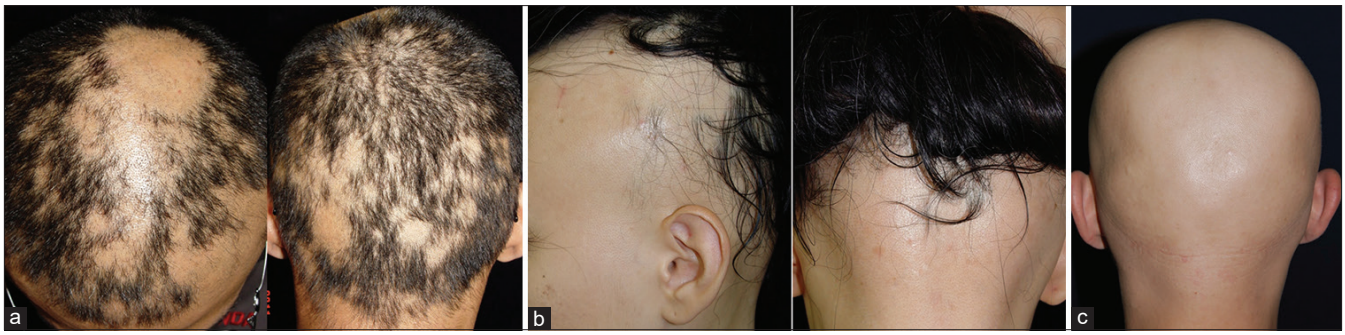

Figure 2: Alopecia areata subtypes that are more challenging to treat. (a) severe alopecia areata, (b) alopecia ophiasis, (c) alopecia totalis.

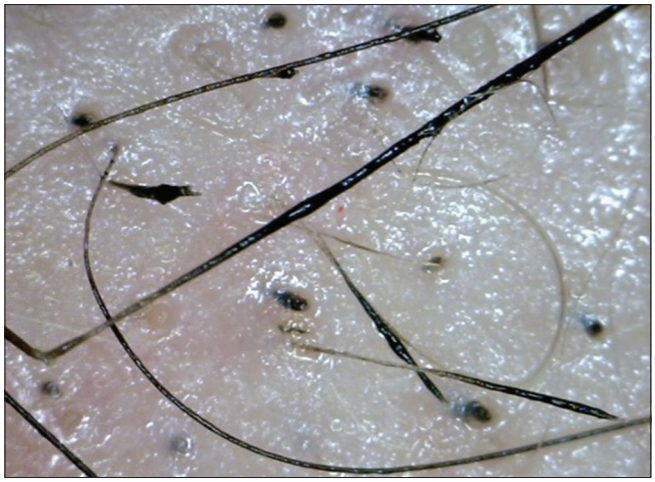

Figure 3: Exclamation mark hairs and black dots as the hallmark feature of alopecia areata.

of exclamation mark hair and black dots [Figure 3].[17,31] The patients typically experience increased hair shedding, and their hair is easily pulled out at the active site. In most cases, a diagnosis can be made based on the clinical symptoms and examination results. However, careful consideration is necessary to differentiate AA from other conditions such as tinea capitis, trichotillomania, syphilis, primary cicatricial alopecia, aplasia cutis, triangular alopecia, and other easily misdiagnosed diseases.[26] Scarring alopecia can sometimes present as patchy hair loss, most commonly observed in traumatic scarring alopecia, discoid lupus erythematosus, and dissecting folliculitis (cellulitis), lichen planopilaris and frontal fibrosing alopecia.[32,33] The presence and preservation of hair follicle openings within alopecia patches under a dermatoscope help distinguish AA from scarring alopecia, while skin pathology examination can further confirm scarring alopecia and identify its subtype. Tinea capitis should be considered when inflammatory papules, pustules, scales, or crusts are present within the hair loss patches, particularly in children or postmenopausal women who are more susceptible to tinea capitis. The broken hair shafts observed in trichotillomania feature uneven length and a split or friable distal end, in contrast to the tapered distal end observed in AA. In trichotillomania, hair loss patches often exhibit irregular and bizarre shapes, whereas in AA, they appear smoother and relatively symmetrical. Differentiating diffuse AA from telogen effluvium or androgenetic alopecia can be challenging, and accurate diagnosis often requires histopathological examination. In addition, the presence of trachyonychia, fine nail pitting, and nail dystrophy supports the diagnosis of AA.[34] A skin biopsy should be considered if the diagnosis cannot be confirmed based on clinical symptoms and signs.

Severity Evaluation

The Severity of Alopecia Tool (SALT) is a standardized assessment tool used to evaluate the severity of AA [Figure 4].[35] Based on SALT, the severity of AA can be classified as mild (SALT score ≤20%), moderate (SALT score >20% and ≤50%), or severe (SALT score >50%).

The limitation of SALT is that it only assesses scalp hair loss, does not include hair status on the face or other body areas, and fails to address the significant correlation between AA and patients' psychological and mental states. Some patients exhibit poor long-term treatment responses, necessitating differentiation in severity assessment. To address these limitations, we combined the SALT criteria with the four secondary clinical features, as listed in Table 2. When these features are present, the severity of alopecia increases by one level. This approach maintains a quantitative evaluation of alopecia and addresses aspects previously overlooked by SALT.[36]

Regarding the negative impact of AA on psychosocial function, we recommend the use of well-established assessment tools that are widely recognized within the international dermatological community. These tools include the Dermatology Life Quality Index, Patient Health Questionnaire-9, and the Hospital Anxiety and Depression Scale (HADS), with its subcomponents HADS-A for anxiety and HADS-D for depression.[37-39] These validated measures yield objective and quantifiable data for evaluating the psychosocial dimensions of patients affected by AA. In cases where significant psychological impact is identified, comprehensive care may necessitate interdisciplinary collaboration between dermatologists and psychiatrists. This integrated approach, combining standardized assessment tools with collaborative care, allows clinicians to systematically monitor psychological burdens and accordingly implement

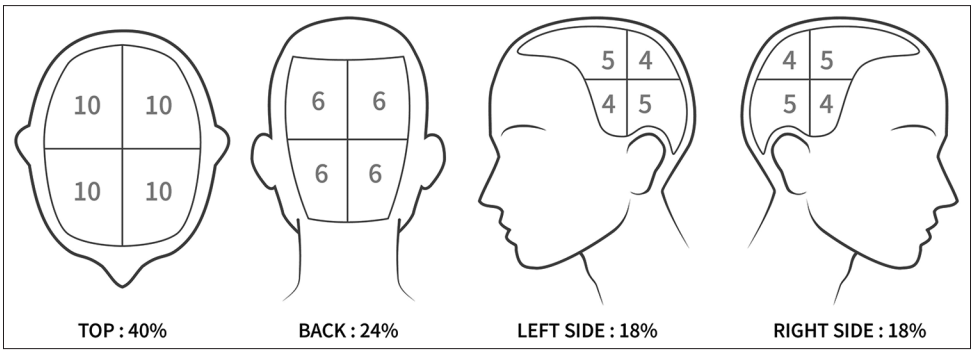

Figure 4: Assessment of hair loss using Severity of Alopecia Tool scoring.

Table 2: Definition of alopecia areata severity

Severity	Extent of scalp alopecia
Mild AA	≤20% scalp hair loss (or SALT score ≤20%)
Moderate AA	21%–50% scalp hair loss (or SALT scores >20% and ≤50%)
Severe AA	51%–100% scalp hair loss (or SALT score >50%)
AA severity is increased by 1 level when ≥1 of the following features is (are) present	
Negative impact on psychosocial function due to AA	
Noticeable involvement of the eyebrows or eyelashes	
Inadequate response after ≥6 months of treatment	
Rapidly progressive and extensive alopecia and/or positive hair pull test	

SALT: Severity of alopecia tool, AA: Alopecia areata

targeted interventions. This would ensure a holistic management of the dermatological condition and its associated psychosocial sequelae.

Treatment Efficacy Assessment and Adjustment

The treatment goal of AA is to improve scalp hair coverage. After a course of treatment, which typically lasts for 3–6 months, patients who had a SALT score reduction of ≥75% compared to pretreatment levels or a decrease in SALT score to ≤20% are considered to have achieved treatment success.[34] If the SALT score decreases by <50% compared with the pretreatment level, the existing treatment regimen should be adjusted. If the SALT score decreases by 50%–75%, physicians should discuss with the patient whether to continue or adjust the treatment [Figure 5].[40]

Treatment Options

Treatment should be selected based on the patient's age and AA severity. Figure 6 and Table 3 present the comprehensive treatment flowchart and recommended dosages for systemic medications. Further elaboration on treatment options is provided in subsequent sections.

Topical Treatment

Topical corticosteroid treatment

Topical corticosteroids are considered the first-line topical treatment, particularly in children aged <12 years who cannot tolerate intralesional corticosteroid injection.[41] High-potency and ultra-high-potency topical corticosteroids, such as clobetasol propionate foam, cream, and ointment, are recommended for adult patients with AA.[42] For children aged <12 years, mid- to low-potency corticosteroids such as mometasone are initially preferred.[42] The medication should be administered daily for 6 weeks to 6 months, with evaluations every 2–3 months during treatment.[41] Once hair starts to regrow in the affected areas, the dose of strong-potency topical corticosteroids should be gradually reduced.[23] Side effects include folliculitis, skin atrophy, pigmentation abnormalities, capillary dilatation, and, rarely, adrenal suppression.[43]

Minoxidil

Minoxidil increases the length and thickness of new hair by extending the anagen phase of the hair cycle.[43] Its advantages include ease of use and minimal side effects such as mild dermatitis and pruritus. Less than 5% of patients may experience hypertrichosis, lowered blood pressure, dizziness, or headaches.[42] However, minoxidil monotherapy is not recommended and should be used in combination with other first-line topical preparations to maintain hair growth induced by other treatments.[42,43] Concomitant minoxidil is not required for all patients with AA undergoing topical treatment.[41] The recommended dose for adults is 5% minoxidil, while for children it is 2%, administered once or twice daily.[43,44] It is recommended that clinicians exercise caution when prescribing minoxidil treatment for children.

Topical immunotherapy

Topical immunotherapy is primarily recommended for chronic AA, including moderate or severe patchy AA, alopecia ophiasis, alopecia totalis, or alopecia universalis.[41] The chemical agents commonly used for topical immunotherapy include diphenylcyclopropenone (DPCP) and squaric acid dibutyl ester, with DPCP being the most commonly used. In AA patients treated with DPCP, 53.5% (46/86) experienced >75% hair regrowth, and 32.6% (28/86) achieved >90% hair regrowth.[45] Good prognostic factors for DPCP treatment in AA include older age at onset, early initiation of treatment, mild alopecia, and hair loss limited to the scalp region.[46] Topical immunotherapy may cause allergic contact dermatitis,[23,42] and DPCP is contraindicated for pregnant women.[42] Common side effects include pigment changes, vitiligo (particularly in

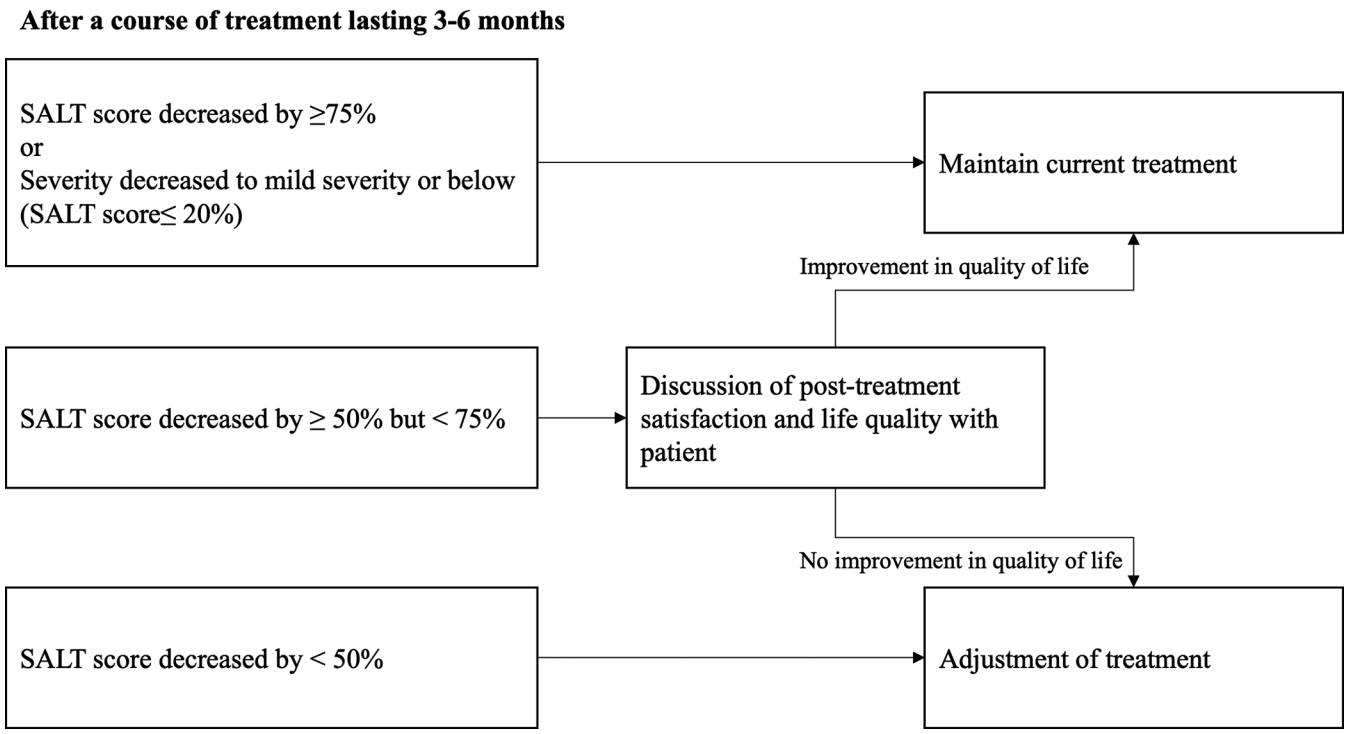

Figure 5: Assessment protocol for alopecia treatment.

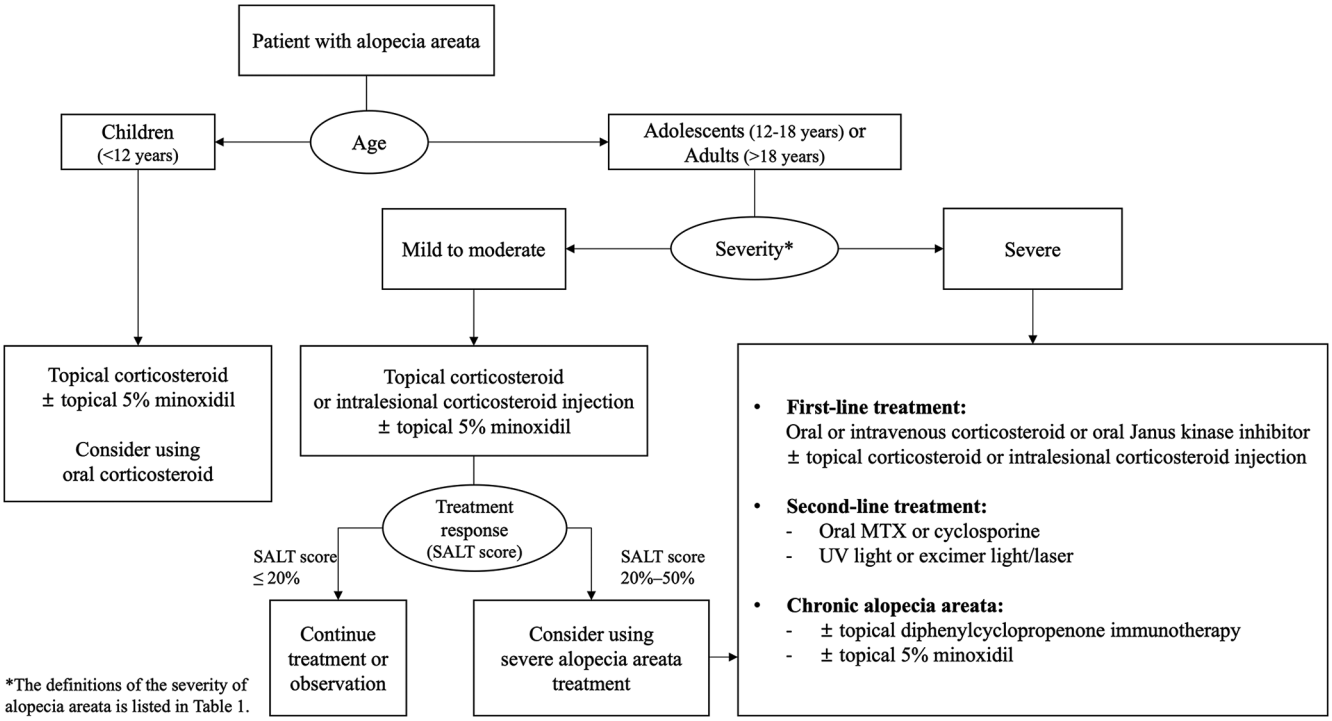

Figure 6: Algorithm for selecting treatment options for alopecia areata.

patients with dark skin), eczema, blisters, lymphedema, and flu-like symptoms.[23,43]

Intralesional corticosteroid injection

Intralesional corticosteroid injection is regarded as the first-line treatment for patients with active AA.[23,41,43,47] The most commonly used corticosteroid is triamcinolone acetonide (TA), typically prepared at a concentration of 2.5–10 mg/mL, with a maximum dose of 10–20 mg per treatment session, administered at intervals of 2–6 weeks between injections.[41,43] An optimal treatment response was achieved with 10 mg/mL of

Table 3: Recommended dose and duration of systemic medication

	Route of administration	Dose	Recommended treatment duration
Prednisolone (or other corticosteroids in equivalent dose)	Oral, IV or IM	0.2–0.5 mg/kg/day (pulse therapy: 5–10 mg/kg bolus)	Adult: 2–6 months Children and adolescents: 1–3 months
Methotrexate	Oral	Adult: 7.5–15 mg/week Children and adolescents: ≤10 mg/week	<6 months
Cyclosporine	Oral	2–5 mg/kg/day	<6 months
Baricitinib	Oral	4 mg/day	12–104 weeks
Ritlecitinib	Oral	50 mg/day	12–96 weeks

IV: Intravenous, IM: Intramuscular

TA on the scalp while maintaining acceptable levels of adverse reactions.[48] If no improvement occurs within 6 months, the injection should be discontinued.[43] Common side effects of intralesional corticosteroid injection include pain, bleeding, headache, systemic absorption, dyschromia, reversible local cutaneous atrophy (persisting for several months), and, rarely, anaphylaxis.[43]

Systemic Treatment

Patients with severe AA may require systemic oral or intravenous treatment. The most common systemic treatment options include oral corticosteroids, cyclosporine, and methotrexate. JAK inhibitors have shown good efficacy in clinical trials for treating severe AA. The subsequent sections provide a detailed description of these treatments. The recommended doses of these systemic agents are listed in Table 3.

Systemic corticosteroids

Systemic corticosteroids are the recommended treatment choice for severe AA in children, adolescents, and adults. Systemic corticosteroids can be administered orally, intramuscularly, or intravenously. The recommended dose of prednisolone is 0.2–0.5 mg/kg/day, or an equivalent dose of another corticosteroid, for 2–6 months in adults and 1–3 months in children and teenagers. For adults with severe AA, oral or intravenous corticosteroid pulse therapy is recommended. The dose for pulse therapy is 5–10 mg/kg/day for 1–3 days, administered weekly to monthly.[49,50] For patients with severe AA, the rate of satisfactory response to pulse therapy (defined as >75% hair regrowth) was 51.8%, while the recurrence rate after discontinuing treatment was 22.7%.[49] The side effects of long-term use of systemic corticosteroids can be significant; therefore, the benefits and risks of prolonged use should be carefully weighed.

Cyclosporine

Although previous studies have demonstrated the moderate efficacy of cyclosporine monotherapy in alleviating moderate-to-severe AA,[51] some systematic reviews have shown that cyclosporine combined with systemic corticosteroids yields superior efficacy and lower recurrence rates compared to cyclosporine alone.[52,53] In a meta-analysis based on 344 patients, the overall response rate to cyclosporin monotherapy and combined therapy was 73% and the overall recurrence rate was 39%.[52] However, the current data are still insufficient to conclude the efficacy of cyclosporine. The recommended dose of cyclosporine is 2–5 mg/kg/day with a recommended treatment duration of <6 months. Side effects occurred in 0%–83% of the patients, depending on the dose and treatment duration of cyclosporine.[52] Significant and common side effects include increased blood pressure, kidney damage, hypertrichosis, and infection, which require close monitoring.

Methotrexate

Two meta-analysis studies indicated that patients with AA may achieve complete or good remission after methotrexate treatment in adult or pediatric cases.[54,55] The response rate of hair regrowth was 63% and the complement hair regrowth rate was 36% in adults.[54] The recurrence rate of AA was 48%. However, in a double-blind randomized study recruiting 89 patients with alopecia totalis or alopecia universalis, only 2 out of 45 (4.4%) patients with methotrexate monotherapy achieved good hair regrowth (SALT score ≤25%).[54] The recommended dose of methotrexate is 7.5–15 mg/week for adults and 10 mg/week for children and teenagers, with a suggested treatment duration of <6 months. Significant and common side effects of methotrexate include hematological and liver abnormalities, infection, and mucocutaneous toxicity, and require regular monitoring.

Janus kinase inhibitors

As the role of the JAK-STAT pathway in AA pathogenesis has gained recognition, JAK inhibitors have emerged for treating AA. Among all JAK inhibitors, baricitinib and ritlecitinib have been approved by the Food and Drug Administration in Taiwan, the US, and other countries for treating severe AA. Although both medications are used to treat severe AA, their approved age indications differ. Baricitinib is indicated for severe AA in adults, whereas ritlecitinib can be used for severe AA in adolescents and adults.

Two phase 3 clinical trials (BRAVE-AA1 and BRAVE-AA2) evaluating baricitinib for AA treatment included 654 and 546 adult patients with severe AA, respectively.[56,57] After 36 weeks of treatment, approximately 38.8% of patients on baricitinib 4 mg achieved a SALT score of ≤20%, compared to 22.8% in the baricitinib 2 mg group and 6.2% in the placebo group, according to results from BRAVE-AA1. In BRAVE-AA2, the percentages were 35.9%, 19.4%, and 3.3%, respectively. Both doses of baricitinib showed a statistically significant difference in treatment efficacy compared to

placebo. At week 104 of follow-up, mixed statistical data from patients treated with baricitinib indicated that 39.1% achieved a SALT score ≤20%. Common adverse reactions include upper respiratory tract infections, headaches, nasopharyngitis, acne, urinary tract infections, and elevated creatine phosphokinase levels.

The ALLEGRO phase 2b/3 trial recruited 718 patients aged ≥12 years with severe AA who were treated with ritlecitinib or placebo.[58] This marked the first phase 3 trial of JAK inhibitors in adolescents. The study revealed that 23% of patients receiving ritlecitinib 50 mg achieved a SALT score ≤20% at week 24 follow-up compared to 1.6% in the placebo group, indicating a significant difference in treatment efficacy. During the extension period, the proportion of patients achieving a SALT score ≤20% further increased to 43% in the ritlecitinib 50 mg group after 48 weeks of follow-up. A 96-week follow-up study further revealed that the proportion of patients with a SALT score ≤20% increased to 60.8%, with nearly 80% of patients maintaining their response from week 48 up to week 96.[59] Regarding safety, approximately 4% of ritlecitinib-treated patients experienced adverse events, such as headache (10.8%), diarrhea (10%), acne (6.2%), rashes (5.4%), and urticaria (4.6%). Ritlecitinib demonstrated similar efficacy and safety profiles in adolescents (12–17 years old) and adults (≥18 years old).

Tofacitinib, the first JAK inhibitor to be developed, is a viable off-label treatment option for AA. A Taiwanese study showed that 51.4% of patients with severe AA achieved ≥50% hair regrowth after 4–24 months with good tolerance.[60] Another study found that 60% of responders achieved a >50% SALT score reduction after 6 months of treatment with 5 mg tofacitinib, with no further benefit observed from dose escalation.[61]

A critical consideration is that the longitudinal safety data for JAK inhibitors currently extend only to 104 weeks. Based on therapeutic experience in other clinical diseases, it is essential to increase awareness of immunosuppression-associated risks, most commonly herpes zoster, and other specific adverse effects, including hyperlipidemia, elevated creatine phosphokinase levels and venous thrombosis. To ensure patient well-being, we strongly emphasize that clinicians must rigorously adhere to the risk management plans established by regulatory authorities during the implementation of these therapeutic agents.

Other Treatments

Phototherapy

Photochemotherapy with psoralen and ultraviolet A radiation (PUVA) was the standard treatment for AA between 1980 and 1990. However, long-term PUVA treatment potentially increases the risk of skin tumors.[62] Nonetheless, phototherapies such as UVA-1 and narrowband UVB are not endorsed as AA treatment options in prevailing guidelines or expert consensus worldwide, owing to limited clinical trials and inconsistent literature.[41,63] Therefore, ultraviolet phototherapy may serve as an alternative treatment for AA after the failure of first-line treatment; however, careful consideration of potential long-term side effects is advised.

Excimer laser/excimer light

A limited number of previous studies have demonstrated the efficacy of excimer light in treating AA, particularly in cases where patients were unresponsive to standard therapies, highlighting its potential in managing refractory disease.[64-67] A systematic review indicated that 50.2% of patients achieved cosmetically satisfactory hair regrowth after an average of 12 weeks of treatment.[68] Notably, even in resistant cases, a Taiwanese study revealed that The overall response rate for excimer light in treating AA was 41.2%. Of these, 29.4% had more than 50% regrowth in affected areas (considered a good response), and 11.7% had <50% regrowth. However, 58.8% showed no hair regrowth or experienced further hair loss. Among patients with alopecia totalis or alopecia universalis, the response rate was 60%.[69] Common side effects include mild erythema, treatment-induced pain, pigmentation, blisters, pruritus, and skin desquamation.[70]

Conclusion

AA not only impacts patients' physical appearance but also their mental and social well-being. Therefore, in addition to hair recovery, it is crucial to address patients' psychological adjustment. Given the availability of various therapeutic options, treatment strategies should be individualized through shared decision-making between clinicians and patients. Moreover, both pharmacological and nonpharmacological interventions for AA necessitate prolonged administration to evaluate their therapeutic efficacy, as disease recurrence is frequently observed following treatment discontinuation. The present consensus did not address management strategies for recurrent AA and treatment response-based dose adjustments, given the complexity of clinical scenarios and the current paucity of literature, management strategies for recurrent AA and treatment response-based dose adjustments. Furthermore, while novel small-molecule therapeutics demonstrate promising efficacy, their long-term safety profiles and therapeutic effects warrant further investigation. This represents a key objective for future iterations of our consensus guidelines. We aim to incorporate emerging longitudinal studies and their findings into subsequent versions of the consensus document, thereby enhancing our understanding and recommendations for AA management.

Declaration of patient consent

This study was performed in accordance with and conforming to the Declaration of Helsinki. The authors certify that they have obtained all appropriate patient consent form. In the form, the patient has given his consent for his images and other clinical information to be reported in the journal. The patient understands that name and initials will not be published and due efforts will be made to conceal identity, but anonymity cannot be guaranteed.

Acknowledgments

The consensus meeting was organized and funded by the TDA. The manuscript was drafted and approved by the consensus committee members. Editorial support was provided by COMPASS Co., LTD.

Data availability statement

Data sharing is not applicable to this article as no datasets were generated or analyzed during the current study.

Financial support and sponsorship

The consensus meeting was funded by the TDA.

Conflicts of interest

Chao-Chun Yang, Chih-Chiang Chen, Sung-Jan Lin, Ching-Chi Chi, Ren-Yeu Tsai, Cheng-Che Lan and Wen-Hung Chung, editorial board members at *Dermatologica Sinica*, had no roles in the peer review process of or decision to publish this article. All authors declared no conflicts of interest in writing this paper.

References

1. Gilhar A, Etzioni A, Paus R. Alopecia areata. N Engl J Med 2012;366:1515-25.
2. Ho CY, Wu CY, Chen JY, Wu CY. Clinical and genetic aspects of alopecia areata: A cutting edge review. Genes (Basel) 2023;14:1362.
3. Rajabi F, Drake LA, Senna MM, Rezaei N. Alopecia areata: A review of disease pathogenesis. Br J Dermatol 2018;179:1033-48.
4. Xing L, Dai Z, Jabbari A, Cerise JE, Higgins CA, Gong W, *et al.* Alopecia areata is driven by cytotoxic T lymphocytes and is reversed by JAK inhibition. Nat Med 2014;20:1043-9.
5. Mirzoyev SA, Schrum AG, Davis MD, Torgerson RR. Lifetime incidence risk of alopecia areata estimated at 2.1% by Rochester epidemiology project, 1990-2009. J Invest Dermatol 2014;134:1141-2.
6. Safavi KH, Muller SA, Suman VJ, Moshell AN, Melton LJ 3rd. Incidence of alopecia areata in Olmsted County, Minnesota, 1975 through 1989. Mayo Clin Proc 1995;70:628-33.
7. You HR, Kim SJ. Factors associated with severity of alopecia areata. Ann Dermatol 2017;29:565-70.
8. Xiao FL, Yang S, Liu JB, He PP, Yang J, Cui Y, *et al*. The epidemiology of childhood alopecia areata in China: A study of 226 patients. Pediatr Dermatol 2006;23:13-8.
9. Harries M, Macbeth AE, Holmes S, Chiu WS, Gallardo WR, Nijher M, *et al*. The epidemiology of alopecia areata: A population-based cohort study in UK primary care. Br J Dermatol 2022;186:257-65.
10. Tan E, Tay YK, Goh CL, Chin Giam Y. The pattern and profile of alopecia areata in Singapore – A study of 219 Asians. Int J Dermatol 2002;41:748-53.
11. Yang YC, Cheng YW, Lai CS, Chen W. Prevalence of childhood acne, ephelides, warts, atopic dermatitis, psoriasis, alopecia areata and keloid in Kaohsiung County, Taiwan: A community-based clinical survey. J Eur Acad Dermatol Venereol 2007;21:643-9.
12. Wu MC, Yang CC, Tsai RY, Chen WC. Late-onset alopecia areata: A retrospective study of 73 patients from Taiwan. J Eur Acad Dermatol Venereol 2013;27:468-72.
13. Sterkens A, Lambert J, Bervoets A. Alopecia areata: A review on diagnosis, immunological etiopathogenesis and treatment options. Clin Exp Med 2021;21:215-30.
14. Lee S, Lee H, Lee CH, Lee WS. Comorbidities in alopecia areata: A systematic review and meta-analysis. J Am Acad Dermatol 2019;80:466-77.e16.
15. Betz RC, Pforr J, Flaquer A, Redler S, Hanneken S, Eigelshoven S, *et al*. Loss-of-function mutations in the filaggrin gene and alopecia areata: Strong risk factor for a severe course of disease in patients comorbid for atopic disease. J Invest Dermatol 2007;127:2539-43.
16. Uchiyama M, Egusa C, Hobo A, Irisawa R, Yamazaki M, Tsuboi R. Multivariate analysis of prognostic factors in patients with rapidly progressive alopecia areata. J Am Acad Dermatol 2012;67:1163-73.
17. Tsuboi R, Itami S, Manabe M, Amoh Y, Ito T, Inui S. Japanese Dermatological Association's guidelines for the management of alopecia areata. Jpn J Dermatol 2017;127:2741-62.
18. Okhovat JP, Marks DH, Manatis-Lornell A, Hagigeorges D, Locascio JJ, Senna MM. Association between alopecia areata, anxiety, and depression: A systematic review and meta-analysis. J Am Acad Dermatol 2023;88:1040-50.
19. Bain KA, McDonald E, Moffat F, Tutino M, Castelino M, Barton A, *et al*. Alopecia areata is characterized by dysregulation in systemic type 17 and type 2 cytokines, which may contribute to disease-associated psychological morbidity. Br J Dermatol 2020;182:130-7.
20. Kang JH, Lin HC, Kao S, Tsai MC, Chung SD. Alopecia areata increases the risk of stroke: A 3-year follow-up study. Sci Rep 2015;5:11718.
21. Lien KH, Ger TY, Chi CC. Association of alopecia areata with sensorineural hearing loss: A systematic review and meta-analysis. Dermatology 2023;239:523-32.
22. Chen CC, Chang YT, Liu HN, Chen YJ. Cancer risk in patients with alopecia areata: A nationwide population-based matched cohort study. Cancer Med 2018;7:2153-9.
23. Rossi A, Muscianese M, Piraccini BM, Starace M, Carlesimo M, Mandel VD, *et al*. Italian guidelines in diagnosis and treatment of alopecia areata. G Ital Dermatol Venereol 2019;154:609-23.
24. Meah N, Wall D, York K, Bhoyrul B, Bokhari L, Asz-Sigall D, *et al*. The Alopecia Areata Consensus of Experts (ACE) study part II: Results of an international expert opinion on diagnosis and laboratory evaluation for alopecia areata. J Am Acad Dermatol 2021;84:1594-601.
25. Messenger AG, McKillop J, Farrant P, McDonagh AJ, Sladden M. British Association of Dermatologists' guidelines for the management of alopecia areata 2012. Br J Dermatol 2012;166:916-26.
26. Alkhalifah A, Alsantali A, Wang E, McElwee KJ, Shapiro J. Alopecia areata update: Part I. Clinical picture, histopathology, and pathogenesis. J Am Acad Dermatol 2010;62:177-88, quiz 189-90.
27. Fukuyama M, Sato Y, Kinoshita-Ise M, Yamazaki Y, Ohyama M. Chronological clinicopathological characterization of rapidly progressive alopecia areata resistant to multiple I.V. Corticosteroid pulse therapies: An implication for improving the efficacy. J Dermatol 2018;45:1071-9.
28. Sato Y, Kinoshita-Ise M, Fukuyama M, Yamazaki Y, Ohyama M. Development of a scoring system to predict outcomes of I.V. Corticosteroid pulse therapy in rapidly progressive alopecia areata adopting digital image analysis of hair recovery. J Dermatol 2021;48:301-9.
29. Lew BL, Shin MK, Sim WY. Acute diffuse and total alopecia: A new subtype of alopecia areata with a favorable prognosis. J Am Acad Dermatol 2009;60:85-93.
30. Sato-Kawamura M, Aiba S, Tagami H. Acute diffuse and total alopecia of the female scalp. A new subtype of diffuse alopecia areata that has a favorable prognosis. Dermatology 2002;205:367-73.
31. Waśkiel A, Rakowska A, Sikora M, Olszewska M, Rudnicka L. Trichoscopy of alopecia areata: An update. J Dermatol 2018;45:692-700.
32. Su HJ, Cheng AY, Liu CH, Chu CB, Lee CN, Hsu CK, *et al*. Primary scarring alopecia: A retrospective study of 89 patients in Taiwan. J Dermatol 2018;45:450-5.
33. Lee CN, Chen W, Hsu CK, Weng TT, Lee JY, Yang CC. Dissecting folliculitis (dissecting cellulitis) of the scalp: A 66-patient case series and proposal of classification. J Dtsch Dermatol Ges 2018;16:1219-26.
34. Olsen EA, Roberts J, Sperling L, Tosti A, Shapiro J, McMichael A, *et al.* Objective outcome measures: Collecting meaningful data on alopecia areata. J Am Acad Dermatol 2018;79:470-8.e3.
35. Wyrwich KW, Kitchen H, Knight S, Aldhouse NV, Macey J, Nunes FP, *et al.* The alopecia areata investigator global assessment scale: A measure for evaluating clinically meaningful success in clinical trials. Br J Dermatol 2020;183:702-9.
36. King BA, Mesinkovska NA, Craiglow B, Kindred C, Ko J, McMichael A, *et al*. Development of the alopecia areata scale for clinical use: Results of an academic-industry collaborative effort. J Am Acad Dermatol 2022;86:359-64.

37. Chernyshov PV, Tomas-Aragones L, Finlay AY, Manolache L, Marron SE, Sampogna F, *et al*. Quality of life measurement in alopecia areata. Position statement of the European Academy of Dermatology and venereology task force on quality of life and patient oriented outcomes. J Eur Acad Dermatol Venereol 2021;35:1614-21.
38. Alomaish AR, Gosadi IM, Dallak FH, Darraj AI, Jaafari SM, Alshamakhy AE, *et al*. Quality of life and the presence of depression among adults with hair loss in the South of Saudi Arabia. Psychol Res Behav Manag 2022;15:1989-96.
39. Ito T, Kamei K, Yuasa A, Matsumoto F, Hoshi Y, Okada M, *et al*. Health-related quality of life in patients with alopecia areata: Results of a Japanese survey with norm-based comparisons. J Dermatol 2022;49:584-93.
40. Fatani MI, Alkhalifah A, Alruwaili AF, Alharbi AH, Alharithy R, Khardaly AM, *et al*. Diagnosis and management of alopecia areata: A Saudi expert consensus statement (2023). Dermatol Ther (Heidelb) 2023;13:2129-51.
41. Meah N, Wall D, York K, Bhoyrul B, Bokhari L, Sigall DA, *et al*. The Alopecia Areata Consensus of Experts (ACE) study: Results of an international expert opinion on treatments for alopecia areata. J Am Acad Dermatol 2020;83:123-30.
42. Strazzulla LC, Wang EH, Avila L, Lo Sicco K, Brinster N, Christiano AM, *et al.* Alopecia areata: Disease characteristics, clinical evaluation, and new perspectives on pathogenesis. J Am Acad Dermatol 2018;78:1-12.
43. Ramos PM, Anzai A, Duque-Estrada B, Melo DF, Sternberg F, Santos LD, *et al*. Consensus on the treatment of alopecia areata – Brazilian Society of Dermatology. An Bras Dermatol 2020;95 Suppl 1:39-52.
44. Stefanaki C, Kontochristopoulos G, Hatzidimitraki E, Stergiopoulou A, Katsarou A, Vosynioti V, *et al*. A retrospective study on alopecia areata in children: Clinical characteristics and treatment choices. Skin Appendage Disord 2021;7:454-9.
45. Huang CM, Tsai TF. Topical diphenylcyclopropenone in the treatment of alopecia areata: A 10-year follow-up of 86 cases in a single center. Dermatol Sin 2022;40:214-21.
46. Huang CM, Tsai TF. Topical diphenylcyclopropenone in the treatment of alopecia areata: A 10-year follow-up of 86 cases in a single center. Dermatol Sin 2022;40:214.
47. Fukuyama M, Ito T, Ohyama M. Alopecia areata: Current understanding of the pathophysiology and update on therapeutic approaches, featuring the Japanese Dermatological Association guidelines. J Dermatol 2022;49:19-36.
48. Su HA, Chen YT, Chen YC. The optimal concentration of intralesional triamcinolone acetonide for patchy alopecia areata: A systematic review and meta-analysis. Dermatol Sin 2022;40:85.
49. Yang CC, Lee CT, Hsu CK, Lee YP, Wong TW, Chao SC, *et al*. Early intervention with high-dose steroid pulse therapy prolongs disease-free interval of severe alopecia areata: A retrospective study. Ann Dermatol 2013;25:471-4.
50. Lu HA, Yang CC, Chen YC. Three monthly doses of corticosteroid pulse therapy yields a satisfactory but temporary response in severe alopecia areata patients. Dermatol Sin 2022;40:178-81.
51. Lai VW, Chen G, Gin D, Sinclair R. Cyclosporine for moderate-to-severe alopecia areata: A double-blind, randomized, placebo-controlled clinical trial of efficacy and safety. J Am Acad Dermatol 2019;81:694-701.
52. Husein-ElAhmed H, Steinhoff M. Efficacy and predictive factors of cyclosporine A in alopecia areata: A systematic review with meta-analysis. J Dermatolog Treat 2022;33:1643-51.
53. Nowaczyk J, Makowska K, Rakowska A, Sikora M, Rudnicka L. Cyclosporine with and without systemic corticosteroids in treatment of alopecia areata: A systematic review. Dermatol Ther (Heidelb) 2020;10:387-99.
54. Phan K, Ramachandran V, Sebaratnam DF. Methotrexate for alopecia areata: A systematic review and meta-analysis. J Am Acad Dermatol 2019;80:120-7.e2.
55. Phan K, Lee G, Fischer G. Methotrexate in the treatment of paediatric alopecia areata: Retrospective case series and updated meta-analysis. Australas J Dermatol 2020;61:119-24.
56. King B, Ohyama M, Kwon O, Zlotogorski A, Ko J, Mesinkovska NA, *et al*. Two phase 3 trials of baricitinib for alopecia areata. N Engl J Med 2022;386:1687-99.
57. Senna M, Mostaghimi A, Ohyama M, Sinclair R, Dutronc Y, Wu WS, *et al.* Long-term efficacy and safety of baricitinib in patients with severe alopecia areata: 104-week results from BRAVE-AA1 and BRAVE-AA2. J Eur Acad Dermatol Venereol 2024;38:583-93.
58. King B, Zhang X, Harcha WG, Szepietowski JC, Shapiro J, Lynde C, *et al*. Efficacy and safety of ritlecitinib in adults and adolescents with alopecia areata: A randomised, double-blind, multicentre, phase 2b-3 trial. Lancet 2023;401:1518-29.
59. Long-Term Efficacy of Ritlecitinib up to Month 24 from the ALLEGRO Phase 2b/3 and Long-Term Phase 3 Clinical Studies in Alopecia Areata. Available from: https://eadvhighlights.com/medfyles/8-soung-allegro-lt-ritlecitinib-in-aa?switch_language=en. [Last accessed on 2024 Jan 23].
60. Dai YX, Yeh CP, Chen CC. Efficacy and safety of tofacitinib therapy in Asian patients with severe alopecia areata. Dermatol Sin 2020;38:3.
61. Chen YY, Lin SY, Chen YC, Yang CC, Lan CE. Low-dose tofacitinib for treating patients with severe alopecia areata: An efficient and cost-saving regimen. Eur J Dermatol 2019;29:667-9.
62. van der Schaar WW, Sillevis Smith JH. An evaluation of PUVA-therapy for alopecia areata. Dermatologica 1984;168:250-2.
63. Herz-Ruelas ME, Gomez-Flores M, Miranda-Maldonado I, Welsh E, Ocampo-Candiani J, Welsh O. Escalating dosimetry of UVA-1 in the treatment of alopecia areata. Int J Dermatol 2017;56:653-9.
64. Ly K, Smith MP, Thibodeaux QG, Beck KM, Liao W, Bhutani T. Beyond the booth: Excimer laser for cutaneous conditions. Dermatol Clin 2020;38:157-63.
65. Ohtsuki A, Hasegawa T, Komiyama E, Takagi A, Kawasaki J, Ikeda S. 308-nm excimer lamp for the treatment of alopecia areata: Clinical trial on 16 cases. Indian J Dermatol 2013;58:326.
66. Darwin E, Arora H, Hirt PA, Wikramanayake TC, Jimenez JJ. A review of monochromatic light devices for the treatment of alopecia areata. Lasers Med Sci 2018;33:435-44.
67. Gupta AK, Carviel JL. Meta-analysis of 308-nm excimer laser therapy for alopecia areata. J Dermatolog Treat 2021;32:526-9.
68. Lee JH, Eun SH, Kim SH, Ju HJ, Kim GM, Bae JM. Excimer laser/light treatment of alopecia areata: A systematic review and meta-analyses. Photodermatol Photoimmunol Photomed 2020;36:460-9.
69. Hsu TC, Lin TK, Hsu CK, Jou HJ, Yang CC. Excimer lamp as an effective alternative treatment for severe alopecia areata. Dermatol Sin 2015;33:151-3.
70. Mlacker S, Aldahan AS, Simmons BJ, Shah V, McNamara CA, Samarkandy S, *et al*. A review on laser and light-based therapies for alopecia areata. J Cosmet Laser Ther 2017;19:93-9.