Severe Asthma
Casebook
嚴重氣喘案例集

Table of Contents

Prologue 2

Chapter I. Diagnosis and management of severe asthma in Taiwan..... 6
- Taiwan Consensus Statement on the Diagnosis and Management of Severe Asthma 7

Chapter II. Uncontrolled asthma 16
- Uncontrolled asthma due to vocal cord dysfunction..... 18
- Uncontrolled asthma with fungal sensitization 26

Chapter III. Severe allergic asthma.....35
- Effect of omalizumab on immune modulation..... 37
- Severe Allergic Asthma..... 51

Chapter IV. Severe eosinophilic asthma 57
- Severe eosinophilic asthma 59
- Target therapy for severe eosinophilic asthma 64

Chapter V. Mixed allergic eosinophilic Severe asthma 69
- Mixed Allergic eosinophilic Severe asthma treated with omalizumab 72
- Mixed allergic eosinophilic severe asthma Case: Omalizumab to Mepolizumab..... 77
- Mixed allergic eosinophilic Severe asthma 84

Chapter VI. Severe Neutrophilic Asthma 91
- Neutrophilic Inflammation in Severe Asthma 94
- Bronchiectasis and Severe Neutrophilic Asthma 102

Asthma is an important chronic respiratory disorder in Taiwan as well as the rest of the world. The World Health Organization (WHO) estimates that 325 million people are affected by asthma worldwide. In recent years, there has been an increasing trend in the prevalence of asthma among adults in Taiwan. According to an analysis of the Taiwan National Health Insurance database, prevalence of asthma among residents older than 18 years has increased from 7.57% in 2000 to 10.57% in 2011. Consequently, substantial amounts of medical resources have been expended toward asthma care, and it has become a burden to society due to reduced productivity.

It has been well known that chronic airway inflammation may cause respiratory tract obstruction. It leads to wheezing, shortness of breath, chest tightness, coughing and other respiratory presentations. The manifestations of the disease, degrees of airway obstruction, and clinical symptoms differ among individuals. The severity of asthma in an individual also varies over time.

Severe asthma is defined as asthma that requires stage 4 or 5 treatments to prevent it from becoming"uncontrolled"or that which remains"uncontrolled"despite such treatments. Therefore, the differentiation between uncontrolled and severe asthma is relatively important.

Taiwan Society of Pulmonary and Critical Care Medicine therefore published this casebook of severe asthma to provide details on various asthma cases for primary care physicians to use as a reference. The physicians will be able to differentiate different phenotypes and treat the diverse types of severe asthma more precisely, thereby improving their care-giving capabilities. Hopefully you will enjoy reading this casebook.

Meng-Chih Lin, MD.

President, Taiwan Society of Pulmonary and Critical Care Medicine

Professor, Division of Pulmonary and Critical Care Medicine,
Vice superintendent, Kaohsiung Chang Gung Memorial Hospital,
Kaohsiung, Taiwan

Severe asthma is a high heterogeneous disease without a standard definition. It is usually defined by the patient's response to controller treatment, clinical symptoms, and changes in lung function. The diagnosis of severe asthma requires systematic, stepwise evaluations to ensure that each relevant step is monitored and executed.

The steps include medical history confirmation, differential diagnosis, medication adherence evaluation, drug administration method assessment, allergy evaluation, chest imaging, lung function and laboratory testing, and comorbidity assessment. These steps are described in the first chapter of this book. Based on the types of inflammation and clinical presentations, cases in the severe asthma casebook have been classified into: uncontrolled asthma, severe allergic asthma, severe eosinophilic asthma, mixed allergic eosinophilic severe asthma, and severe neutrophilic asthma.

The treatment strategies in this casebook are to be used as a reference by asthma care physicians when deciding the best treatment method for severe asthma and selecting the appropriate biological agents, such as anti-IgE or anti-IL-5, for escalation treatments. We hope that the publication of this casebook on severe asthma will help improve asthma care in Taiwan.

Hao-Chien Wang 王鶴健

Professor Hao-Chien Wang , MD. Ph. D

Chairman of the Respiratory Disorders Committee of TSPCCM

Deputy Director of the Department of Internal Medicine,
National Taiwan University Hospital

Severe asthma is the most serious and life-threatening form of asthma. Most people with asthma can manage their symptoms well with common treatment methods, such as use of a maintenance inhaler or a reliever inhaler. But patients with severe asthma struggle to manage their symptoms despite high medication doses.

Biologics, a new type of treatment, has been developed in recent years, which involves use of monoclonal antibodies, such as anti-IgE or anti-IL5. These treatments can dramatically improve the lives of patients with certain types of severe asthma as well as reduce their steroid dosages, leading to a better quality of life.

To help our colleagues manage the different types of severe asthma more effectively, this casebook on severe asthma was developed as a case-based learning module. Readers can learn from the Clinical Pearl in each case to improve their clinical practice skills. I sincerely hope that this compilation of cases will help physicians in their daily practice.

Professor Chau-Chyun Sheu

Editor in chief

Director of Critical Care Center, Kaohsiung Medical University Hospital, Kaohsiung, Taiwan

Chapter I

Diagnosis and management of severe asthma in Taiwan

TAIWAN CONSENSUS STATEMENT ON THE DIAGNOSIS AND MANAGEMENT OF SEVERE ASTHMA

Chau-Chyun Sheu[1], Ming-Cheng Chan[2]

[1]Kaohsiung Medical University Institutional Repository, Kaohsiung, Taiwan

[2]Taichung Veterans General Hospital, Taichung, Taiwan

Question 1: What are the definitions of uncontrolled, difficult-to-treat, and severe asthma?

Recommendation

We recommend adopting the GINA definitions for uncontrolled, difficult-to-treat, and severe asthma.

Uncontrolled asthma

- Defined as one or both of the following
  - Poor symptom control: ACT <20 or ACQ consistently ≥1.5.
  - Frequent exacerbations (≥ 2/year) requiring OCS or serious exacerbations (≥ 1/year) requiring hospitalization.

Difficult-to-treat asthma

- Defined as asthma that remains uncontrolled despite GINA step 4 or 5 treatment (e.g. medium- or high-dose inhaled corticosteroid [ICS] with a second controller; maintenance oral corticosteroid [OCS]), or that requires such treatment to maintain good symptom control and reduce the number of exacerbations.

Severe asthma

- Defined as asthma that remains difficult to treat (requiring GINA step 4 or 5 treatment) after correction for modifiable factors (adherence, inhaler technique, comorbidity, obesity, and smoking).
- The diagnosis should be retrospectively made after 3-6 months of optimized treatment.

- In 2014 ERS/ATS guidelines, severe asthma was defined as "asthma which requires treatment with high-dose ICS plus a second controller to prevent it from becoming uncontrolled or which remains uncontrolled despite this therapy."

Question 2: For patients with difficult-to-treat asthma, what evaluations and managements should be performed before making the diagnosis of severe asthma?

Recommendation

We recommend confirming the diagnosis of asthma, checking and correcting the inhaler technique and adherence, adjusting modifiable risk factors, and treating comorbidities in patients with difficult-to-treat asthma before confirming the diagnosis of severe asthma.

- In many cases, asthma may appear to be difficult to treat because of modifiable factors such as incorrect inhaler technique, poor adherence, smoking, comorbidities, or incorrect diagnosis.

Question 3: For patients with difficult-to-treat asthma, how to check their inhaler adherence and technique?

Recommendation

We recommend using a check list, including self-reporting from patients and direct observation through healthcare providers, to evaluate the inhaler technique and adherence.

The suggested check list

The Inhaler Adherence and Technique Check List		
Does the patient use the inhaler regularly? (from monitoring the prescription or dispensing records)	☐ Yes	☐ No
Does the patient use the inhaler regularly? (from patient interview)	☐ Yes	☐ No
Has the patient's inhaler technique been re-confirmed by a trained medical provider?	☐ Yes	☐ No
Does the patient use a spacer (if needed)?	☐ Yes	☐ No

Question 4: For patients with difficult-to-treat asthma, how to evaluate and correct their comorbidities and other modifiable risk factors?

Recommendation

We recommend using a check list to comprehensively evaluate the modifiable risk factors, including smoking status, exposures to environmental tobacco, allergens, and indoor and outdoor air pollutants. We also recommend using a check list to evaluate comorbidities, including chronic rhinosinusitis, COPD, bronchiectasis, OSA, cardiac diseases, GERD, anxiety and depression, and obesity.

The suggested check list

The Modifiable Risk Factors Check List		
	Patient has this factor?	Could be further modified?
Active smoking	☐ Yes ☐ No	☐ Yes ☐ No
Significant environmental exposures, including indoor/outdoor allergens and pollutants	☐ Yes ☐ No	☐ Yes ☐ No
Chronic rhinosinusitis	☐ Yes ☐ No	☐ Yes ☐ No
Chronic obstructive pulmonary disease	☐ Yes ☐ No	☐ Yes ☐ No
Bronchiectasis	☐ Yes ☐ No	☐ Yes ☐ No
Obstructive sleep apnea	☐ Yes ☐ No	☐ Yes ☐ No
Cardiac diseases	☐ Yes ☐ No	☐ Yes ☐ No
Gastroesophageal reflux disease	☐ Yes ☐ No	☐ Yes ☐ No
Anxiety and/or depression	☐ Yes ☐ No	☐ Yes ☐ No
Obesity	☐ Yes ☐ No	☐ Yes ☐ No

Question 5: For phenotyping patients with severe asthma, what biomarkers should be measured?

Recommendation

We recommend measuring serum IgE levels, blood eosinophil counts, and fractional exhaled nitric oxide (FeNO) for phenotyping severe asthma, and for guiding the biological treatment. These biomarkers should be measured at the diagnosis of severe asthma, or at least before the initiation of biological treatment.

- Blood eosinophil counts and FeNO are the most practical and useful biomarkers. Sputum eosinophil counts and serum periostin are also useful biomarkers for severe asthma, but are not available in most clinical settings. The combination of these biomarkers provides the best overall assessment of type 2 airway inflammation
- Serum IgE and allergy testing (skin tests or blood tests), together with allergen-driven symptoms, are important clues for the diagnosis of allergic asthma
- Type 2 airway inflammation is usually defined as one or more of the following: (1) blood eosinophil count ≥ 150 cells/μL; (2) sputum eosinophils ≥ 2%; (3) FeNO ≥ 20 ppb; and (4) asthma being clinically allergen-driven

Question 6: For patients with severe asthma, when is the right time to measure blood eosinophil counts?

Recommendation

We recommend measuring the blood eosinophil counts (1) at the diagnosis of asthma and before initiating the treatment, (2) when the asthma is uncontrolled, and (3) before the use of systemic corticosteroids.

- For better phenotyping of severe asthma, we recommend repeating the measurement of blood eosinophil count for up to 3 times (same for FeNO) before defining a non-type 2 asthma
- When patients are on maintenance OCS, we recommend measuring the blood eosinophil count at least 2 weeks at the lowest dose of OCS, or 4 weeks after acute exacerbation

Question 7: For patients with uncontrolled severe asthma, what non-biological treatments are recommended?

Recommendation

In consideration of availability and affordability, we recommend maximizing non-biological treatments (both non-pharmacological and pharmacological interventions) to achieve and maintain asthma control before applying biological agents. Non-pharmacological interventions include smoking cessation, physical exercise, healthy diet, weight loss, mucus clearance strategies, influenza vaccination, and allergen avoidance. Non-biological pharmacological add-on therapies include high-dose ICS, long-acting muscarinic antagonist (LAMA, tiotropium), leukotriene antagonist, macrolide, ICS-formoterol maintenance and reliever strategy (SMART), and OCS.

- Addition of LAMA treatment in patients with severe asthma may improve symptom control and reduce exacerbations. Subgroups with fixed or baseline airflow obstruction might preferentially respond to LAMA therapy
- Chronic macrolide therapy reduces asthma exacerbations regardless of eosinophilia. This therapy is currently classified as an off-label use. Possible adverse effects should be monitored
- While applying maintenance OCS for patients with uncontrolled severe asthma, the benefits should be weighed against the potential adverse effects, including immunosuppression and metabolic derangement

Question 8: For patients with uncontrolled severe asthma, what biological treatments are recommended?

Recommendation

For patients with uncontrolled severe asthma already receiving optimized non-biological treatments, we recommend initiating biological therapy to achieve and maintain asthma control and prevent exacerbations. The selection of biological agents (anti-IgE, anti-IL-5/anti-IL-5R, and anti-IL-4R) should be guided by clinical characteristics and biomarkers.

- For patients with severe allergic asthma, anti-IgE treatment (omalizumab) reduces exacerbations and hospitalizations, and improves symptom control, lung function, and quality of life. Baseline IgE level is used to guide the initiation of anti-IgE treatment but is not associated with treatment response. Higher blood eosinophil count ($\geq$ 260 cells/μL) and higher FeNO ($\geq$ 20 ppb) can predict a good treatment response

- For patients with severe eosinophilic asthma, anti-IL-5/anti-IL-5R treatment (mepolizumab and benralizumab) reduces exacerbations and hospitalizations, and improves lung function and quality of life. Particularly, in these patients with corticosteroid dependency, anti-IL5/anti-IL-5R are effective in reducing the maintenance OCS dose. The blood eosinophil count is a strong predictor of response to anti IL-5/anti-IL-5R treatment. Higher blood eosinophil counts predict a better response. Nasal polyposis, higher maintenance OCS dose, and higher exacerbation frequency also predict a good treatment response
- For patients with severe eosinophilic asthma or corticosteroid-dependent asthma regardless of eosinophil levels, anti-IL-4R treatment (dupilumab) reduces exacerbations, and improves symptom control, lung function, and quality of life. Higher blood eosinophil counts and higher FeNO predict a good treatment response

Chapter II

Uncontrolled asthma

Uncontrolled asthma

Uncontrolled asthma is a condition that is difficult to treat despite treatment according to the Global Initiative for Asthma (GINA) Step 4 or 5, or one that requires such treatment to maintain good symptom control and reduce the risk of exacerbation. Asthma may appear to be difficult to treat in several cases because of modifiable factors such as incorrect inhaler technique, poor adherence, smoking or comorbidities, intrinsically severe asthma biology, other factors responsible for symptom exacerbation, or incorrect diagnosis. In this chapter, Dr. Shen introduces the first case of misdiagnosis of vocal cord dysfunction (VCD) as asthma. The clinical assessment and diagnostic approach for VCD have been reported comprehensively. Dr. Chen also introduces another case of severe asthma with fungal sensitization (SAFS). The diagnostic criteria for SAFS are reviewed, and the clinical course and treatment for SAFS are also reported. We hope that pulmonologists can comprehensively assess all patients with uncontrolled asthma and optimize the clinical management of asthma with the help of these case descriptions.

Hsin-Kuo Ko
Taipei Veterans General Hospital, Taipei, Taiwan

UNCONTROLLED ASTHMA DUE TO VOCAL CORD DYSFUNCTION

Sheng-Yeh Shen

Mackay Memorial Hospital, Taipei, Taiwan

Clinical presentation

- 26 year-old woman
- Height: 161 cm. Weight : 75 kg; BMI: 28.9 kg/m^2
- Occupation: Customer service (office)
- Asthma and seasonal allergic rhinitis diagnosed in her childhood
- Step-up treatment including high dose ICS/LABA, LTRA for asthma and antihistamine for allergic rhinitis from a medical center for more than one year
- Shortness of breath, dyspnea on exertion during the day
- Occasional audible respiratory sounds during exercise
- History of respiratory failure requiring intubation with ventilatory support on six occasions and Bi-PAP support on eight occasions from October, 2013 to April, 2016

Evaluation

Modifiable risk factors

- Medication: adequate inhaler technique and good adherence with controller therapy
- No history of drug allergy; no history of aspirin-or non-steroidal anti-inflammatory drug (NSAID)-induced exacerbation
- Exposure: non-smoker; no home pets

Co-morbidities

- Allergic rhinitis with nasal polyps
- No history of gastroesophageal reflux disease (GERD)

Lung function tests

Table 1. Lung function tests (2016/12/13)

Parameter	Values		
	Pre-BD	Post-BD	%Change
FVC (%pred)	81%	89%	9%
FEV_1 (%pred)	76%	90%	18%
FEV_1/FVC (%)	81%	87%	-
$FEF_{25\%-75\%}$ (%pred)	64%	101%	57%
BD response (L, FEV_1)	2.26L	2.67L	18%

Laboratory tests

- Blood eosinophils
  - ◈ 189 cells/μL (2013/10/25)
  - ◈ 344 cells/μL (2015/07/25) during exacerbation (emergency room visit)
- Allergen testing (2014/12/17)

檢驗項目	單位	Class
d1 D. pteronyssinus (屋塵蹣)	0.58 kU/l	Class 1
d2 D. farinae (粉塵蹣)	0.47 kU/l	Class 1
e1 Cat dander (貓毛)	0.01 kU/l	Class 0
e5 Dog dander (狗毛)	0.01kU/l	Class 0
i6 Cockroach (德國蟑螂)	0.02kU/l	Class 0
f1 Egg white (蛋白)	0.00kU/l	Class 0
f2 Milk (牛奶)	0.02kU/l	Class 0
f3 Cod Fish (鱈)	0.00kU/l	Class 0

- Total IgE: 3 kU/l (2014/12/17)

Imaging studies

- Chest radiograph and computed tomography (CT) scans (2014/8/15): no abnormality of structures (Figure 1a-1c)

Figure 1. Chest X-ray and computed tomography scan of chest

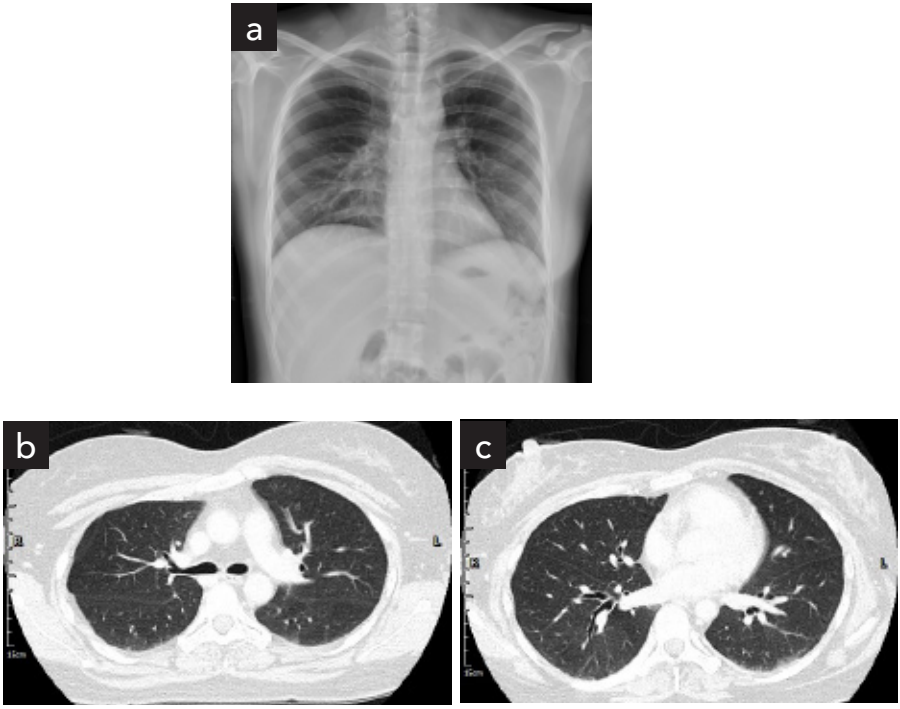

Figure 2. Skull PA view and Water's view (2014/11/19): left nasal polyp (Figure 2a-2b)

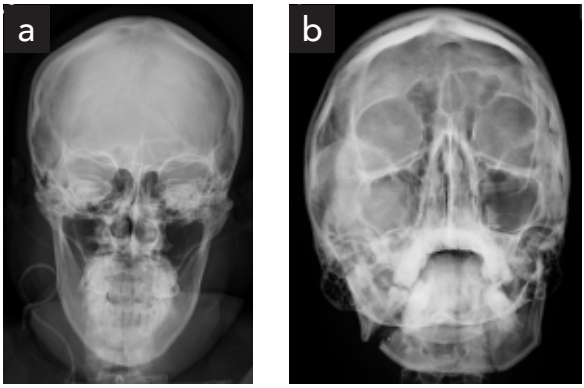

Laryngoscopy examination by ENT specialist (after 3rd intubation) (2014/5/16); (Figure 3a-3c)

Figure 3. Limited and paradoxical movement of vocal cords

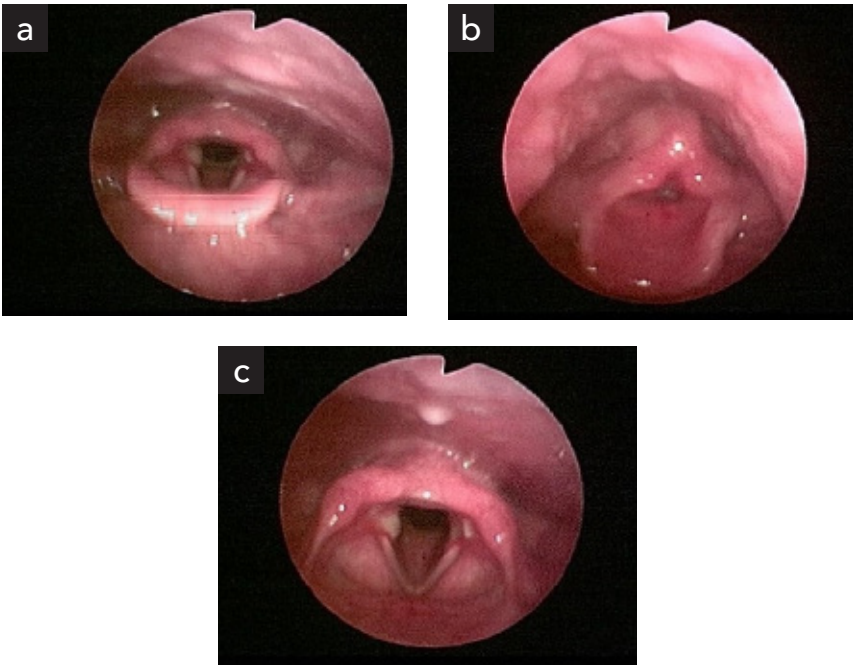

Bronchoscopy and bronchoalveolar lavage (BAL) analysis (2015/5/13)

- No endobronchial lesion
- BAL cellular analysis (Table 3)

Table 3. Bronchoalveolar lavage analysis

Cell type	Differential cell counts
Neutrophil	76%
Lymphocyte	8%
Eosinophil	0%
Mesothelial cell+ Histocyte + Monocyte	16%

Assessment

Severe asthma diagnosis and assessment were based on

- Symptoms and pulmonary function test (PFT)-confirmed asthma
- Review of inhaler technique and adherence
- Management of comorbidities (allergic rhinitis, nasal polyps, and exclusion of GERD)
- Multiple episodes of respiratory failure persisted despite high-dose ICS/LABA and LTRA, and even following add-on LAMA therapy

Uncontrolled asthma related to upper airway abnormality (vocal cord dysfunction) is likely, based on

- On review of her medical records and images, there was no obvious wheezing during her attacks of asthma
- According to her bedside statement, she had more difficulty breathing in than breathing out

Management and Clinical Course

- Treatment with Seretide evohaler (125 µg) 2 puff twice daily, Spiriva SMI 2 puff daily, and Singulair 10mg QHS
- Adjust life style and neurology (Betahistine 12 mg twice daily for vertigo) & psychiatry follow-up (suggest speech therapy)

Clinical pearls

- Asthma is a heterogeneous disease and upper airway disease, e.g. vocal cord dysfunction (VCD) may coexist with or masquerade as asthma.
- Misdiagnosis of VCD as asthma leads to inappropriate use of systemic steroids with its adverse effects, frequent emergency department visits, hospitalization, and, rarely, intubation and tracheostomy.
- Attenuation of the inspiratory flow volume loop on spirometry is suggestive of VCD. However, when patients are not having symptoms, it may reveal a normal test result.
- Laryngoscopic demonstration of the paradoxical vocal cord movements during an acute attack is the gold standard for the diagnosis of VCD[1].
- Patient education, managing allergic rhinitis and GERD, speech therapy, and psychological counseling are the therapeutic options.
- VCD is an important, not uncommon (25% reported in severe asthma)[2], respiratory disorder that should be included in the differential diagnosis of refractory asthma.

Abbreviation

FVC, forced vital capacity; FEV_1, forced expiratory volume in 1 second; $FEF_{25\%-75\%}$, forced expiratory flow at 25-75% of the pulmonary volume;BD, bronchodilator

Reference

1.Bahrainwala AH, Simon MR. Wheezing and vocal cord dysfunction mimicking asthma. Current Opinion in Pulmonary Medicine 2001,7:8–13

2.Parsons JP, Benninger C, Hawley MP et al. Vocal cord dysfunction: Beyond severe asthma. Respiratory Medicine 2010,104:504-509

UNCONTROLLED ASTHMA WITH FUNGAL SENSITIZATION

Kuan-Yuan Chen

Taipei Medical University-Shuang Ho Hospital,
Ministry of Health and Welfare, Taipei, Taiwan

Clinical presentation

- 44 year-old male
- Height: 176 cm, Weight: 60 kg; BMI: 19.4 kg/m^2
- Occupation: salesperson
- Asthma diagnosis: variable severity of respiratory symptoms and PFT with obstructive pattern and positive bronchodilator test since 2016
- Treatment: regular use of Seretide 250 Evohaler (fluticasone propionate 250 ug/ salmeteroal 25 ug) 2 puff q12h, Singulair 10 mg/tablet QD, Clarinase 120/5 mg/tablet BID, Nasonex 7 mg/bot QD, and famotidine 20 mg/tablet bid at chest OPD
- Uncontrolled asthma:persistent dyspnea and tenacious secretions noticed (ACT 13-15), and worsening of symptoms relieved by short course of oral steroids and antibiotics (5 to 6 times/year)

Evaluation

Modifiable risk factors

- Medication
  - ◈ Correct inhaler technique and good adherence with controller therapy
  - ◈ History of multiple drug allergies including NSAIDs and many kinds of antibiotics with allergic manifestation of skin rash but no significant respiratory symptoms
  - ◈ Exposure: ex-smoker, no pets, no seasonal or event-related exacerbation

Co-morbidities

- ◈ Allergic rhinitis without nasal polyps
- ◈ GERD(Gastro-esophageal reflux disease)
- ◈ No history of anxiety/depression or obstructive sleep apnea

Lung function tests

Table 1. Lung function tests (2016/04/07)

Parameter	Values		
	Pre-BD	Post-BD	%Change
FVC (%pred)	65.2%	69.9%	-
FEV_1 (%pred)	46.6%	63.7%	-
FEV_1/FVC (%)	59.02%	75.23%	-
$FEF_{25\%-75\%}$ (%pred)	52.2%	57.3%	-
BD response (L, FEV_1)	1.80 L	2.46 L	36.7%

Laboratory data (2016/04/07)

- Blood eosinophil: 1232 cells/μL
- Total IgE level: 569.8 KU/mL

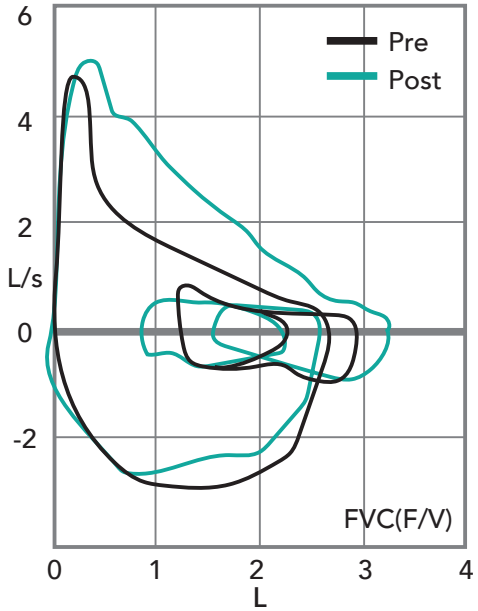

- CAP panel: multiple allergen positivity including Dermatophagoides pteronyssinus, German cockroach, cat dander, Candida albicans, and shrimp

Radiological data (2016/04/12)(1a),(2018/03/21) (Figure 1b-1d)

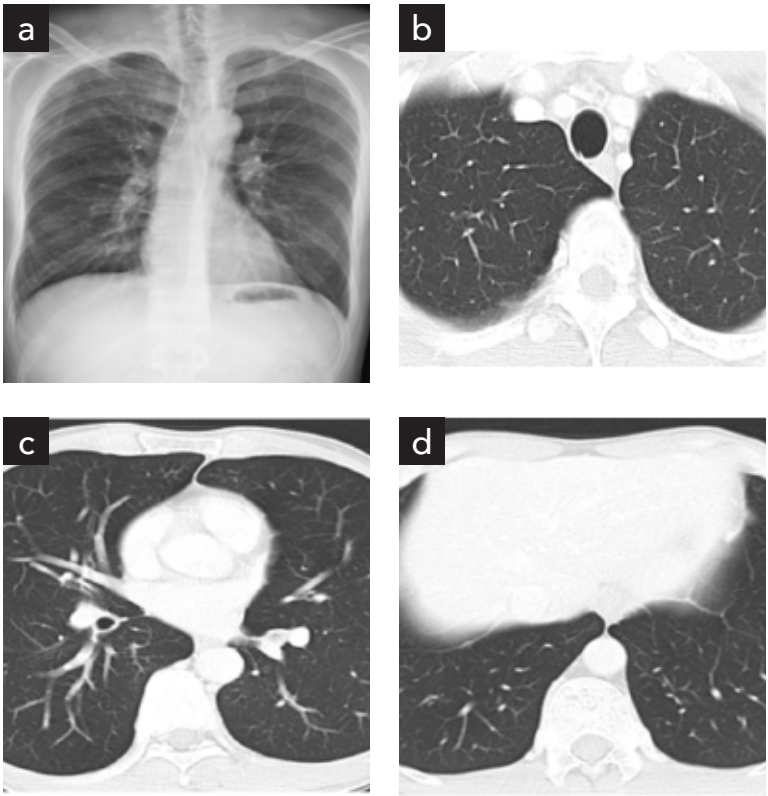

No significant central bronchiectasis

Bronchoscopy examination and bronchoalveolar lavage (BAL) analysis (2018/03/22) (Figure 2a-2d)

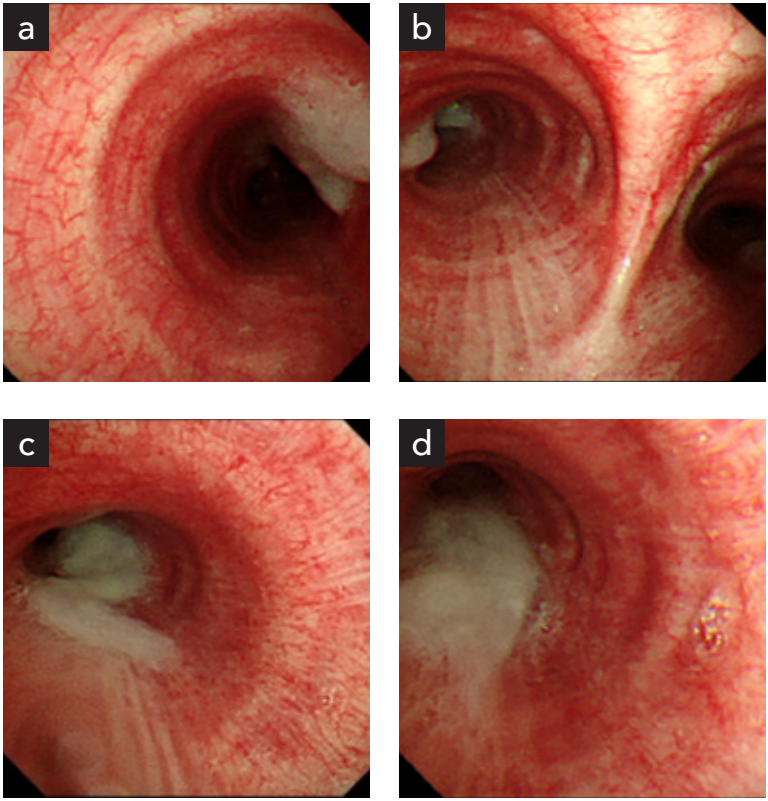

- No vocal cord dysfunction
- Profuse mucus plugs noticed in accessible airways

BAL cellular analysis

Cell type	Differential cell counts
Neutrophil	7%
Lymphocyte	14%
Eosinophil	1%
Mesothelial cell+ Histocyte + Monocyte	78%

BAL culture: *Candida albicans*

Assessment

Difficult-to-treat asthma was diagnosed based on

- Symptoms and PFT-confirmed asthma
- Review of inhaler technique and adherence
- Avoiding exposure to allergens measured positive by CAP test
- Management of comorbidity: LTRA and intra-nasal steroid for allergic rhinitis and H2-blockade for GERD
- Persistent poor symptoms control and asthma exacerbation under high-dose ICS/LABA therapy and persistent eosinophilia

Uncontrolled asthma with fungal sensitization was diagnosed based on

- Fungal sensitization with positive results of *Candida albicans-specific IgE*
- Exclusion of allergic bronchopulmonary aspergillosis with central bronchiectasis (ABPA-CB) due to normal HRCT and allergic bronchopulmonary aspergillosis-serosensitivity (ABPA-S) due to negative results of Aspergillus fumigatus-specific IgE as well as total IgE count < 1000 IU/mL

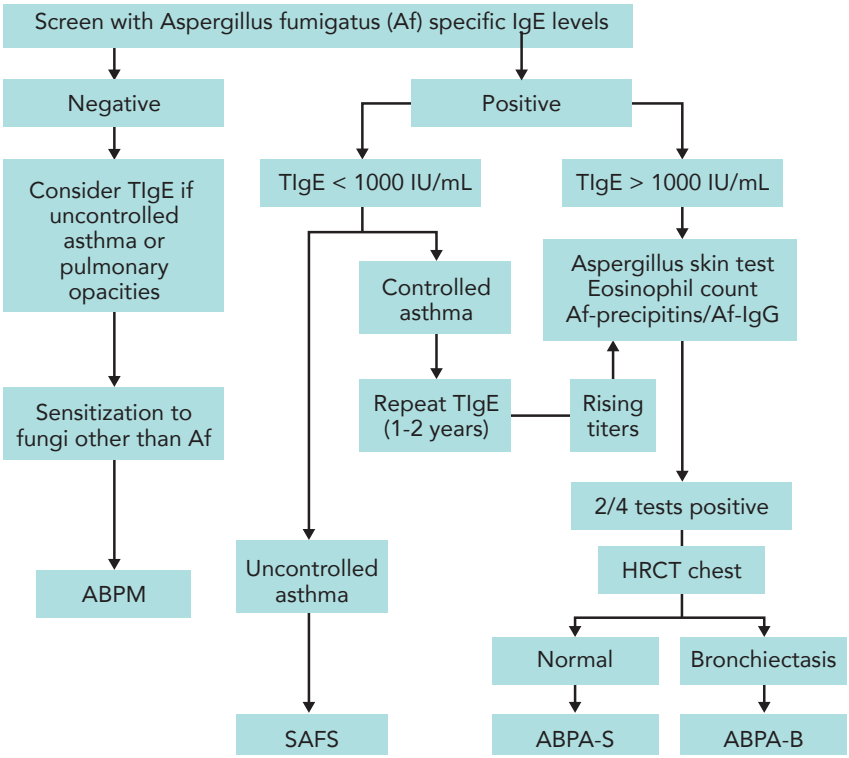

Figure [ABPM: allergic bronchopulmonary mycosis, ABPA-S: seropositive; Clin Exp Allergy 2013;43:850;TIgE, total IgE;Af, Aspergillus fumigatus;SAFS, severe asthma with fungal sensitization;ABPA-B, ABPA-bronchiectasis]

Management and Clinical Course

- Maintenance therapy for asthma with high-dose ICS/LABA and comorbidity treatment with LTRA and intra-nasal steroid CS for allergic rhinitis as well as H2-blockade for GERD
- Oral steroid with low dose prednisolone 10 mg QD for asthma with persistent eosinophilic inflammation since 2016/6
- Anti-IgE therapy for allergic, severe, uncontrolled asthma for nearly one year (since 2016/11 to 2017/9) with partial clinical response measured by ACT score (from 15 to 17)
- Add-on itraconazole 100 mg QD for 3 months, then good clinical response measured by ACT score (from 17 to 23)

Clinical pearls

- Difficult-to-treat asthma is asthma that is poorly controlled despite treatment with high-dose inhaled glucocorticoids or other controllers, or that requires such treatment to remain well controlled. Severe asthma is a subset of difficult-to-treat asthma and excludes patients in whom difficult-to-treat asthma is improved with optimization of adherence, inhaler technique, and treatment of coexisting conditions.
- Management of difficult-to-treat asthma requires a multidisciplinary approach including identification of comorbidities and appropriate treatment. Among numerous comorbidities, severe asthma with fungal sensitization (SAFS) should be one to consider, particularly in the patients with a persistent higher level of blood IgE and eosinophils.
- SAFS can be understood as a continuum of fungal sensitization, with asthma at one end and ABPA at the other. It is diagnosed by the presence of severe asthma, fungal sensitization (skin prick test for fungus or fungus-specific IgE), and exclusion of ABPA.
- ABPA is confirmed by the presence of asthma, *A. fumigatus* sensitization (skin reactivity or *A. fumigatus*-specific IgE and/or IgG), total IgE > 1000 IU/mL; and usually is present with central bronchiectasis (CB) on a chest CT diagnosis of ABPA-CB. If patients fulfill the first three criteria but lack abnormalities on chest CT they are labeled as seropositive ABPA (ABPA-S).
- The presented case met the criteria with severe asthma, fungal sensitization (Candida albicans-specific IgE) and exclusion of ABPA (seronegative of *A. fumigatus*-specific IgE and total IgE < 1000 IU/mL)

- Clinical features of patients with asthma for considering SAFS is persistent type 2 inflammation even under high-dose ICS or dependence upon oral corticosteroids control. So, treatment of SAFS should be similar to that of severe asthma with type 2 inflammation including anti-IgE therapy. Itraconazole should be considered based on the findings in our presented case and several clinical trials; however the optimal dose and duration of azole therapy in SAFS is currently not clear.

Abbreviation

FVC, forced vital capacity; FEV_1, forced expiratory volume in 1 second; $FEF_{25\%-75\%}$, forced expiratory flow at 25-75% of the pulmonary volume;BD, bronchodilator

Reference

1.Israel E, Reddel HK. Severe and difficult-to-treat asthma in adults. N Engl J Med. 2017 Sep 7;377(10):965-976
2.Agarwal R. Severe asthma with fungal sensitization. Curr Allergy Asthma Rep. 2011 Oct;11(5):403-13
3.Denning DW, O'Driscoll BR, Powell G, Chew F, Atherton GT, Vyas A, Miles J, Morris J, Niven RM. Randomized controlled trial of oral antifungal treatment for severe asthma with fungal sensitization: The Fungal Asthma Sensitization Trial (FAST) study. Am J Respir Crit Care Med. 2009 Jan 1;179(1):11-8
4.Agarwal R, Chakrabarti A, Shah A, Gupta D, Meis JF, Guleria R, Moss R, Denning DW. ABPA complicating asthma ISHAM working group. Allergic Bronchopulmonary Aspergillosis: Review of Literature and Proposal of New Diagnostic and Classification Criteria. Clin Exp Allergy. 2013 Aug;43(8):850-73

Chapter III

Severe allergic asthma

Severe allergic asthma

Allergic asthma can be distinguished by the presence of a clinical allergic reaction and in vitro IgE response to specific aeroallergens. An inflammatory cascade can be triggered by IgE-mediated mast cell activation; production, mobilization, and activation of eosinophils and Th2 lymphocytes in the airways; and the production of IL-4, IL-5, and IL-13. These events can lead to bronchial constriction and mucus production with airway narrowing. Currently, ICS/LABA are used to ameliorate this inflammation and relive asthma symptoms. However, some patients still develop allergic asthma. Omalizumab is a monoclonal antibody, which not only binds to and neutralizes free IgE but also down-regulates the IgE receptors—(FcεRI)—on inflammatory and structural cells. Omalizumab is indicated as an adjunct therapy to improve asthma control in patients with severe allergic asthma who experience frequent daytime symptoms or night-time awakenings and have multiple documented episodes of severe asthma exacerbations. The two cases described herein could help pulmonologists to identify the optimal window for initiating omalizumab therapy in patients with severe allergic asthma, which could additionally confer the benefits of omalizumab-mediated immune modulation.

Sheng-hao Lin
Changhua Christian Hospital, Changhua, Taiwan

EFFECT OF OMALIZUMAB ON IMMUNE MODULATION

Po-Jui Chang

Chang Gung Memorail Hospital, Linkou, Taiwan

Clinical presentation

- 24 year-old female
- Height: 155 cm; Weight: 52 kg; BMI: 21.6 kg/m^2
- Occupation: Cleaner
- Asthma and allergic rhinitis noted since childhood
- Rhinorrhea with nasal stuffiness and sneezing
- Vulnerable to weather change (esp. in winter) and upper respiratory infection (URI)
- Cough with mucoid sputum production, predominantly at night and in the morning
- Family history: Mother with allergic asthma
- Treatment at a local medical department
  - Budesonide/formoterol Turbuhaler, regularly
  - Bursts of low dose oral steroids
  - Oral bronchodilators
- Side effects: Palpitations and hand tremors
- Physical examination
- HEENT
  - Under-eye bags and dark circles
  - No micrognathia or retrognathia
  - Thrush observed at the tongue base
  - Dry oral mucosa
  - Cobblestone appearance over the oropharyngeal mucosa
  - No dental malalignment
- Chest
  - No chest wall deformity or kyphoscoliosis
  - Breath sounds: Fine wheezes bilaterally; no crackles or rhonchi

Evaluation

Modifiable risk factors

- Proper inhaler technique for DPIs, but not MDIs
- Good adherence, primarily owing to troublesome symptoms
- No history of aspirin- or NSAIDs-induced exacerbation
- Exposure: Non-smoker; no pets; no beta-blocker usage

Co-morbidities

- Allergic rhinitis
- No history of anxiety or depression

Lung function tests

Table 1. Lung function tests (2016/6/24)

Parameter	Values		
	Pre-BD	Post-BD	%Change
FVC (%pred)	60%	69%	14%
FEV_1 (%pred)	65%	75%	15%
FEV_1/FVC (%)	107%	108%	1%
$FEF_{25\%-75\%}$ (%pred)	82%	97%	18%

Table 2. Lung function tests (2017/6/7)

Parameter	Values		
	Pre-BD	Post-BD	%Change
FVC (%pred)	62%	69%	11%
FEV_1 (%pred)	67%	75%	12%
FEV_1/FVC (%)	108%	109%	1%
$FEF_{25\%-75\%}$ (%pred)	99%	118%	19%

Laboratory tests

- Total IgE: 491 KU/L
- ECP: 20.7 mg/L
- Positive specific IgEs: *D. pteronyssinus*(屋塵蹣)、*D. farinae*(粉塵蹣)、*Blomia tropicalis*(熱帶無爪蹣)、*Candida albicans* (白色念珠菌)

Nasopharyngoscopy (Figure 1a-1d)

- Pale swelling of bilateral nasal mucosa, c/w allergic rhinitis
- Subglottic edema and hyperemia of bilateral arytenoid processes, c/w reflux laryngopharyngitis
- No vocal cord dysfunction

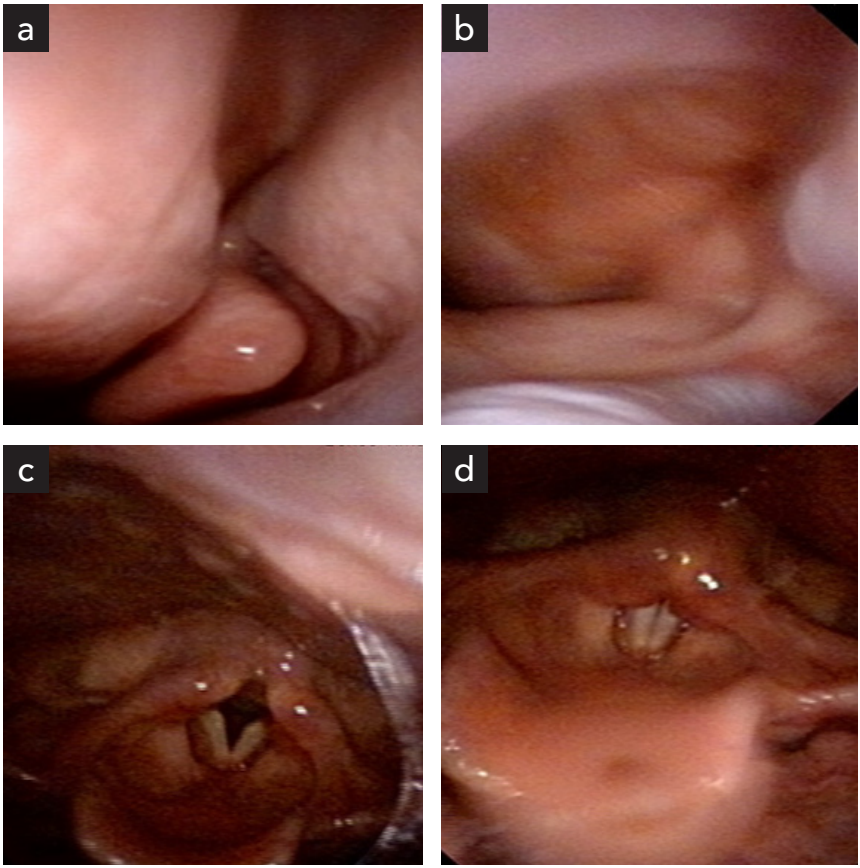
a
b
c
d

Chest X-ray

- Essentially normal

Treatment course

Initial medications

- Budesonide/formoterol (160/4.5) Turbuhaler 2 puff bid
- Fenoterol 2 puff prn
- Montelukast 10 mg hs
- Fexotenadine 180 mg QD

Subsequent additional medications for reflux laryngopharyngitis

- Mosapride 5 mg tid
- Esomeprazole 40 mg QD

Palpitations after budesonide/formoterol

Change budesonide/formoterol Turbuhaler to fluticasone propri-onate/salmeterol (FP/SAL) Accuhaler (250/50) 1 puff bid

Night attack of dyspnea after URI, with acid reflux and productive cough with increased sputum

- Prednisolone 10 mg QD x 7 days
- Clarithromycin 500 mg bid x 7 days
- Lansoprazole 30 mg QD x 14 days
- Add Tiotropium 2 puff QD for uncontrolled asthma

Frequent dyspnea attack with wheeze after URI

Prednisolone 10 mg QD x 7 days

Dyspnea attack with wheeze after URI, with copious sputum production

- Prednisolone 5 mg QD x 14 days
- Lansoprazole 30 mg QD x 14 days
- Levofloxacin 500 mg x 7 days

Average of 5-7 exacerbations/year, mostly precipitated by URI, despite medium-dose ICS/LABA plus additional agents

Not responsive to a temporary doubling dose of FP/SAL Accu-haler [(250/50) 2 puff bid]

Administration of omalizumab (600 mg qM)

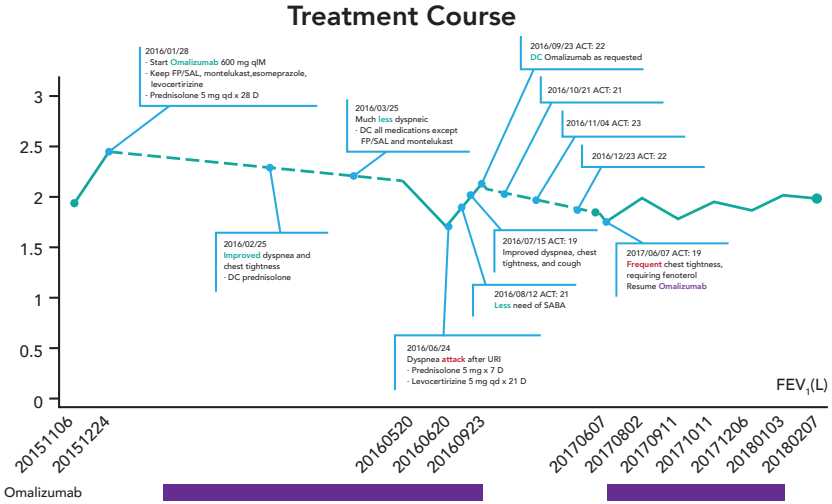

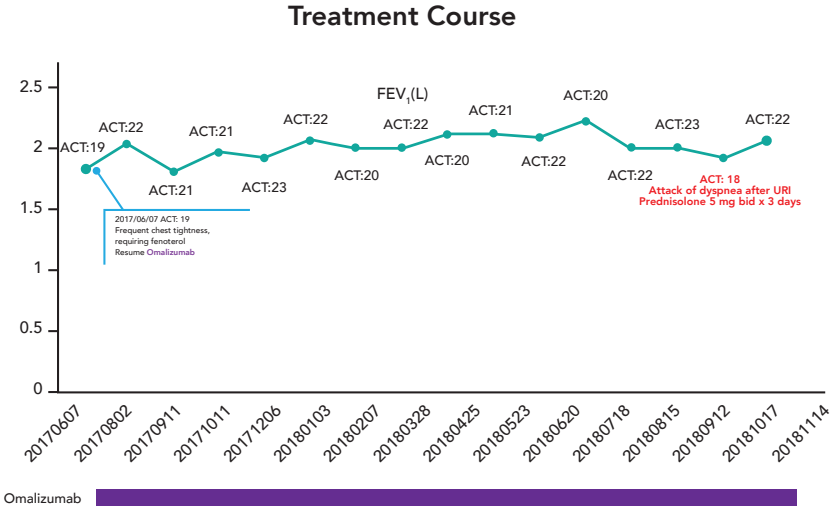

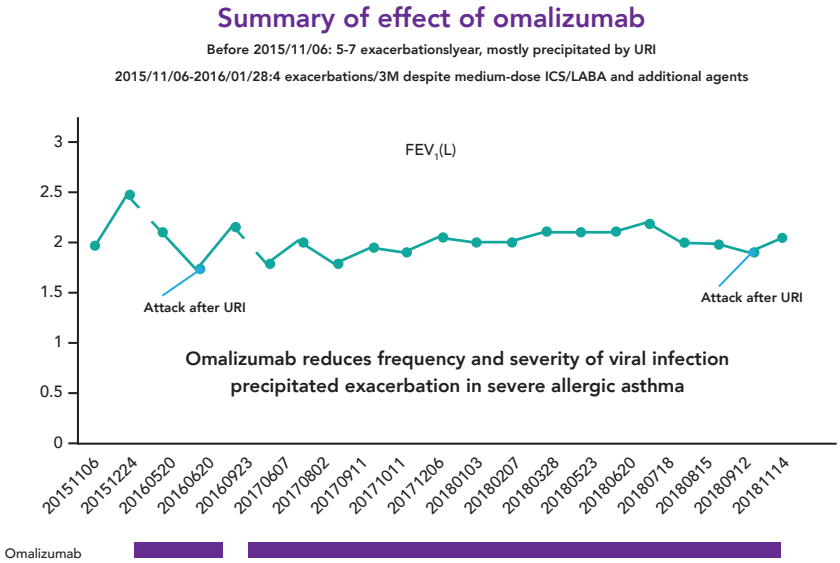

Summary

<u>A 24-year-old female cleaner with severe allergic asthma</u>

- Allergic phenotype
  - Early onset
  - Comorbid allergic rhinitis
  - Elevated total IgE and specific IgE for mites and candida
  - Family history of asthma
- Severe asthma
  - Poorly controlled symptoms with frequent exacerbations despite medium-dose (and temporary high-dose) ICS/LABA plus montelukast,and LAMA
  - Frequent viral infection
  - OCS responsive
  - Proper inhaler technique and adequate adherence
  - Other comorbidities: non-complicated GERD

- Good response to added-on omalizumab
  - Improved respiratory symptoms
  - Marked reduction of exacerbations
  - Marked reduction of frequency of viral infection

Discussion

- Increased risk and host susceptibility to infections in atopic and asthmatic patients

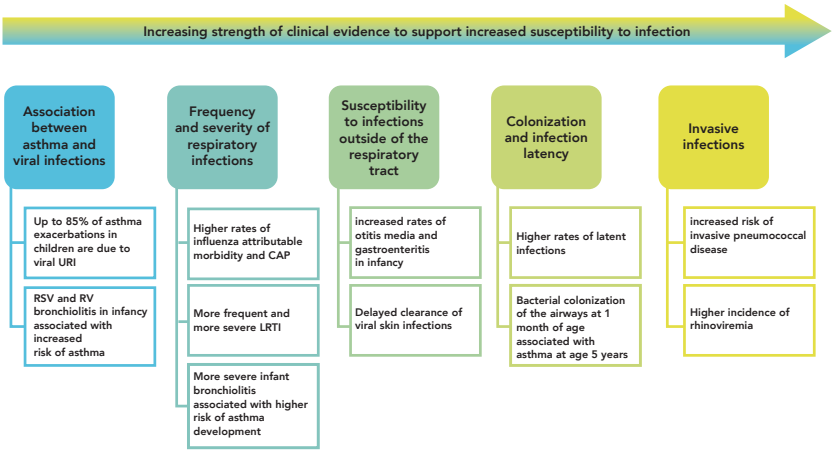

- Biological mechanisms underlying altered immune response to infections in atopic and asthmatic hosts

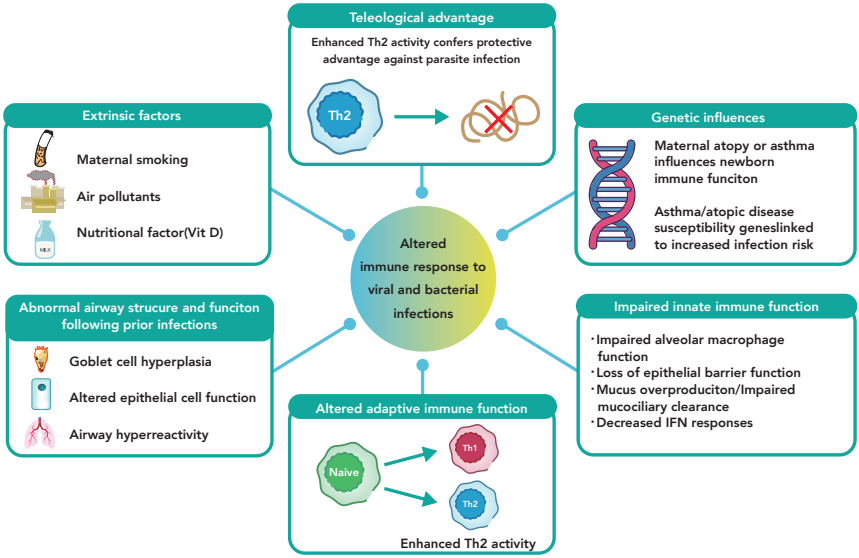

- Innate immunity of airways in response to viral infection

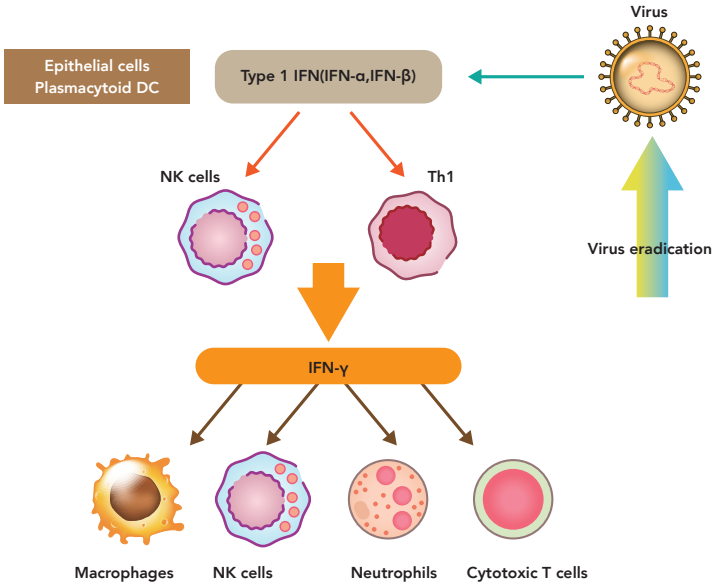

- Impaired TLR7 mediated anti-viral immunity in severe asthma

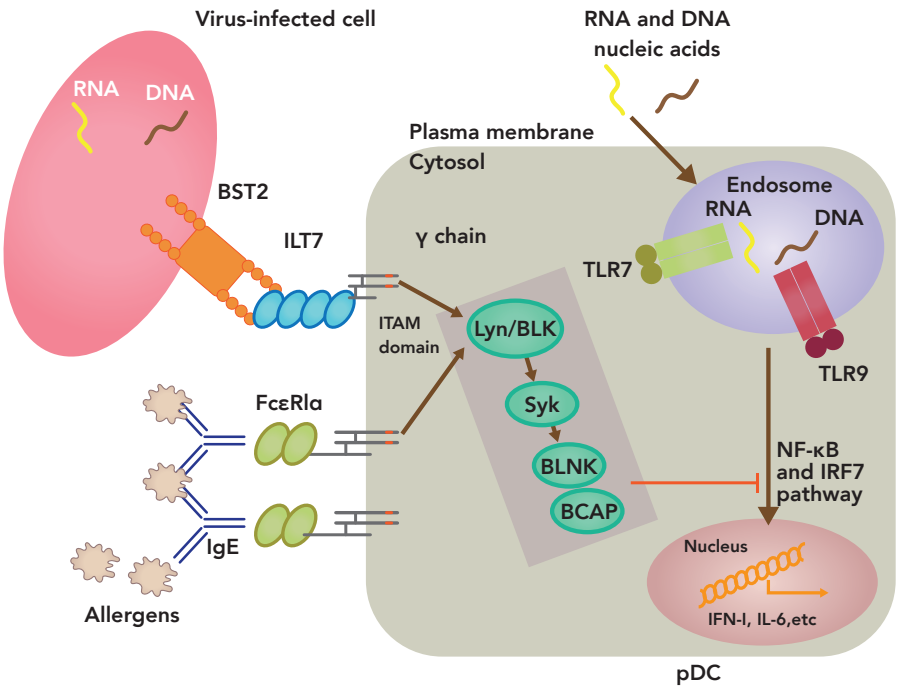

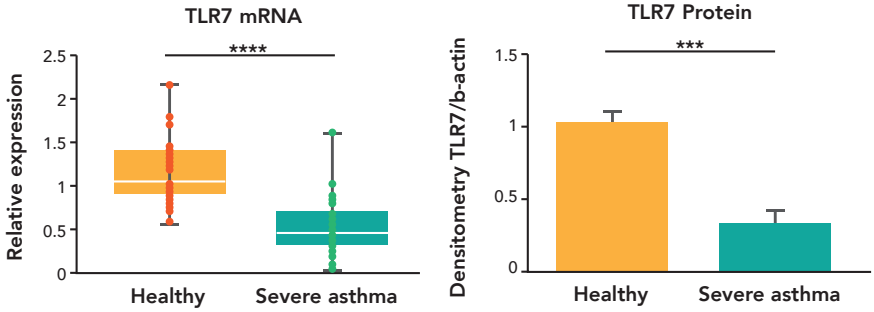

- Defective TLR7 and IgE –mediated impaired antiviral effect and amplified inflammation in severe allergic asthma

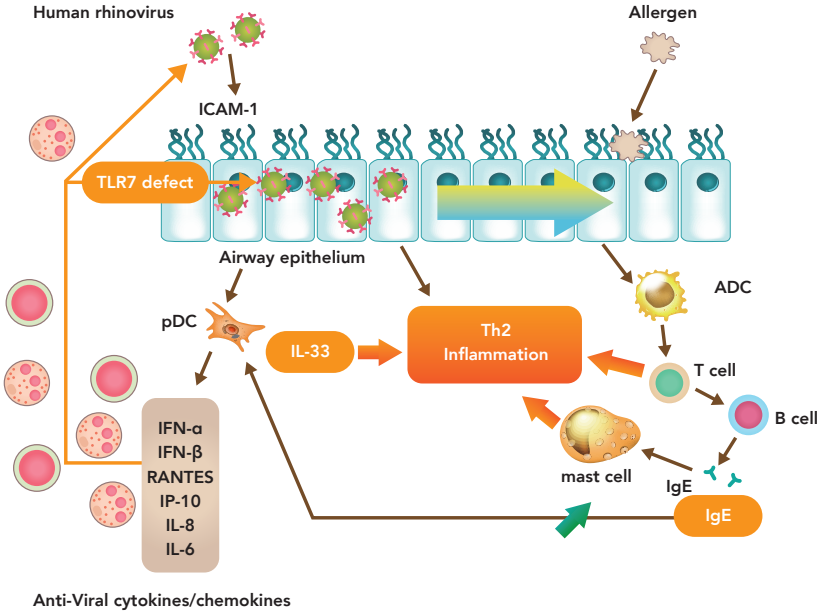

- Modulation of viral-induced IFN-α release in dendritic cells by IgE in asthma

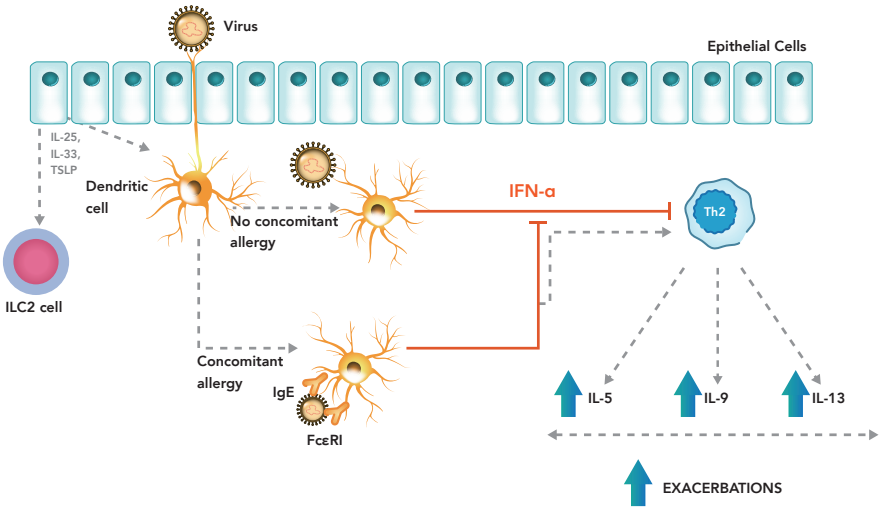

- Study demonstrating that short-term omalizumab administration before the fall season prevents viral-induced asthma exacerbations

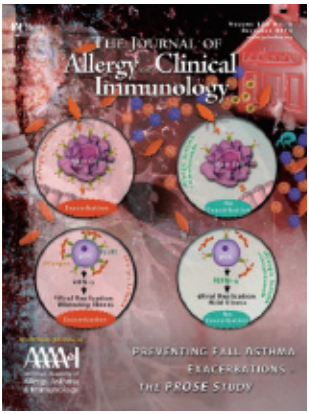

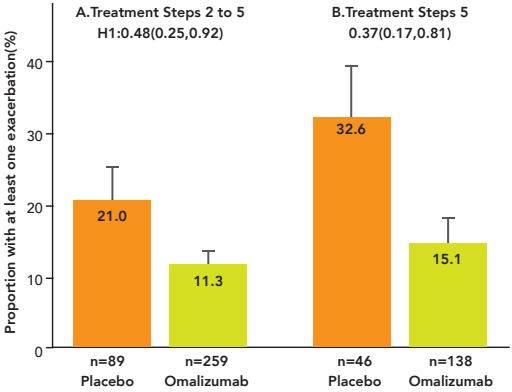

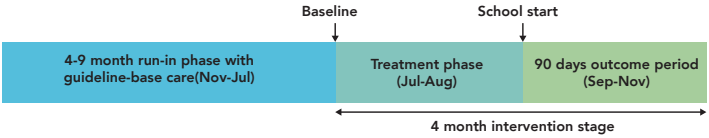

Clinical pearls

- Increased risk of susceptibility to viral infections in patients with allergic asthma
- Impaired innate immunity to viral infection in severe allergic asthma:
  - Defective TLR7
  - IgE-FcεR1 cross-link
- Anti-IgE, in addition to improving asthma control, decreases the frequency of exacerbations and viral infection in severe allergic asthma

Abbreviation

Pre-BD, pre-bronchodilator; FVC, forced vital capacity; FEV_1, forced expiratory volume in 1 second; $FEF_{25\%-75\%}$, forced expiratory flow at 25-75% of the pulmonary volume

SEVERE ALLERGIC ASTHMA

Wei-Chang Huang

Taichung Veterans General Hospital, Taichung, Taiwan

Clinical presentation

- 36 year-old woman
- Height: 153 cm; weight: 62 kg; BMI: 26.5 kg/m^2
- Occupation: employee at a videotape rental shop
- Had a family history of asthma (the patient's father and younger sister had a history of asthma)
- Diagnosed with asthma by pulmonary function test (PFT) at a medical center
- Regularly used Symbicort (budesonide/formoterol) and a leukotriene receptor antagonist (montelukast) as controllers, and was subsequently prescribed high-dose inhaled corticosteroids/long-acting β-agonists (ICS/LABA)
- Experienced frequent chest tightness and productive cough despite treatment, which resulted in five to six episodes of asthma exacerbation annually that required emergency department visits, and occasionally, hospitalization
- Experienced weight gain with appearance of moon face due to frequent use of systemic steroids for relief from asthma exacerbations

Evaluation

Modifiable risk factors

- Medication: correct inhaler technique and good adherence to controller therapy
- No history of drug allergy; no history of aspirin- or NSAIDs-induced exacerbation
- Exposure: non-smoker; having dog breeding; exacerbations happening frequently in the winter

Co-morbidities

- Allergic rhinitis
- Severe obstructive sleep apnea syndrome (OSAS)
- Ventricular septal defect
- No history of gastroesophageal reflux disease, anxiety, or depression

Lung function tests

Parameter	Values		
	Pre-BD	Post-BD	%Change
FVC (%pred)	85%	94%	11%
FEV_1 (%pred)	64%	76%	19%
FEV_1/FVC (%)	65%	70%	-
$FEF_{25\%-75\%}$ (%pred)	32%	36%	-
BD response (L, FEV_1)	1.65L	1.97L	19%

Laboratory tests

- White blood cell count: $12.1 \times 10^3/\mu L$
- Blood eosinophil percentage: 2.3%
- Total IgE: 532 IU/mL
- Allergen testing: strongly allergic to mite
- Polysomnography: apnea-hypopnea index, 34.1 per hour

Imaging studies (Figure 1a)

Chest radiograph: no remarkable finding

Assessment

Severe asthma was diagnosed based on

- Symptoms and PFT-confirmed asthma
- Review of inhaler technique and adherence
- Suggested to avoid exposure to dogs
- Suggested to clean-up the working place and bedroom
- Management of co-morbidity (allergic rhinitis and severe OSAS)

- Continued to experience poor symptoms control and frequent exacerbations despite treatment with high-dose ICS/LABA and montelukast

Severe allergic asthma was characterized based on

- Positive allergen test result
- Elevated blood level of total IgE
- Presence of comorbid allergic rhinitis

Management and Clinical Course

- High-dose ICS/LABA plus montelukast
- Prescription of Tiotropium should be cautious when patients were diagnosed as having VSD
- Add-on omalizumab showed excellent clinical success to reduce the number of exacerbations to zero and to spare the use of systemic steroids in the next year, eventually achieving good control of asthma symptoms
- Serial lung function

Date	FVC (L)	FVC (%pred)	FEV_1 (L)	FEV_1 (% pred)	FEV_1/FVC (%)
2014/03	2.54	85%	1.65	64%	65%
2015/10	2.34	78%	1.34	52%	57%
2016/09	2.68	91%	1.57	63%	59%
2017/01	2.59	89%	1.88	76%	73%

Clinical pearls

The patient had a typical diagnostic evaluation and treatment course for severe allergic asthma. Moreover, the patient manifested adverse effect of systemic steroid use (weight gain, appearance of moon face, and severe obstructive sleep apnea syndrome). These side-effects make physicians aware of the steroid-sparing effect of biological therapy in the management of severe allergic asthma.

Abbreviation

Pre-BD, pre-bronchodilator; FVC, forced vital capacity; FEV_1, forced expiratory volume in 1 second; $FEF_{25\%-75\%}$, forced expiratory flow at 25-75% of the pulmonary volume

Chapter IV

Severe eosinophilic asthma

Severe eosinophilic asthma

Eosinophilic asthma is now recognized as an important subphenotype of asthma based on the pattern of inflammatory infiltrate in the airway. Eosinophilic asthma, which is characterized by a high eosinophilic cell count in the induced sputum and peripheral blood, may be associated with increased asthma severity, atopy, late-onset disease, and steroid refractoriness. Airway eosinophilia and elevated eosinophil counts are associated with frequent asthma exacerbations, as well as with a high degree of airflow limitation and disease severity. Interleukin (IL)-5 is the main cytokine responsible for the activation of eosinophils; hence, therapeutic strategies have been investigated and developed for clinical use. Biologics targeting IL-5 and its receptors (first mepolizumab and subsequently, reslizumab and benralizumab) have recently been approved and used as add-on therapy for severe eosinophilic asthma, resulting in a reduction in the circulating eosinophil count, improvement in the lung function, and exacerbation reduction. In this chapter, we present two case reports of severe eosinophil asthma, wherein the patients benefited from mepolizumab therapy. We hope that pulmonologists are familiar with the management of severe eosinophilic asthma.

Ching-hsiung Lin
Changhua Christian Hospital, Changhua, Taiwan

SEVERE EOSINOPHILIC ASTHMA

Ching-Hsiung Lin

Changhua Christian Hospital, Changhua, Taiwan

Clinical presentation

- 61 year-old man
- Height: 168 cm, weight: 61 kg, BMI: 21.3 kg/m^2
- Occupation: Machinery factory manager
- PFT-documented asthma diagnosed since 2007
- Regular use of fluticasone propionate 250 ug/ salmeteroal xinafoate 25 ug (Seretide) and tiotropium bromide (Spiriva)
- Frequent exacerbation with tightness in the chest, wheezing and productive cough, and systemic corticosteroid use: 5-6 times per year

Evaluation

Modifiable risk factors

- Medication: Non-adherence to asthma controller
- The patient had a history of smoking 2 packs of cigarettes per week for 17 years and has quit smoking since then

Co-morbidities

- Allergic rhinitis with nasal polyps
- GERD with esophagitis

Lung function tests

Parameter	Values		
	Pre-BD	Post-BD	%Change
FVC (%pred)	102%	105%	-
FEV_1 (%pred)	104%	106%	-
FEV_1/FVC (%)	79%	80%	-
$FEF_{25\%-75\%}$ (%pred)	85%	88%	-
BD response (L, FEV_1)	3.17L	3.58L	13%

Laboratory tests

- Blood eosinophil: 738/μL
- Total IgE: 123 KU/L
- Allergen testing: D. pteronyssinus>0.35KU/L(with ImmunoCAP)

Imaging studies

- Chest radiography and CT: No specific findings
- Waters'view: Increased soft tissue in both maxillary sinuses, which indicated the possibility of maxillary sinusitis.

Assessment

The diagnosis of severe asthma was based on the following

- Confirmed asthma diagnosis based on clinical signs, symptoms, and evidence of variable air flow observation
- Identify and treat modifiable factors
  - Addressing non-adherence to controller medication
  - Reviewing inhaler technique

- Avoiding allergens, irritants, and medication triggers
- Multidisciplinary evaluation and treatment of comorbidities including allergic rhinitis and GERD
- Successful smoking cessation
- Add-on therapy with inhaled tiotropium and burst of oral corticosteroid
- Frequent exacerbations and poor symptom control

Characterization of mixed allergic eosinophilic severe asthma phenotype was based on the following

- Blood eosinophil count > 300/μL
- Positive allergen specific IgE level≥ 0.35 IU/mL (in response to a common perennial allergen)

Management and Clinical Course

- High-dose ICS/LABA and LAMA
- Suboptimal control by omalizumab due to≥ 2 exacerbations per year requiring treatment with systemic steroid after receiving omalizumab for > 4 months
- Switch to Mepolizumab for this mixed allergic eosinophilic phenotype severe asthma
- Eosinophil count decreased to 36 /μL after 2 courses of mepolizumab 100 mg, Q4W
- Good clinical response evidenced by an increase in the ACT score to 23~24, less than 2 exacerbations per year, and complete lack of systemic steroid therapy

Clinical pearls

- About one-quarter of patients in a Japanese cohort with severe asthma demonstrated an atopic/eosinophilic overlap.
- There is no clear optimal choice between anti-IgE and anti-IL5 therapy for patients with mixed allergic eosinophilic severe asthma owing to a lack of randomized controlled trials focusing on a direct comparison between anti-IgE and anti-IL5 therapies .
- An open-label study provided evidence that mepolizumab could effectively control severe asthma that was not optimally controlled with omalizumab in patients who were eligible for both biological agents.
- A real word study showed that omalizumab was effective for treating patients with severe allergic asthma, irrespective of the pre-treatment blood eosinophil count.
- The best therapeutic regimen for each individual patient is a challenging decision, despite the existence of different biologic therapies targeting different phenotypes.

Abbreviation

Pre-BD, pre-bronchodilator; FVC, forced vital capacity; FEV_1, forced expiratory volume in 1 second; $FEF_{25\%-75\%}$, forced expiratory flow at 25-75% of the pulmonary volume; FEF: forced expiratory flow, BD: bronchodilator

TARGET THERAPY FOR SEVERE EOSINOPHILIC ASTHMA

Shih-Lung Cheng

Far Eastern Memorial Hospital, Taipei, Taiwan

Clinical presentation

- 61 year-old woman
- Height: 162 cm; weight: 64 kg; BMI: 24.4 kg/m^2
- Occupation: Nil
- Diagnosed with asthma 10 years ago
- Regular use of budesonide and formoterol fumarate dihydrate (Symbicort) with a low-maintenance dose, which was stepped up to a high dose
- Chest tightness, dyspnea on exertion, and productive cough were frequent despite medication
- Frequent exacerbations occurred more than four times and she was admitted once due to a fatal asthma attack
- Audible wheezing

Evaluation

Modifiable risk factors

- Medication: correct inhaler technique and good adherence with controller therapy
- No history of drug allergies or aspirin- or non-steroidal anti-inflammatory drug-induced exacerbation
- Exposure: non-smoker, no pets, no seasonal or event-related exacerbation
- Asthma control test (ACT): 17, peak expiratory flow (PEF): 220 (best predicted: 340)

Co-morbidities

- Nasal polyps
- No history of gastroesophageal reflux disease (GERD), anxiety, or depression

Lung function tests

Parameter	Values		
	Pre-BD	Post-BD	%Change
FVC (%pred)	51%	65%	14%
FEV_1 (%pred)	58%	59%	-
FEV_1/FVC (%)	67%	66%	-
$FEF_{25\%-75\%}$ (%pred)	26%	34%	-
BD response (L, FEV_1)	1.28L	1.49L	210 mL

Laboratory tests

- Blood eosinophil count: 531.8/µL (12.1%)
- Total IgE: 74.8 KU/L
- Allergen testing: negative (with ImmunoCAP)

Imaging studies

- Chest radiography and computed tomography (CT): no specific findings
- Waters'view: no evidence of chronic sinusitis

Bronchoscopy examination

- No vocal cord dysfunction, airway distortion, or obstruction

Assessment

Severe asthma was diagnosed on the basis of the following

- Symptoms and asthma confirmed by pulmonary function tests (PFTs)
- Review of inhaler technique and adherence
- Management of comorbidity (allergic rhinitis, nasal polyp)
- Add-on inhaled tiotropium therapy for severe asthma
- Still poor symptoms control with high-dose ICS/LABA and LAMA therapy

Characterization of the eosinophilic phenotype of severe asthma was based on the following

- High blood eosinophil count
- Late onset of asthma
- Comorbidities such as nasal polyps

Management and Clinical Course

- Maintain high-dose ICS/LABA and LAMA therapy
- Apply-on anti-interleukin (IL)-5 therapy with mepolizumab for severe eosinophilic asthma
- Good clinical response and improvement in lung function
- No more attacks after 4 months of mepolizumab therapy
- Maintain 5-step therapy

Clinical pearls

- Severe asthma is a heterogeneous disease, which requires targeted treatment assessment according to the inflammatory phenotype.
- Severity, level of control, and phenotype stratification are intended for better management strategies for treating asthma.
- IL-5 plays a crucial role in the development, maturation, and action of eosinophils. Eosinophil count is a biomarker for predicting symptom control and exacerbation frequency in patients with severe eosinophilic asthma.
- Currently, patients treated with anti-IL-5 therapy (that decrease the eosinophil count) experience the positive effect of these drugs, especially with respect to the reduction in exacerbation rate.

Abbreviation

Pre-BD, pre-bronchodilator; FVC, forced vital capacity; FEV_1, forced expiratory volume in 1 second; $FEF_{25\%-75\%}$, forced expiratory flow at 25-75% of the pulmonary volume

Chapter V

Mixed allergic eosinophilic Severe asthma

Mixed allergic eosinophilic severe asthma managed by shifting from omalizumab to mepolizumab

Asthma is typically managed using both pharmacological and non-pharmacological approaches. Allergen avoidance is the main focus of the non-pharmacological approach. Pharmacological treatments include β2 agonists, inhaled corticosteroids, leukotriene receptor antagonists, long-acting anticholinergic agents, and theophylline. Most patients respond to these interventions, but some experience severe asthma refractory to the treatment, even at high doses. This is of particular concern among children, who are disproportionately affected.

Novel lines of research for treating severe asthma focus on cytokine production and pathways, including T-helper 2 (Th2) cells, type 2 innate lymphoid cells, interleukin 4 receptor alpha (IL-4Rα), IL-4, IL-5, IL-13, thymic stromal lymphopoietin, and non-Th2 pathways. Biological treatments specifically targeting these may help address asthma pathogenesis. Modern medicine is becoming more and more oriented toward tailored treatments designed for patterns of pathology observed in individual patients using endotypes with associated biomarkers, and biological treatments for asthma are an excellent example of this approach.

Among the biological drugs currently available, omalizumab is well-supported by data regarding efficacy and safety and has a good record of clinical experience. Mepolizumab will also soon be accessible globally for clinical use. These agents have yielded considerable reductions in exacerbation rates, increases in forced expiratory volume in 1 second, and reductions in inflammatory markers when used in patients with severe asthma refractory to available β2-agonists and/or inhaled corticosteroids. Guidelines are thus essential to determine the category of patients who can receive these agents, and biomarkers will be of use in aiding clinicians in making such determinations. In the cases described in this chapter, we cover patients with mixed allergic eosinophilic severe asthma who benefited from either omalizumab or mepolizumab therapy. Further study is needed to identify which agent is more beneficial to this phenotype of severe asthma.

Shih-Lung Cheng
Far Eastern Memorial Hospital, Taipei, Taiwan

MIXED ALLERGIC EOSINOPHILIC SEVERE ASTHMA TREATED WITH OMALIZUMAB

Yi-Hung Pan

Antai Medical Care Corporation Antai Hospital, Pingtung, Taiwan

Clinical presentation

- A 17-year-old girl presented with dry cough, exertional dyspnea, and chest tightness for several months
- Height: 160 cm; weight: 46 kg; BMI: 17.9 kg/m^2
- She was apparently diagnosed with asthma in childhood, but no maintenance therapy was prescribed
- Seasonal variations caused changes in the symptom severity
- Occupation: student
- Grandmother has a history of asthma
- Audible wheezing was heard on auscultation and negative post-bronchodilator test with high FEV_1 2.5% (50 mL)
- She was treated with medium dose inhaled corticosteroids/ long-acting β-agonists (ICS/LABA) for 2 years, which provided partial control of symptoms; however, she experienced an asthma attack while cleaning her house, which needed oral steroids for symptom relief. Since that episode, her asthma became uncontrolled with severe symptoms and poor peak flow PEF(peak expiratory flow) levels despite treatment with high dose ICS/LABA in combination with tiotropium and theophylline; she needed regular oral prednisolone (5 mg/day) for symptom relief.

Evaluation

Modifiable risk factors

- Exposure: non-smoker; no pets
  - ◈ Medication: correct inhaler technique and good adherence with controller therapy
- No history of drugs allergy; no history of aspirin use or NSAIDs-induced exacerbation

Co-morbidities

Allergic rhinitis and atopic dermatitis, which was treated by intra-nasal steroids, systemic anti-histamine, and montelukast

Lung function tests

Parameter	Values		
	Pre-BD	Post-BD	%Change
FVC (%pred)	62.3%	64.8%	-
FEV_1 (%pred)	61.8%	63.3%	-
FEV_1/FVC (%)	92.5%	97.9%	-
$FEF_{25\%-75\%}$ (%pred)	72.0%	65.3%	-
BD response (L, FEV_1)	1.97L	2.02L	2.5%

Laboratory tests

- Blood eosinophil: 508/μL (6.6%)
- Total IgE: 1388 KU/L
- Allergen testing: house dust mite (very high titer)

Imaging studies

Within normal limit.

Assessment

Severe asthma was diagnosed and the assessment were based on

- Symptoms and pulmonary function test-confirmed asthma
- Despite treatment with high-dose ICS/LABA and tiotropium, she continued to experience poor symptom control.
- Management of allergic rhinitis
- Routine oral prednisolone was needed to control the symptoms

Mixed allergic eosinophilic severe asthma was characterized based on

- High serum eosinophil count
- High IgE titer with specified allergen
- Coexisting allergic rhinitis and atopic dermatitis
- Family history of asthma

Management and Clinical Course

- She received omalizumab treatment, following which, she showed significant improvement in Asthma Control Test score (13 to >19) and peak expiratory flow (PEF; 220 mL to > 330 mL) within 2 months without any further need for oral prednisolone therapy.
- Inhaler treatment was tapered to medium dose ICS/LABA, with total control observed after 6 months.
- Montelukast and systemic anti-histamine were not needed for allergic symptoms after 8 months of omalizumab treatment

- Serial lung function

Date	FVC (L)	FVC (%pred)	FEV_1 (L)	FEV_1 (%pred)
2018/08	2.05	64.8	2.02	63.3
2019/05	2.81	87.3	2.6	79.5

Clinical pearls

- This case demonstrated the typical features of the allergic asthma phenotype (childhood-onset asthma; symptoms triggered by allergens; seasonal variations in symptom severity, atopic comorbidities; and family history of asthma)
- Although the patient has both atopic trait with high IgE titer and high serum eosinophil count, her disease characteristics were more indicative of severe allergic asthma.
- On literature review, omalizumab was reported to show good response in patients with blood eosinophils≥260/μL, FeNO≥20 parts-per-billion, allergen-driven symptoms, and childhood-onset asthma.
- In our case, as reported previously, omalizumab showed favorable response with good symptom control, improvement in lung function, and no further exacerbation of severe allergic asthma. These further led to the discontinuation of oral steroids.

Abbreviation

Pre-BD, pre-bronchodilator; FVC, forced vital capacity; FEV_1, forced expiratory volume in 1 second; $FEF_{25\%-75\%}$, forced expiratory flow at 25-75% of the pulmonary volume

MIXED ALLERGIC EOSINOPHILIC SEVERE ASTHMA CASE: OMALIZUMAB TO MEPOLIZUMAB

Chia-Hung Chen

China Medical University Hospital, Taichung, Taiwan

Clinical presentation

- 52 year-old male
- Height: 171 cm; weight: 83 kg; BMI: 28.3 kg/m^2
- Occupation: office worker (房屋仲介員)
- Bronchial asthma was diagnosed in 2009 and 250-μg fluticasone + 50-μg salmeterol (Seretide 250) ACCUHALER one puff twice a day was initiated.
- Following frequent chest tightness, dyspnea on exertion, and productive cough since June 2016, treatment was stepped up to 500-μg fluticasone + 50-μg salmeterol (Seretide 500) ACCUHALER one puff twice a day.
- After acute exacerbation was diagnosed in September 2016; thus, tiotropium (SPIRIVA® RESPIMAT®) two puffs once a day was added. At that time, the patient also sometimes required oral corticosteroids.
- Symptoms improved after Seretide 500 and SPIRIVA treatment for a short duration. Following this, frequent dyspnea and productive cough were noted from February 2017, and the patient was hospitalized once. Severe asthma was suspected and omalizumab (Xolair®) was initiated in August 2017.
- Symptoms improved after Xolair® treatment. However, frequent dyspnea, need reliever for resuscitation, and an emergency room (ER) visit occurred in May 2018 after 9 months of Xolair® treatment.

Evaluation

Modifiable risk factors

- Medication: correct inhaler technique and good adherence with controller therapy
- No history of drug allergy; no history of aspirin- or nonsteroidal anti-inflammatory drug-induced exacerbation
- Exposure: non-smoker; no pets; no seasonal or event-related exacerbation

Co-morbidities

- Allergic rhinitis with nasal polyps
- Gastroesophageal reflux disease being treated using proton pump inhibitors

Lung function tests

Parameter	Values		
May 2018	Pre-BD	Post-BD	%Change
FVC (%pred)	76.7%	74.2 %	-
FEV_1 (%pred)	73.8%	72.4 %	-
FEV_1/FVC (%)	74.9%	77.3%	-
$FEF_{25\%-75\%}$ (%pred)	52.1%	54.7%	-
BD response (L, FEV_1)	2.41L	2.37L	-1.7%

Laboratory tests

- Blood eosinophil count: 1500/μL
- Total IgE level: 457 IU/mL
- MAST allergen test

檢驗項目	報告值	Class
Cockroach Mix 蟑螂混合	133 LU	Class 2
Mite DF 美洲塵蟎	213 LU	Class 2
Mite DP 歐洲塵蟎	150 LU	Class 1

Imaging studies

- Chest radiograph computed tomography scans: bilateral, basal lung bronchiolar wall thickening, R/O bronchiolitis (Figure 1a-1c)

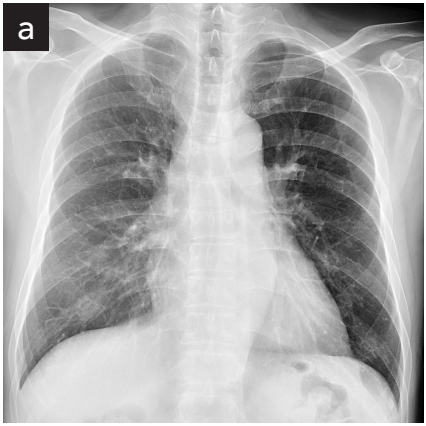

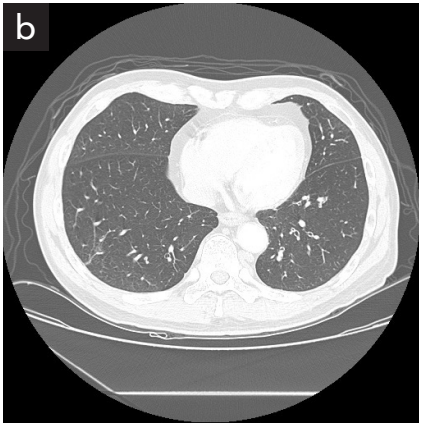

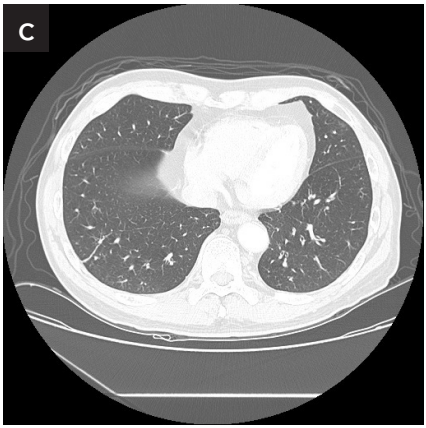

- Head computed tomography: mucus retention with mucosal thickening in the bilateral maxillary, ethmoid, and frontal sinuses; hypertrophy in bilateral inferior and middle turbinates; suspected chronic rhinosinusitis (Figure 2a-2b)

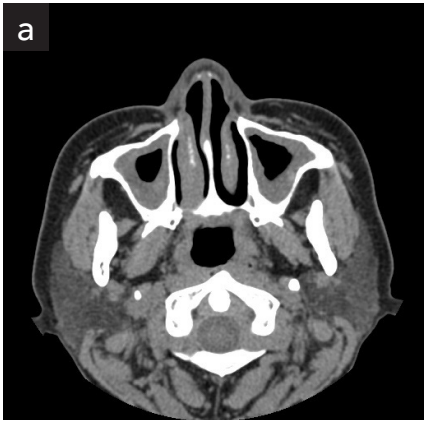

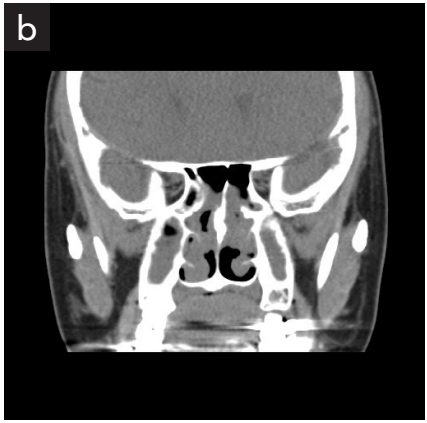

Assessment

Mixed allergic eosinophilic severe asthma was diagnosed according to

- Adult onset asthma mixed allergic eosinophilic severe asthma
- Fixed airflow obstruction often present with recurrent exacerbations
- High IgE titer and MAST allergen test(+)
- Blood eosinophilia
- Relative resistance to inhaled corticosteroids

Management and Clinical Course

- High-dose ICS/LABA/LAMA
- Mepolizumab (Nucala®; 100 mg once every 4 weeks) since May 2018 yielded a good clinical response and improved lung function.
- LAMA was discontinued and ICS/LABA was stepped up to a medium dose from August 2018.
- No more exacerbations occurred requiring ER visit/hospitalization or oral corticosteroid treatment after the switch from omalizumab to mepolizumab.
- Serial eosinophil count

Date	Eosinophil count/μL
2018/05	1500
2018/08	230

- Serial lung function

Date	FVC (L)	FVC (%pred)	FEV_1 (L)	FEV_1 (%pred)	FEV_1/FVC (%)
2018/05	3.11	74.2	2.37	72.4	74.9
2018/08	3.39	80.9	2.76	84.4	81.3

Clinical pearls

- Patients who whose asthma is not optimally managed with omalizumab and who are eligible for biological drugs could be effectively switched to mepolizumab to improve asthma control.
- After switching from omalizumab to mepolizumab, patients with uncontrolled mixed allergy eosinophilic severe asthma experienced clinically improvements in asthma control, health status, and exacerbation rate, with no tolerability issues.

Abbreviation

Pre-BD, pre-bronchodilator; FVC, forced vital capacity; FEV_1, forced expiratory volume in 1 second; $FEF_{25\%-75\%}$, forced expiratory flow at 25-75% of the pulmonary volume

MIXED ALLERGIC EOSINOPHILIC SEVERE ASTHMA

Chien-Wen Huang

Asia University Hospital, Taichung, Taiwan

Clinical presentation

- A 66 year-old housewife with a more than 3-year history of asthma
- Height: 157 cm; weight: 55 kg; BMI: 22.3 kg/m^2
- Non-smoker, without any occupational exposure to other irritating inhalants
- Family history of atopy and asthma; sister has a history of allergic rhinitis
- Onset of recurrent bronchitis with wheezing (more than 6 times/year), which was successfully treated with antibiotics and oral steroids over the last 3 years at a different clinic; severe exertional dyspnea and a recent presentation of audible wheezing on auscultation
- Despite previous treatment with medium dose of inhaled corticosteroids/long-acting β-agonists (ICS/LABA), prescribed by the previous general practitioner, she had poor control of respiratory symptoms
- Poor compliance to inhalation therapy

Evaluation

Modifiable risk factors

- Medication: correct inhaler technique and good adherence to controller therapy
- Poor compliance: education and communication

Co-morbidities

- Panendoscopy results showed the following: 1. Gastroesophageal Reflux Disease (GERD), Los Angeles grade B; 2. Chronic antral gastritis; and 3. Antral gastric ulcer
- Treatment: proton pump inhibitor by the gastrointestinal out-patient department
- Laryngoscopy results: mucous in the bilateral nasal cavity; vocal cord edema

Lung function tests

Parameter	Values		
	Pre-BD	Post-BD	%Change
FVC (%pred)	42%	49%	-
FEV_1 (%pred)	35%	35%	-
FEV_1/FVC (%)	70%	59%	-
$FEF_{25\%-75\%}$ (%pred)	18%	17%	-
BD response (L, FEV_1)	0.73L	0.72L	-

Impulse oscillometry

		Pred	Act1	%(A1/P)	Act2	%(A2/P)	% chg
VT	L	0.39	1.20	306	1.08	275	31.10
R5Hz	kPa/(L/s)	0.40	1.63	402	0.67	165	237.72
R20Hz	kPa/(L/s)	0.34	0.38	109	0.34	98	11.91
Di5-20	kPa/(L/s)		1.25		0.33		
X5Hz	kPa/(L/s)	-0.10	-0.96	1001	-0.47	492	508.66
Z5Hz	kPa/(L/s)	0.42	1.89	455	0.82	196	258.20

		Pred -0.15	Pred -0.3	Pred -0.45	Pred -0.6
X5Hz	kPa/(L/s)	-0.25	-0.40	-0.55	-0.70

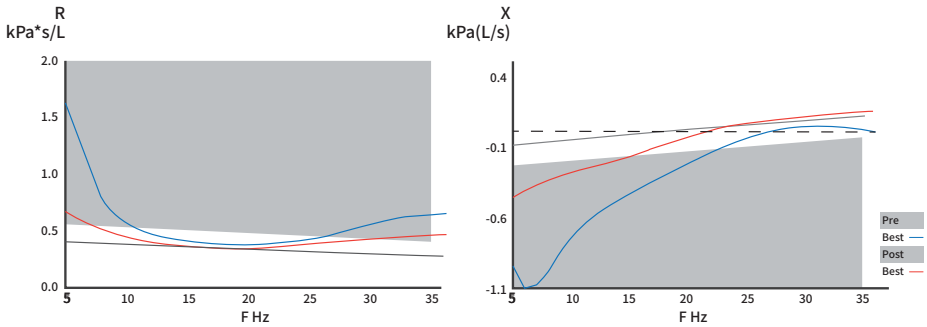

Comment

- R5-R20 = 1.25
- Pre R5%: 403.00%
- Post R5%: 165.65%
- X5: -0.96 kPa/(L/S)
- IOS analysis very severe obstructive
- IOS analysis very severe restrictive
- After bronchodilator, Pre R5% - Post R5% = 238% (Positive response)
- After bronchodilator, SpO_2: 95%

Laboratory tests

- Blood eosinophil: 1455/μL
- Total IgE: 186 KU/L
- Allergen testing: atopy and house dust mite sensitization by Multiple-antigen simultaneous test (MAST)

Imaging studies (Figure 1a-1b)

- Chest radiograph and computed tomography images: Mild bilateral bronchial wall thickening with peribronchial infiltrates and mild mucus plugging in the bilateral lower lung lobes.

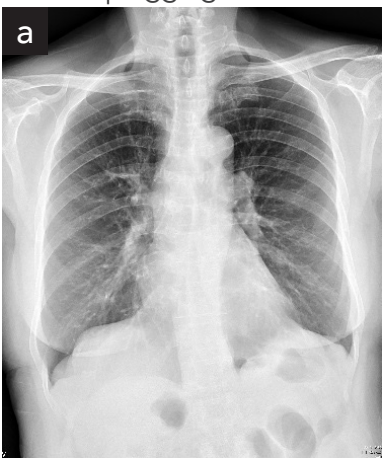

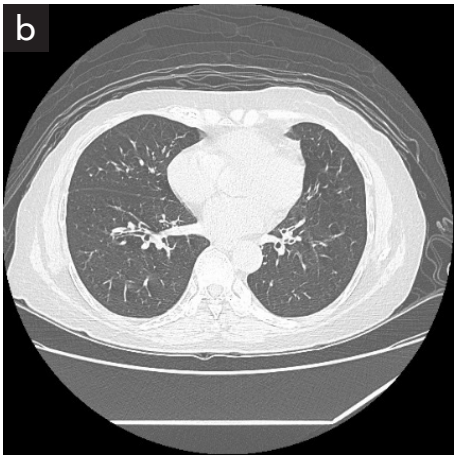

Assessment

Severe asthma diagnosis and assessment were based on

- Patient's clinical symptoms and results of lung function test confirmed a diagnosis of asthma
- Review of inhaler technique and adherence
- Management of comorbidity (allergic rhinitis and GERD)
- Despite treatment with high-dose ICS/LABA, patient continues to experience poor symptom control.

Mixed allergic eosinophilic severe asthma was diagnosed based on

- Allergic: Atopy and house dust mite sensitization by MAST; Total IgE, 186 KU/L
- Eosinophilic: blood eosinophil, 1455/μL

Management and Clinical Course

- Since the beginning of 2018/07, the patient received treatment in our hospital. Therapeutic drugs included Symbicort Turbuhaler (budesonide/formoterol; 160/4.5 2 puff; b.i.d.) and tiotropium bromide (2.5 mcg; 2 puff q.d.) since 2018/07. Although combining this treatment regimen with oral steroids, the distress symptoms and wheezing could not be controlled completely.
- During the 2018/07-2019/01 treatment period, because the symptoms of asthma persisted despite the use of inhaled drugs, oral steroid prednisolone (5 mg; 28 tab) was prescribed every month for more than half a year; nevertheless, she experienced 4 episodes of acute exacerbations.

- Mepolizumab therapy (Nucala), approved by NHIA, was initiated to treat severe asthma. The patient experienced no additional acute exacerbation after Nucala therapy, and therefore, oral steroids were discontinued. Compared with that previously, her symptoms and signs improved significantly after Nucala therapy. The oral steroid regimen was tapered since June 2019. Subsequently, oral steroid was completely discontinued in August 2019. The patient showed significant improvement in quality of life.

Clinical pearls

- Late-onset severe asthma, eosinophilic inflammatory pattern, and peripheral eosinophilia with atopy
- Poor outcome for standard spirometry; impulse oscillometry may have been beneficial for diagnosis
- In our patient with mixed allergic eosinophilic severe asthma, medications including inhalation therapy with ICS/LABA (twice/daily), tiotropium (2 puffs; q.d.), anti-leukotriene modifiers, anti-reflux therapy, antihistamine, oral steroid (prednisone; 5 mg) was prescribed; however, her symptoms persisted. After anti-IL 5 therapy, general condition improved gradually

Abbreviation

Pre-BD, pre-bronchodilator; FVC, forced vital capacity; FEV_1, forced expiratory volume in 1 second; $FEF_{25\%-75\%}$, forced expiratory flow at 25-75% of the pulmonary volume

Chapter VI

Severe neutrophilic asthma

Severe neutrophilic asthma

Severe neutrophilic asthma is a less well-characterized phenotype of severe asthma. Although it is sometimes categorized as"non-eosinophilic"asthma,coexisting eosinophilic inflammation and atopy are frequently seen.

Neutrophilic asthma is defined as >40–60% neutrophils in induced sputum but without consensus definition in other specimens. Features associated with this phenotype include late onset, low lung function (even with persistent airway obstruction), poor response to inhaled glucocorticoids, purulent mucus production, and bronchiectasis. Some patients have coexisting sinopulmonary infections; others report exposure to occupational or environmental sensitizers, including tobacco smoke and air pollution. Medical co-morbidities such as gastroesophageal reflux disease (GERD), hypertension, and diabetes are common. It is important to know that the presence of atopy does not exclude a neutrophilic phenotype in severe asthma.

In this section, Dr. Hsiao and Dr. Chen report two typical cases of severe neutrophilic asthma. Both patients were women with poorly controlled symptoms or frequent exacerbations on high dose inhaled corticosteroid and long-acting β2-agonist treatment with add-on tiotropium. Low lung function with poor reversibility was seen in both cases. It is likely that the reversibility of airway obstruction was gradually lost during the course of the disease. Both cases had allergic rhinitis and high blood eosiniphilic counts. The case presented by Dr. Hsiao also had coexisting bronchiectasis

and GERD, highlighting the importance of such co-morbidities. As sputum induction is not a routine test in Taiwan, the diagnosis of both cases relied on a bronchoalveolar lavage study via bronchoscopy. Both cases showed good response to macrolide treatment, one case with azithromycin and the other with low dose erythromycin. Macrolides, particularly azithromycin, are the most studied treatment for this phenotype of asthma. Other options with weaker strength of evidence are theophylline and PDE4 inhibitors. As neutrophilic asthma is usually mixed with other phenotypes, it could be considered a treatable trait and a part of treatment.

Kang-Yun Lee
Taipei Medical University-Shuang Ho Hospital, Ministry of Health and Welfare
Taipei, Taiwan

NEUTROPHILIC INFLAMMATION IN SEVERE ASTHMA

Kuan-Yuan Chen

Taipei Medical University-Shuang Ho Hospital,
Ministry of Health and Welfare, Taipei, Taiwan

Clinical presentation

- 47 year-old woman
- Height: 166 cm; weight: 55 kg; BMI: 19.9 kg/m^2
- Occupation: office worker
- Pulmonary function test (PFT)-confirmed asthma was diagnosed at a medical center
- Regularly used Symbicort (budesonide/formoterol) using at LMD, which was subsequently stepped-up to a higher dose
- Despite treatment, she continued to experience frequent chest tightness, exertional dyspnea, and productive cough.
- Audible wheezing

Evaluation

Modifiable risk factors

- Medication: showed correct inhaler technique and good adherence with controller therapy
- No history of drugs allergy; no history of aspirin- or NSAIDs-induced exacerbation
- Exposure: non-smoker; no pets; no seasonal or event-related exacerbation or change in symptom severity

Co-morbidities

- Allergic rhinitis with nasal polyps
- No history of gastroesophageal reflux disease (GERD), anxiety, or depression

Lung function tests

Parameter	Values		
	Pre-BD	Post-BD	%Change
FVC (%pred)	61%	65%	-
FEV_1 (%pred)	48%	52%	-
FEV_1/FVC (%)	67%	66%	-
$FEF_{25\%-75\%}$ (%pred)	26%	34%	-
BD response (L, FEV_1)	1.38L	1.47L	7%

Results of laboratory tests

- Blood eosinophil: 73.6/μL
- Total IgE: 132.4 KU/L
- Allergen testing: negative (by CAP)

Imaging studies

Findings on chest radiograph and computed tomography images: mild bilateral bronchial wall thickening with peribronchial infiltrates, and mild mucus plugging in the bilateral lower lung lobes. These findings were indicative of infective/inflammatory changes, such as bronchiolitis (Figure 1a-1c).

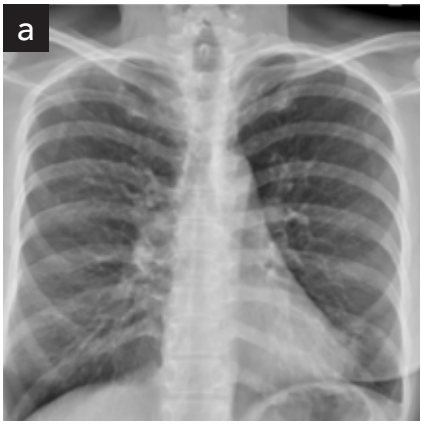

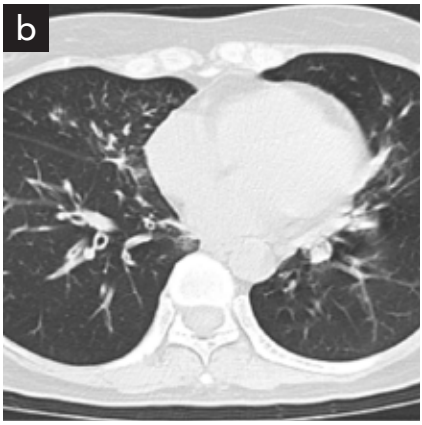

- Water's view: maxillary sinus wall thickening and opacity, indicative of chronic sinusitis (Figure 2a)

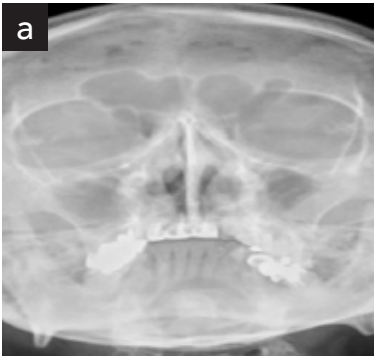

Bronchoscopy and bronchoalveolar lavage (BAL) fluid analysis (Figure 3a-3e)

- No vocal cord dysfunction, or airway distortion or obstruction

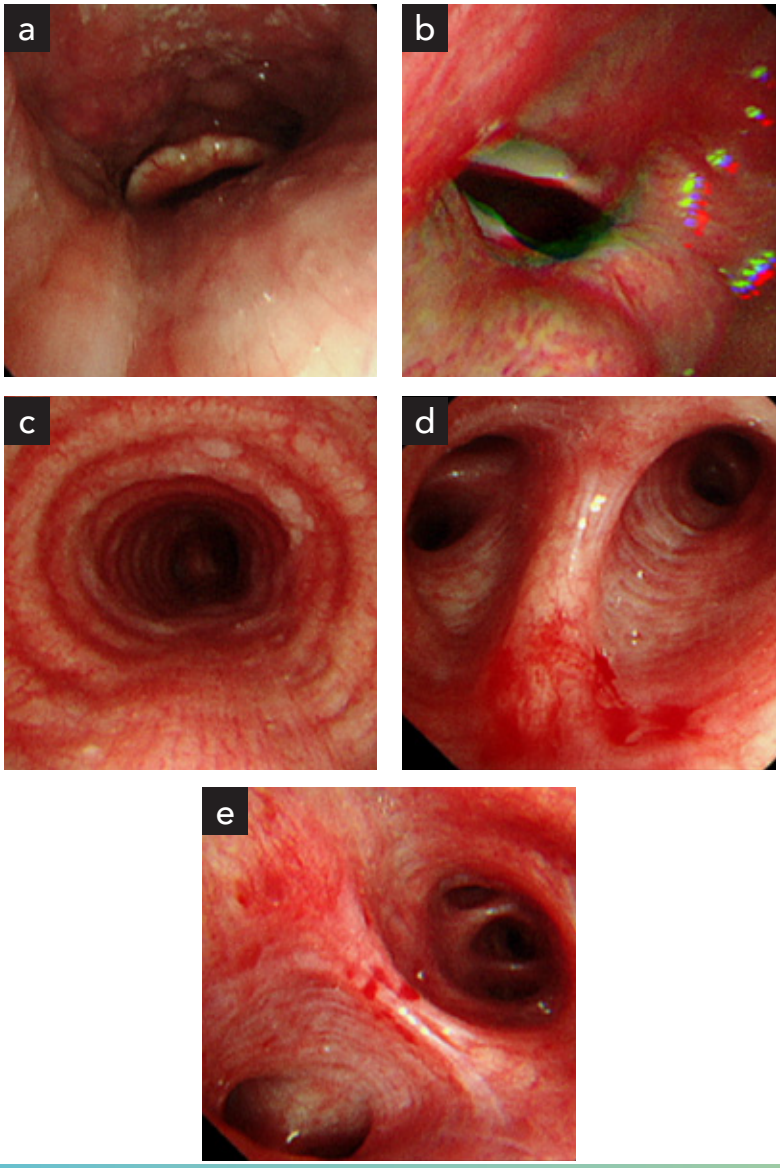

- BAL fluid cellular analysis

Cell type	Differential cell counts
Neutrophil	7%
Lymphocyte	12%
Eosinophil	11%
Mesothothelial cell +Histiocyte + Monocyte	70%

Assessment

Severe asthma was diagnosed based on

- Symptoms and PFT-confirmed asthma
- Review of inhaler technique and adherence
- Management of comorbidity (allergic rhinitis, nasal polyps, and sinusitis)
- Despite treatment with high-dose ICS/LABA, patient continued to experience poor symptom control

Severe neutrophilic asthma was characterized based on

- Increased neutrophil counts in BAL fluid
- Coexisting sinusitis and mild bronchiectasis
- Low lung function

Management and Clinical Course

- High-dose ICS/LABA
- Add-on low dose erythromycin with good clinical response and improvement of lung function
- Serial lung function

Date	FVC (L)	FVC (%pred)	FEV_1 (L)	FEV_1 (% pred)	FEV_1/FVC (%)
2017/06	2.07	61	1.38	48	67
2019/06	2.75	81	1.58	57	57

Clinical pearls

- Severe asthma is a heterogeneous disease and requires targeted treatment according to the inflammatory phenotype.
- Neutrophilic phenotype in severe asthma is defined as >40-60% neutrophils in induced sputum but without consensus definition in other specimens. ATS documents reported neutrophil in BAL cellular pattern in normal/healthy adult nonsmokers is ≤ 3%; therefore, neutrophilic inflammation was suspected in the present case (neutrophil in BAL, 7%)
- Clinical features of neutrophilic phenotype in asthma include poor lower lung function, poor response to inhaled glucocorticoid, purulent mucus production, and comorbid bronchiectasis. It is also characterized by increased rhinosinusitis with sleep disturbance and GERD. The possible causes and associated contributing factors are infections, sinusitis, smoking; exposure to irritants, pollutants, or occupational exposures; and glucocorticoid treatment.

- The outcomes of patients with severe asthma has improved in case of eosinophilic and T2-mediated inflammation with the advent of new biological agents. However, till date, there is no approved therapy for severe neutrophilic asthma.
- Macrolide therapy may be beneficial in neutrophilic asthma with low risk of complications, as indicated by few clinical trials and as demonstrated in the present case.

Abbreviation

Pre-BD, pre-bronchodilator; FVC, forced vital capacity; FEV_1, forced expiratory volume in 1 second; $FEF_{25\%-75\%}$, forced expiratory flow at 25-75% of the pulmonary volume

BRONCHIECTASIS AND SEVERE NEUTROPHILIC ASTHMA

Yi-Han Hsiao

Department of Chest Medicine, Taipei Veterans General Hospital, Taipei, Taiwan

Clinical presentation

- 55 year-old female
- Height: 154.8 cm, Weight: 56 kg, BMI: 23.3 kg/m^2
- Occupation: business woman, office worker
- Asthma diagnosed on pulmonary function tests at a medical center
- Regular use of high dose (HD) ICS/LABA plus tiotropium:
  - ◈ Seretide (25/250 mcg salmeterol/fluticasone propionate) Evohaler 2 puffs BID
  - ◈ Spiriva (2.5 mcg tiotropium bromide) Respimat 2 puff QD
  - ◈ Singular (10 mg montelukast) 1 tab HS
  - ◈ Xathium (200 mg theophylline) 1 cap HS
- Still has persisted exertional dyspnea and chest tightness for the last 6 months
- ACT: 18
- History of severe acute exacerbation of asthma requiring admission in November, 2017, status post antibiotics and systemic steroid. Thereafter, she has two exacerbations requiring oral corticosteroids in February and November 2018.
- Physical exam: no clubbing of the fingers, bilateral vesicular breathing, no wheezing

Evaluation

<u>Modifiable risk factors</u>

- Medication: correct inhaler technique & good adherence with controller therapy
- No history of drug allergies or aspirin- or NSAID-induced exacerbations
- Exposure: never smoked, no pets, no seasonal or event-related exacerbations

Co-morbidities

- Insignificant coronary artery disease (CAD)
  - Coronary angiography in November 2017: left circumflex artery, LCX 30–40% stenosis
- Gastroesophageal reflux disease (GERD): LA grade A
  - Using a proton pump inhibitor (PPI)
- Allergic rhinitis
  - Using a nasal corticosteroid spray
- Bronchiectasis (+)
- No history of chronic rhinosinusitis, nasal polyposis, vocal cord dysfunction, OSAS, dysfunctional breathing, excessive central airway collapse, obesity, underweight, chronic obstructive pulmonary disease(COPD),allergic bronchopulmonary aspergillosis(ABPA), eosinophilic granulomatosis with polyangiitis(EGPA), social deprivation, anxiety, depression, or schizophrenia

Lung function tests

Parameter	Values		
2018/09	Pre-BD	Post-BD	%Change
FVC (%pred)	53%	61%	15%
FEV_1 (%pred)	28%	30%	11%
FEV_1/FVC (%)	42%	41%	-
$FEF_{50\%}$(%pred)	6%	7%	-

Laboratory tests

- Blood eosinophils: 2.6% (200/μL), Eosinophil cationic protein (ECP): 20.1 μg/L (no OCS use for at least 4 weeks)
- Total IgE: 29 IU/mL
- Allergen test (panel I, II): negative
- Echocardiogram: LVEF 64%, normal RVSP
- Sputum culture: Normal pharyngeal flora

Imaging studies

- Chest radiograph and CT scans
  - Chest X ray (left panel) and chest CT (right panel) showed bronchiectasis over bilateral lower lung fields and the presence of mosaic attenuation in both lung fields; thus, an inflammatory process is firstly considered (Figure 1a-1c)

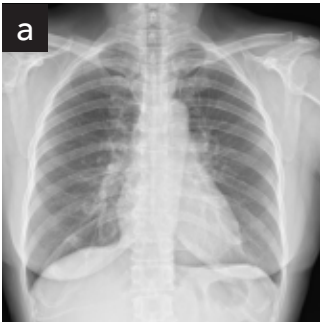

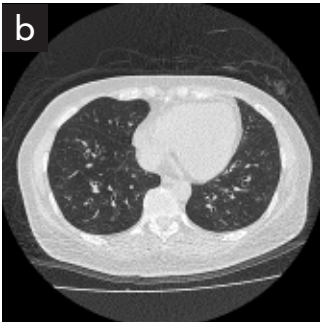

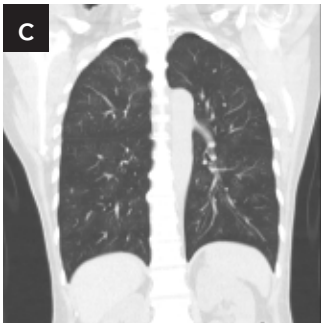

- WATER's view: Increased radiopacity of the left maxillary sinus without a definite air-fluid level (Figure 2a)

- Sinus CT: Mild effusion (arrow) in left maxillary sinus (Figure 3a-3b)

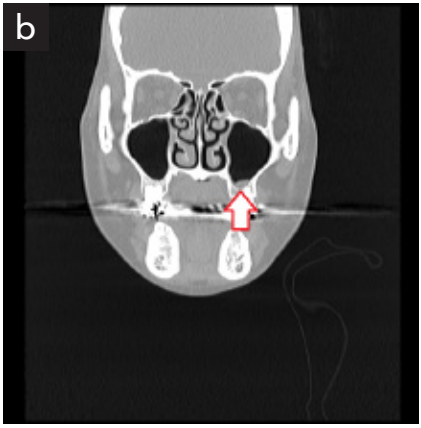

Bronchoscopy and bronchoalveolar lavage (BAL) analysis (Figure 4a-4d)

- No vocal cord dysfunction, airway distortion, or endobronchial lesions
- Large amounts of mucoid secretions over the trachea and bilateral bronchial trees
- Oozing over left lingual division (LLD) and right middle lobe (RML) orifices easily developed on contact

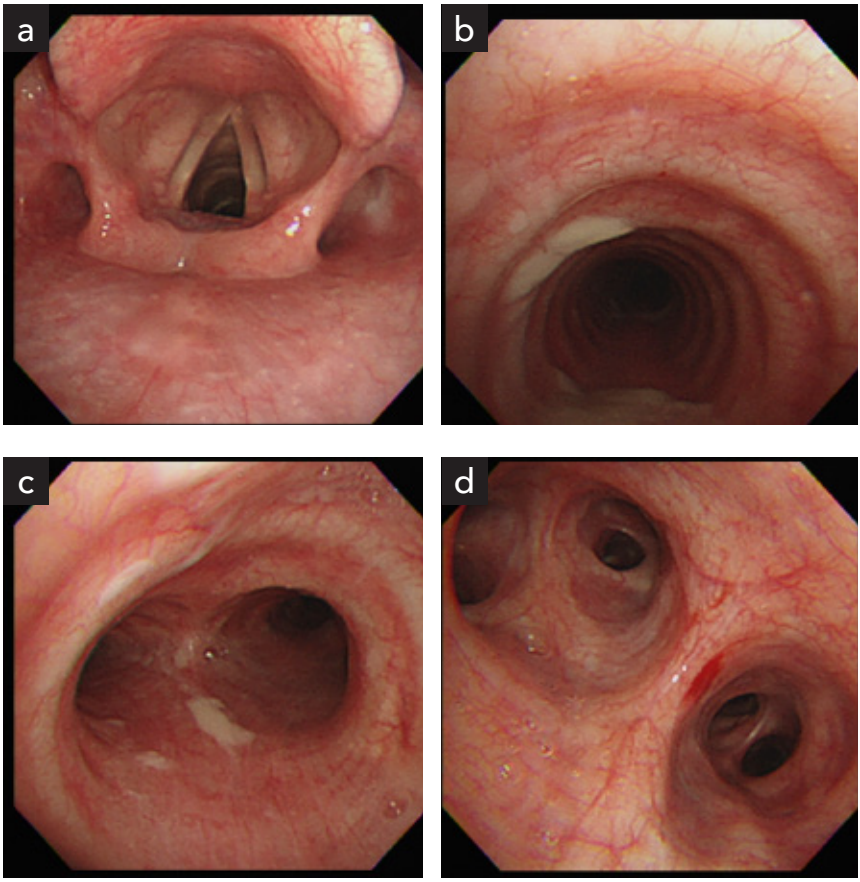

- BAL fluid analysis from LLD showed the following (Figure 5a-5d):
  - normal macrophage distribution with a predominantly neutrophil infiltration (arrows). No lymphocytosis.
  - BAL culture (-), Acid fast stain (AFS) (-), fungus culture (-), TB culture: non-tuberculosis mycobacterium (NTM) likely to be colonization due to the absence of fever/hemoptysis/weight loss

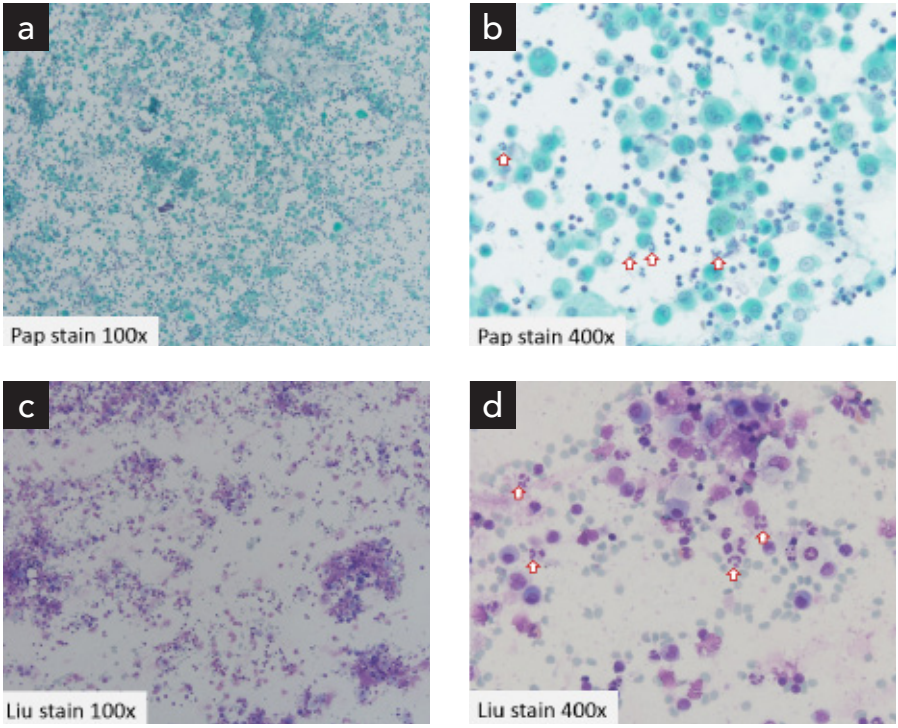

Assessmnt

Severe asthma was diagnosed based on the following

- Uncontrolled asthma
  - The diagnosis of asthma confirmed by our specialists in a multidisciplinary discussion (MDD) meeting, based on her typical respiratory symptoms and variable expiratory airflow limitation (positive bronchial reversibility)
  - Poor symptom control (ACT <20)
  - Frequent acute exacerbations (AEs) of asthma (2 AEs in 2018 requiring OCS, and 1 severe AE requiring admission)
- Difficult-to-treat asthma
  - Uncontrolled despite GINA step 5 (HD ICS/LABA plus tiotropium)
- Severe asthma:
  - Modifiable factors addressed and managed including inhaler technique, adherence, smoking status, and comorbidities.
  - Uncontrolled despite adherence to maximal optimized medical therapy and treatment of contributory factors for 6 months.

Severe neutrophilic asthma was characterized based on the following

- BAL fluid showed neutrophil predominant infiltration
- Coexisting sinusitis and bronchiectasis
- Poor lung function

Management and Clinical Course

- Macrolide treatment with azithromycin 250 mg BID TIW[2, 3]

- Chest physiotherapy and aerosol therapy for sputum clearance
- Nutrition support and pulmonary rehabilitation for dyspnea
- Symptoms improved after 3 months of treatment with no further exacerbation requiring systemic steroids or antibiotics.
- Serial lung function

Date	ACT	FVC (L)	FVC (%pred)	FEV_1 (L)	FEV_1 (% pred)	FEV_1/FVC (%)
2018/09	18	1.65	61	0.67	30	41
2019/02	23	1.20	44	0.51	23	42
2019/09	21	1.17	44	0.52	24	44

- However, a progressive decline was seen on the PFTs, and the patient underwent lung transplantation evaluation for her severe obstructive lung disease in October 2019 after discussion in our MDD meeting

Clinical pearls

- This is a case of severe neutrophilic asthma diagnosed by current guidelines and BAL fluid examination
- Bronchoscopic evaluation, including bronchial biopsy and BAL, provides important information on the type of inflammation and helps identify the phenotypes of refractory asthma in order to administer phenotype-specific treatment [4-6]
- Approximately 20–30% of patients with severe or uncontrolled asthma are found to have radiological bronchiectasis on CT. It is frequently considered to be a consequence of long-standing, severe, uncontrolled asthma[7]
- The co-diagnosis of bronchiectasis with asthma is associated with increased lung inflammation, frequent exacerbations, more severe airway obstruction, and advanced age

Moreover, these patients have a poorer response to asthma treatment and often require a therapeutic approach typically for bronchiectasis (long-term antibiotics, chest physiotherapy) [8]

- Macrolides may have some benefits in both severe neutrophilic asthma and bronchiectasis
- Lung transplantation should be considered based on her relatively young age and the progressive decline in lung function despite comprehensive medical treatment

Abbreviation

Pre-BD, pre-bronchodilator; FVC, forced vital capacity; FEV_1, forced expiratory volume in 1 second; $FEF_{25\%-75\%}$, forced expiratory flow at 25-75% of the pulmonary volume

References

1.https://ginasthma.org/wp-content/uploads/2019/04/GINA-Severe-asthma-Pocket-Guide-v2.0-wms-1.pdf
2.Holguin F, Cardet JC, Chung KF, Diver S, Ferreira DS, Fitzpatrick A, Gaga M, Kellermeyer L, Khurana S, Knight S, McDonald VM. Management of severe asthma: a European Respiratory Society/American Thoracic Society guideline. Eur Respir J. 2020 Jan 1;55(1).
3.Gibson PG, Yang IA, Upham JW, Reynolds PN, Hodge S, James AL, Jenkins C, Peters MJ, Marks GB, Baraket M, Powell H, Taylor SL, Leong LEX, Rogers GB, Simpson JL. Effect of azithromycin on asthma exacerbations and quality of life in adults with persistent uncontrolled asthma (AMAZES): a randomised, double-blind, placebo-controlled trial. Lancet. 2017 Aug 12;390(10095):659-668.
4.Smith DL, Deshazo RD. Bronchoalveolar lavage in asthma. An update and perspective. Am Rev Respir Dis. 1993 Aug;148(2):523-532.
5.Good JT Jr, Kolakowski CA, Groshong SD, Murphy JR, Martin RJ. Refractory asthma: importance of bronchoscopy to identify phenotypes and direct therapy. Chest. 2012 Mar;141(3):599-606.
6.Doberer D, Trejo Bittar HE, Wenzel SE. Should lung biopsies be performed in patients with severe asthma? Eur Respir Rev. 2015 Sep;24(137):525-539.
7.Polverino E, Dimakou K, Hurst J, Martinez-Garcia MA, Miravitlles M, Paggiaro P, Shteinberg M, Aliberti S, Chalmers JD. The overlap between bronchiectasis and chronic airway diseases: state of the art and future directions. Eur Respir J. 2018 Sep 15;52(3).
8.Porsbjerg C, Menzies-Gow A. Co-morbidities in severe asthma: Clinical impact and management. Respirology. 2017 May;22(4):651-661.

SEVERE ASTHMA CASEBOOK
嚴重氣喘案例集

發行單位：台灣胸腔暨重症加護醫學會
地址：10045 台北市中正區重慶南路 1 段 57 號 6 樓之 3
電話：02-2314-4089
傳真：02-2314-1289
網址：www.tspccm.org.tw

發行人：林孟志
顧問：王鶴健
總編輯：許超群
編輯委員：許超群、詹明澄、柯信國、林聖皓、林慶雄、鄭世隆、李岡遠、林鴻銓
撰寫人：沈聲燁、陳冠元、張博瑞、黃偉彰、林慶雄、鄭世隆、潘奕宏、陳家弘、黃建文、李岡遠、蕭逸函（依章節順序排列）

出版單位：臻呈文化行銷有限公司
地址：10654 台北市大安區忠孝東路三段 249-1 號 10 樓
電話：02-2778-7711
傳真：02-2778-7755
網址： www.crossroad.com.tw
出版日期：西元 2020 年 06 月　初版

ISBN:978-986-99108-1-1

電子書下載點

ISBN 978-986-99108-1-1

台灣胸腔暨重症加護醫學會

Taiwan Society of Pulmonary and Critical Care Medicine

NOVARTIS 台灣諾華股份有限公司 助印 荷商葛蘭素史克藥廠股份有限公司 助印