Manual of Contrast-enhanced Endoscopic Ultrasound

內視鏡超音波顯影劑應用手冊 初版

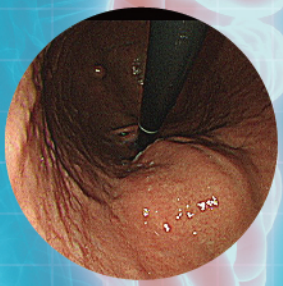

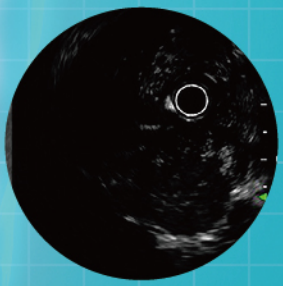

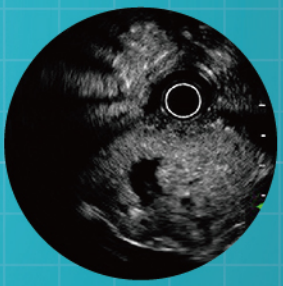

主編・王秀伯

Manual of Contrast-enhanced Endoscopic Ultrasound

內視鏡超音波顯影劑應用手冊 初版

Table of Content

- **內視鏡超音波顯影劑造影術之判讀** *2*
- **Gastric Leiomyoma** *12*
- **Gastric GIST** *15*
- **Pancreatic Adenocacinoma** *19*
- **Pancreatic NET** *25*

主編 / 王秀伯 台大醫院

作者 / 郭雨庭 台大醫院

戎伯岩 台大醫院

張為淵 台大醫院

顯影劑造影判讀的四大重點

觀察不同時間點的顯影變化	顯影 (Enhancement pattern)	顯影分佈 (Enhancement distribution)	血管型態 (Vascular pattern)
• 動脈相 • 門靜脈相 • 延遲血管相 • 庫柏氏相	• 無顯影 • 低顯影 • 等顯影 • 高顯影	• 均一性 • 不均一性	• 規則血管 • 不規則血管 • 無血管

觀察不同時間點的顯影變化

- 動脈相 (Artery Phase): 約 10-20 秒開始，結束時間約 30-45 秒
- 門靜脈相 (Portal Venous Phase): 約 30-45 秒開始，結束時間約 120 秒
- 延遲血管相 (Late Phase): 約 120 秒開始，結束時間約 4-6 分鐘
- 庫柏氏相 (Kupffer Phase): 10 分鐘後進入庫柏氏相觀察時間可達 1 小時

顯影 (Enhancement pattern)

- 無顯影 (No enhancement)

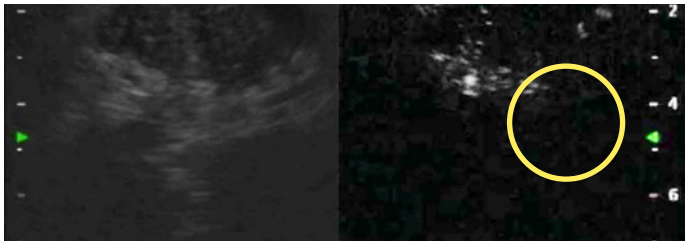

- 低顯影 (Hypo-enhancement)

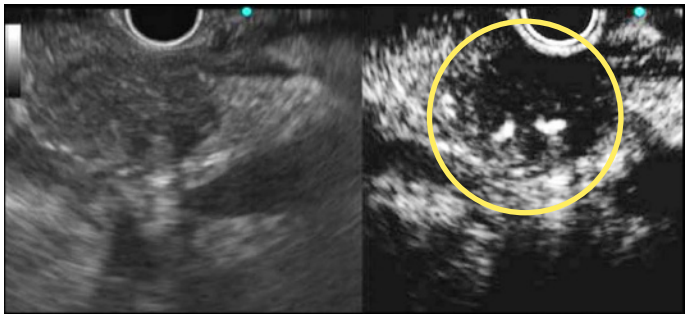

- 等顯影 (Iso-enhancement)

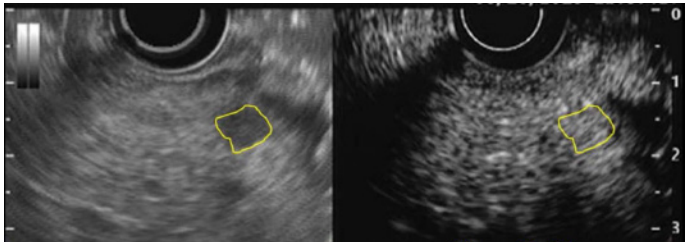

- 高顯影 (Hyper-enhancement)

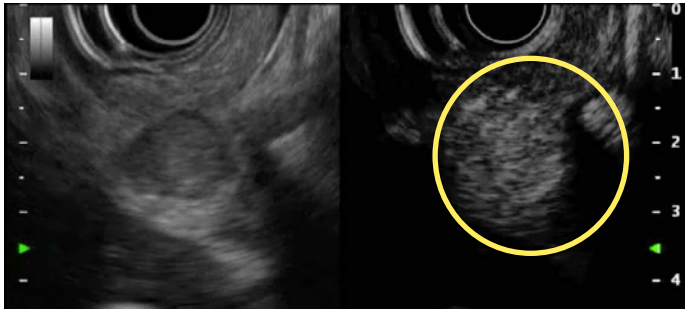

顯影分佈 (Enhancement distribution)

- 均一性顯影分佈 (Homogenous enhancement)

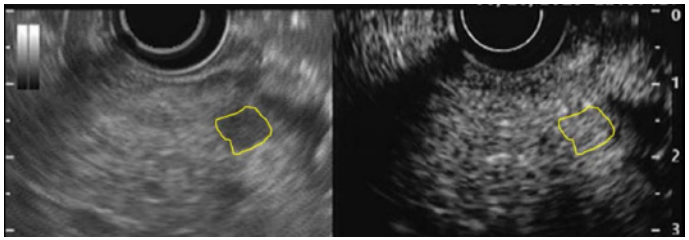

- 不均一性顯影分佈 (Heterogenous enhancement)

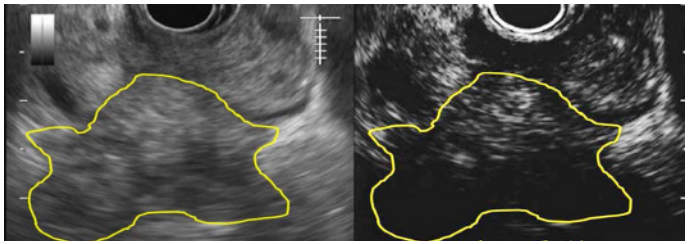

血管 (Vascular pattern)

- 規則血管 (Regular vessels)

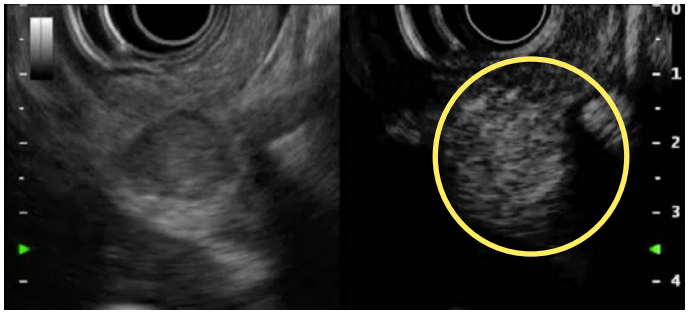

- 不規則血管 (Irregular vessels)

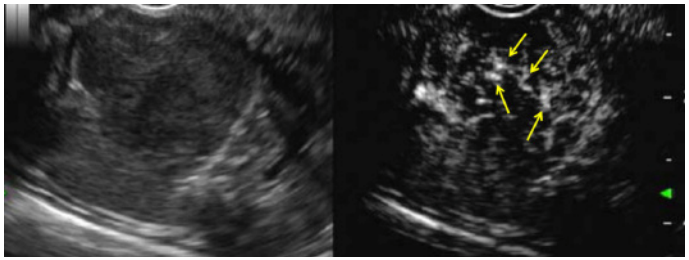

- 無血管 (No vessel)

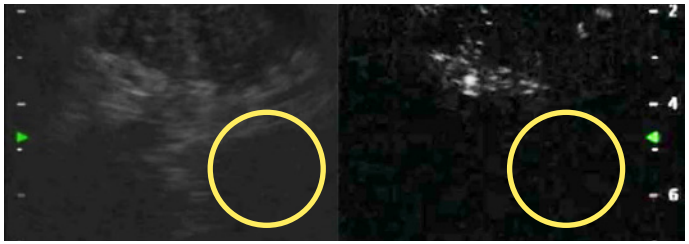

胰臟腫瘤
(Pancreatic tumor)

顯影劑的血管相變化	動脈相	門靜脈相
開始時間 結束時間	10-20 秒 30-45 秒	30-45 秒 120 秒
胰臟癌	無顯影 (No-enhancement) 	無顯影 (No-enhancement) 
自體免疫性胰臟炎 慢性胰臟炎造成的偽腫瘤	等顯影 (Iso-enhancement) 	等顯影 (Iso-enhancement) 
胰臟神經內分泌瘤 腎細胞癌轉移性胰臟腫瘤	高顯影 (Hyper-enhancement) 	高顯影 (Hyper-enhancement)

腸胃道粘膜下腫瘤
(GI tract subepithelial tumor)

顯影劑的血管相變化	動脈相	門靜脈相
開始時間 結束時間	10-20 秒 30-45 秒	30-45 秒 120 秒
平滑肌瘤	無 / 低顯影 (No/Hypo-enhancement) 	無 / 低顯影 (No/Hypo-enhancement) 
間質瘤 神經內分泌瘤	高顯影 (Hyper-enhancement) 	高顯影 (Hyper-enhancement)

肝臟腫瘤
(Liver tumor)

血管相變化	動脈相	門靜脈相	延遲血管相
開始時間 結束時間	10-20 秒 30-45 秒	30-45 秒 120 秒	120 秒 4-6 分鐘
良性肝腫瘤			
血管瘤	從週邊開始顯影 	由周圍向中心顯影 	全部呈現高顯影
局部節性增生 (Focal nodular hyperplasia)	由中心快速向周圍顯影 	高顯影但中間顯影缺損 	高顯影但中間顯影缺損 

血管相變化	動脈相	門靜脈相	延遲血管相
開始時間 結束時間	10-20 秒 30-45 秒	30-45 秒 120 秒	120 秒 4-6 分鐘
良性肝腫瘤			
肝細胞腺瘤 (Hepatocellular adenoma)	由周圍快速向中心顯影 	等顯影 	等顯影 

血管相變化	動脈相	門靜脈相	延遲血管相
開始時間 結束時間	10-20 秒 30-45 秒	30-45 秒 120 秒	120 秒 4-6 分鐘
惡性肝腫瘤			
肝癌	快速的高顯影 	顯影劑於 60 秒後開始廓清 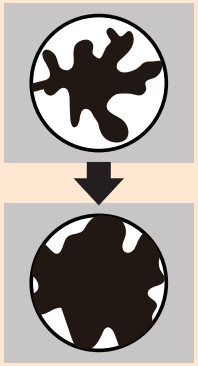	無 / 低顯影 
膽管癌	病兆的周圍開始顯影呈現高顯影 	顯影劑於 60 秒內快速廓清 (early washout) 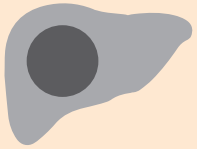	無 / 低顯影 
肝轉移性病兆 (腸胃道腺癌或鱗狀細胞癌轉移)	病兆的周圍開始顯影呈現高顯影 	顯影劑於 60 秒內快速廓清 (early washout) 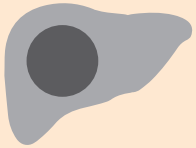	無 / 低顯影 
肝轉移性病兆 (神經內分泌瘤或腎細胞癌轉移)	高顯影 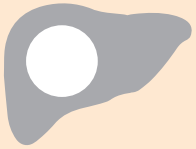	大多數仍呈現高顯影 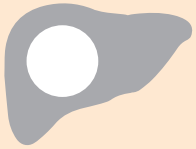	無 / 低顯影 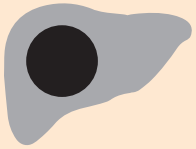

淋巴結 (Lymph node)

血管相變化	動脈相	門靜脈相
開始時間 結束時間	10-20 秒 30-45 秒	30-45 秒 120 秒
良性淋巴結	均一性由中心快速向周圍高顯影分佈 	等顯影 
惡性淋巴結	不均一性由周圍向中心周圍高顯影分佈 	顯影劑會開始不均一性的廓清 

47 years old woman suffered from epigastralgia. EGD presented a large gastric submucosal tumor at cardia (Fig 1).

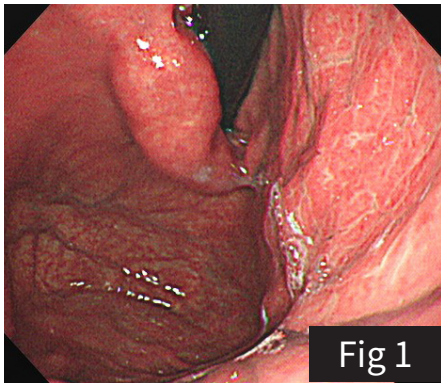
Fig 1

Laboratory data

All within normal range.

Conventional EUS study

A 4.8 cm hypoechoic tumor located at the 4th layer (Fig 2).

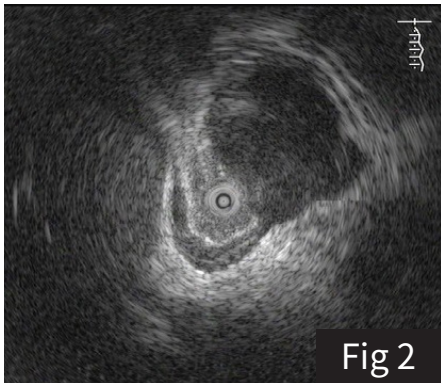
Fig 2

CEH- EUS (Sonazoid 0.5ml, MI 0.2)

The lesion showed hypo-enhancement pattern (Fig 3-1~3-3) .

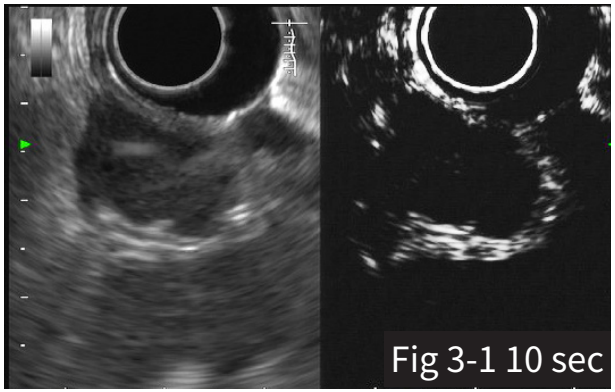
Fig 3-1 10 sec

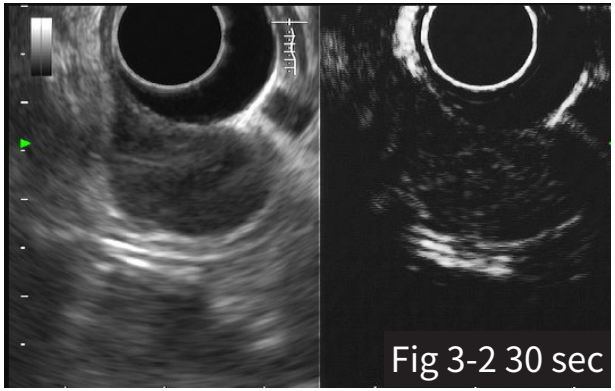
Fig 3-2 30 sec

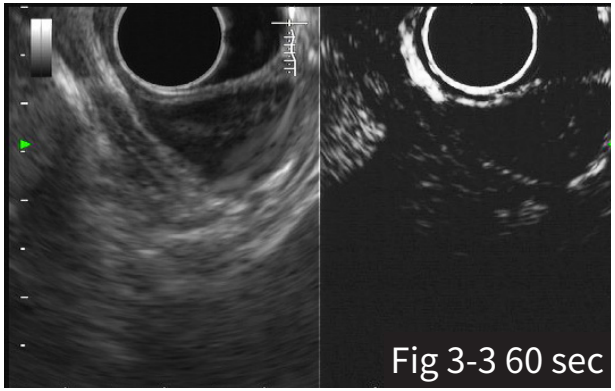
Fig 3-3 60 sec

Pathology

Leiomyoma :

A tumor composed of band-looking spindle-shaped cell with eosinophilic cytoplasm; desmin (+), CD117 (-) , Dog (-).

This 89 year-old woman suffered from epigastralgia. EGD showed a bulging mass with intact mucosa at lesser curvature of upper body (Fig 1).

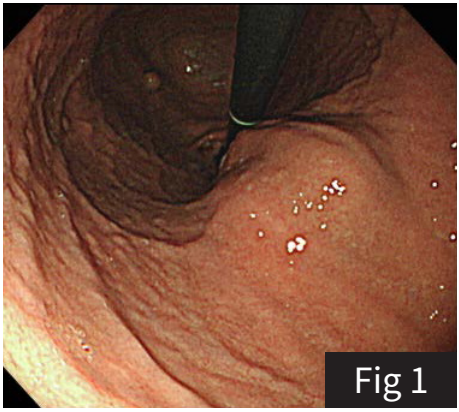
Fig 1

Laboratory data

All within normal range.

Conventional EUS study

A 4.8 cm hypoechoic tumor with anechoic components located at the 4th layer (Fig 2-1).

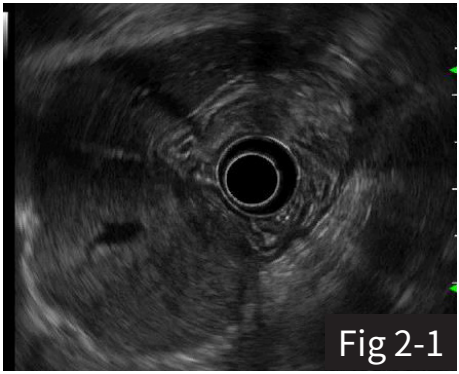
Fig 2-1

Doppler EUS showed increased doppler signals (Fig 2-2).

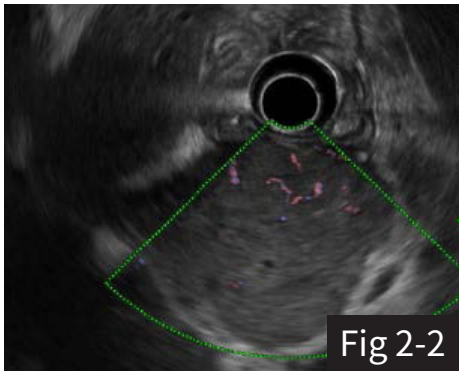

Fig 2-2

EUS elastography showed mosaic blue pattern (Fig 2-3).

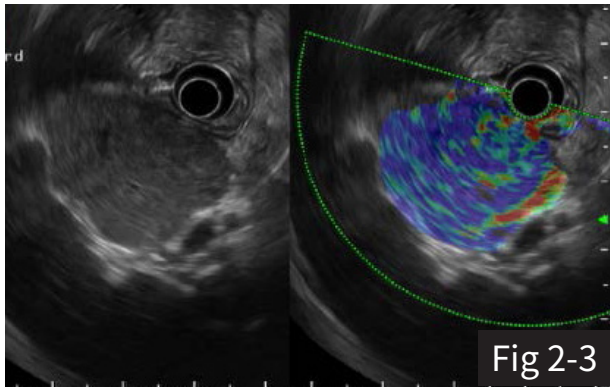

Fig 2-3

CEH- EUS
(Contrast agent: Sonazoid 0.5ml, MI 0.2)

The lesion showed hyper-enhancement with focal non-enhanced parts(Fig 3-1~3-3).

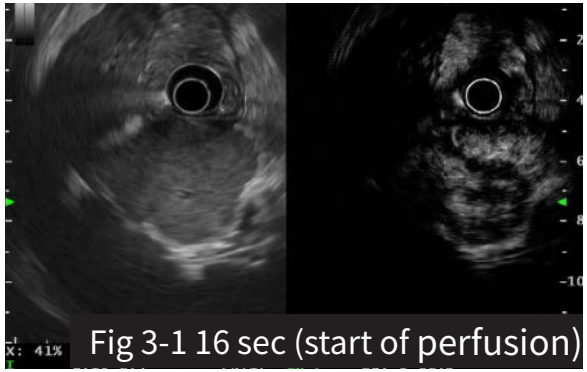

Fig 3-1 16 sec (start of perfusion)

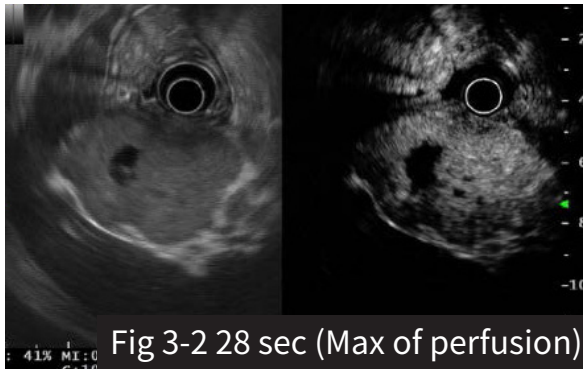

Fig 3-2 28 sec (Max of perfusion)

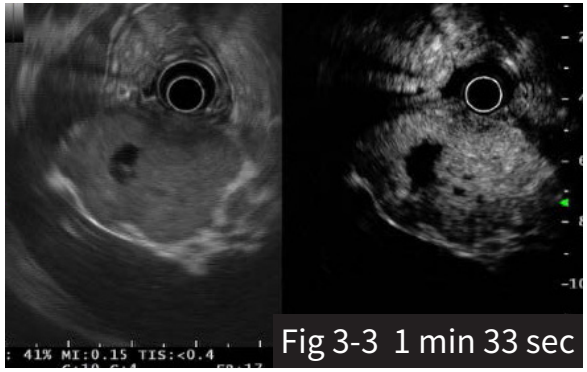

Fig 3-3 1 min 33 sec

Pathology

Gastrointestinal stromal tumor (GIST), prognostic group 2 : spindle cell tumor with whorl-like pattern; CD117 (+) , Dog (+).

A 58 years old man presented with protracted abdominal pain for 2 months, accompanied with weight loss.

Laboratory data

All within normal range including tumor markers.

Image

Abdominal ultrasound:

A hypoechoic lesion (Fig. 1-1, arrow) with encasement of celiac trunk and SMA (Fig.1-2) was noted at pancreatic body.

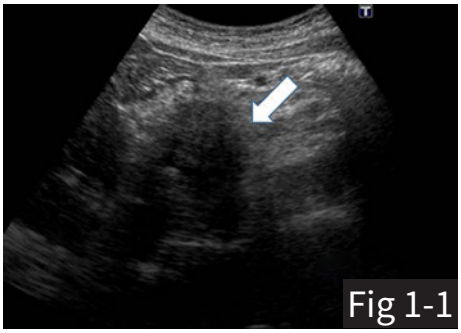

Fig 1-1

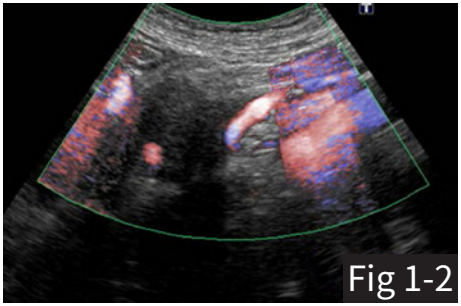

Fig 1-2

Contrast-enhanced CT:
A 5.4cm hypo-enhanced mass at the pancreatic body with celiac trunk in volvement (Fig 2, arrow).

Fig 2

Conventional EUS study

A 36.5mm hypoechoic tumor located at pancreatic neck (Fig 3-1, arrow); with upstream MPD dilatation (Fig 3-2, arrowhead).

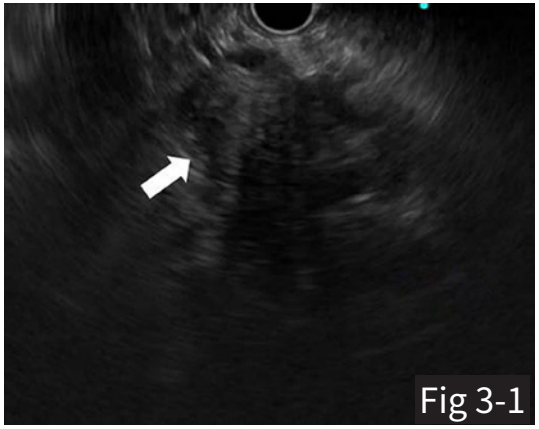
Fig 3-1

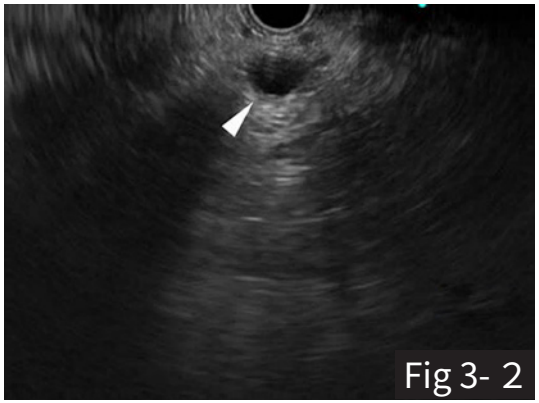
Fig 3- 2

Doppler EUS showed low vascularity(Fig 3-3).

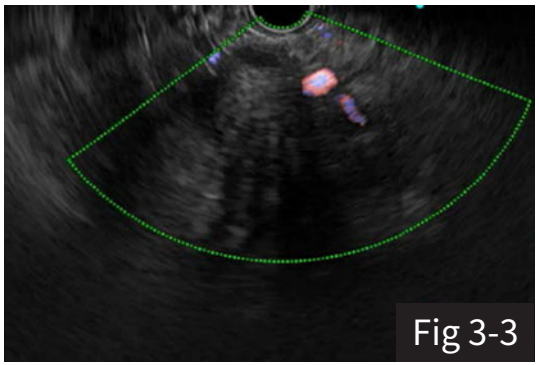
Fig 3-3

EUS elastography showed blue pattern (Fig 3-4).

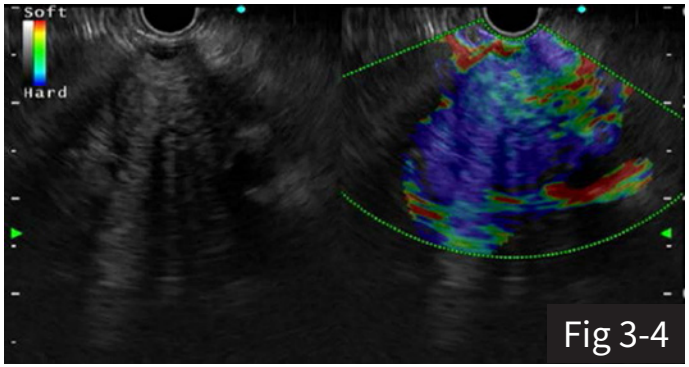

Fig 3-4

CEH-EUS
(Contrast agent: Sonazoid 0.5ml, MI 0.35)

Hypo-enhancement appearance (Fig4-1~4-4) :

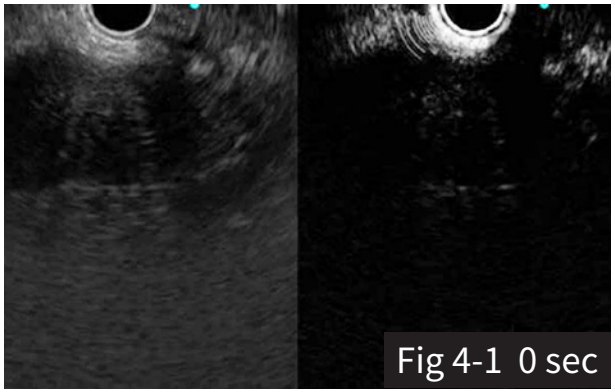

Fig 4-1 0 sec

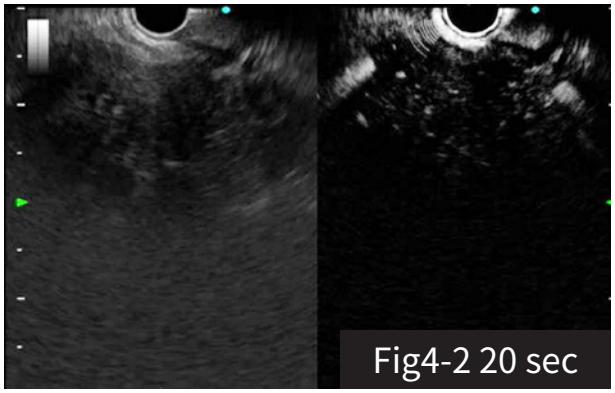

Fig4-2 20 sec

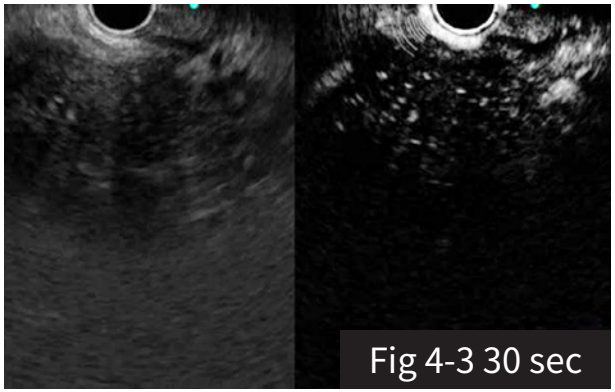

Fig 4-3 30 sec

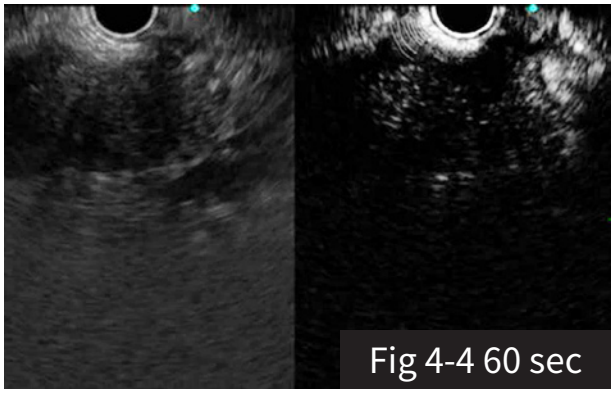

Fig 4-4 60 sec

EUS-FNB with Acquire 22G (Fig 5)

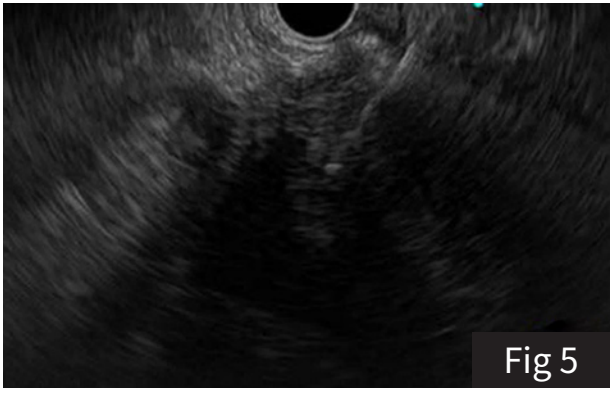

Pathology
Adenocarcinoma

A 53 years old woman presented with acute pancreatitis 3 weeks prior to admission. She did not have a history of choledocolithiasis or alcohol consumption.

Laboratory data

Elevated lipase level (215 U/L). Abnormal HbA1C level (7.1%) Tumor marker: normal.

Image

Abdominal ultrasound:

A hypoechoic lesions was noted at S 5/6 (Fig 1-1, arrow).

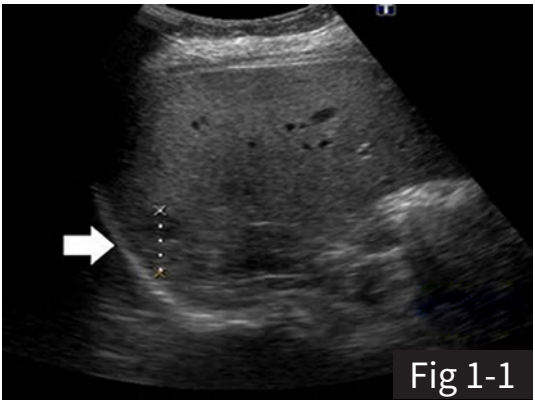

Fig 1-1

A 3.3*3.4*2.4cm hypoechoic tumor was noted at pancreatic head (Fig 1-2, arrow) with upstream MPD dilatation (Fig 1-3, arrow).

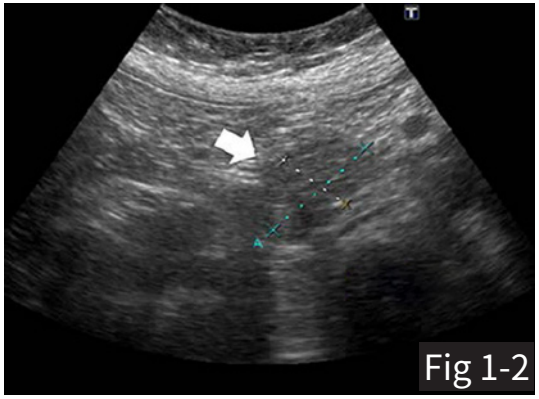
Fig 1-2

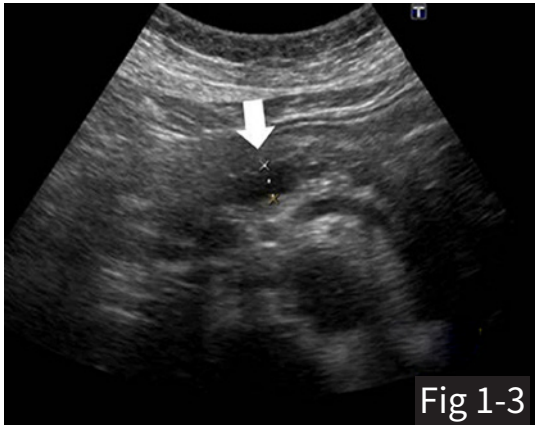
Fig 1-3

Contrast-enhanced CT:
A hypo-enhanced mass at right hepatic lobe, S5/6 (Fig 2-1, arrow).

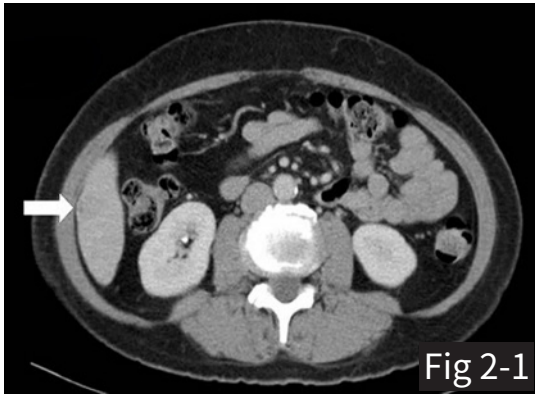
Fig 2-1

Presence of dilated main pancreatic duct and peri-pancreatic inflammation (Fig 2-2).

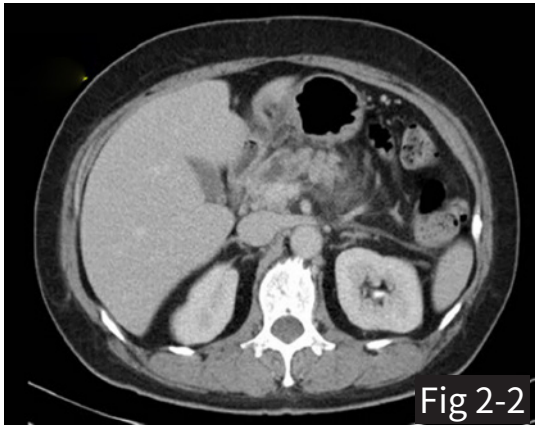
Fig 2-2

Conventional EUS study

A hypoechoic tumor was noted at pancreatic head (Fig 3-1, arrow) with upstream MPD dilatation (Fig 3-1, arrowhead). Doppler EUS did not increase in signals (Fig 3-2). EUS elastography showed mosaic blue predominant (Fig 3-3).

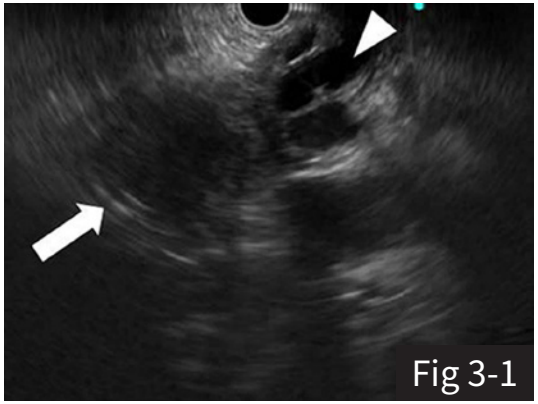

Fig 3-1

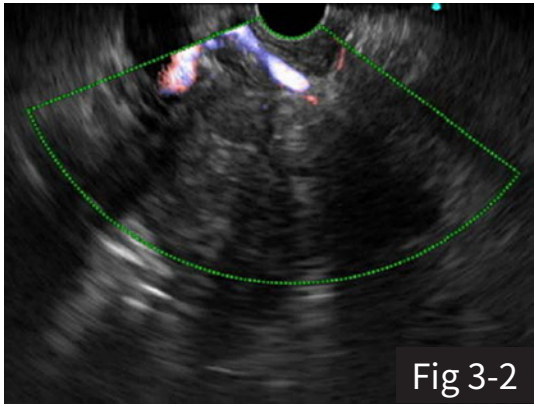

Fig 3-2

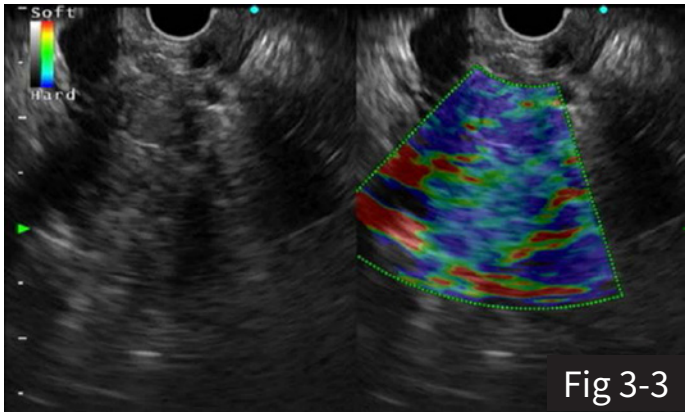

Fig 3-3

CEH- EUS
(Contrast agent: Sonazoid 0.5ml, MI 0.20)

Hyper-enhancement appearance(Fig 4-1~4-4).

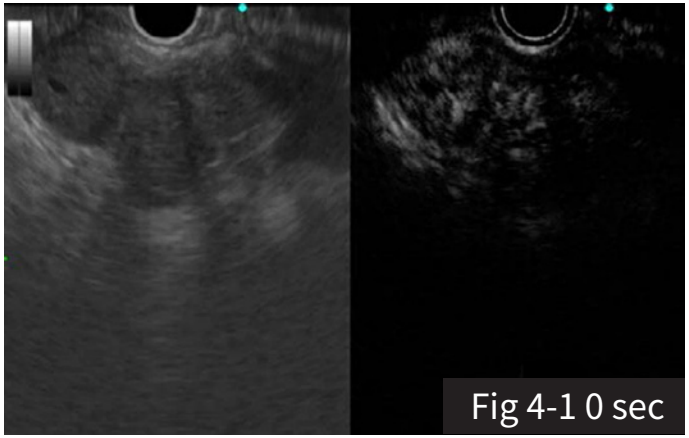

Fig 4-1 0 sec

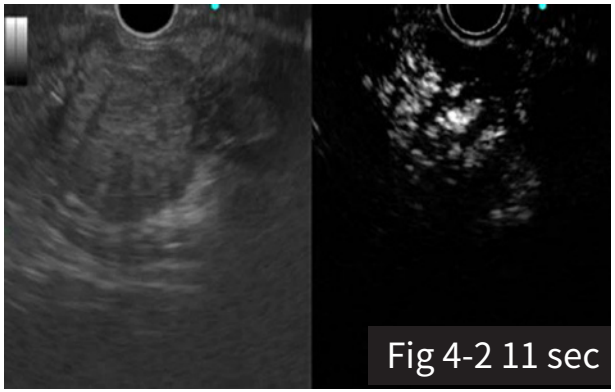
Fig 4-2 11 sec

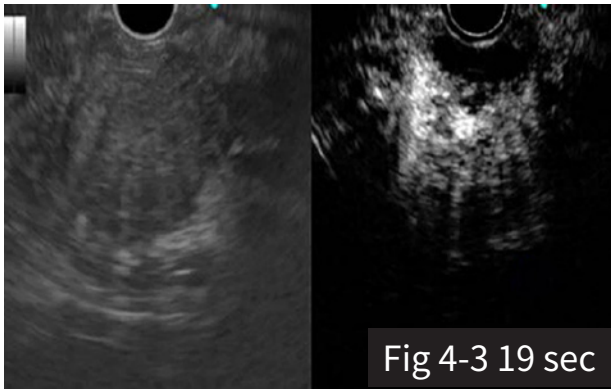
Fig 4-3 19 sec

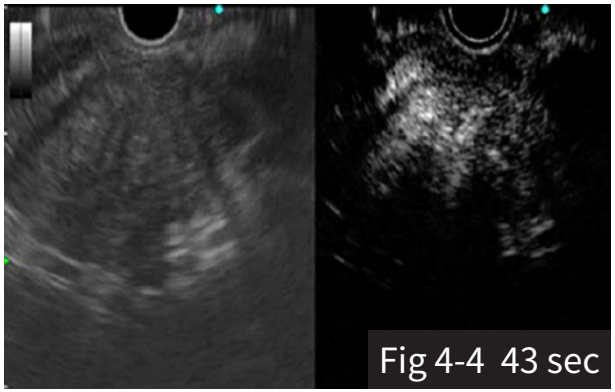
Fig 4-4 43 sec

Contrast guided EUS-FNB with Acquire 22G (Fig 5)

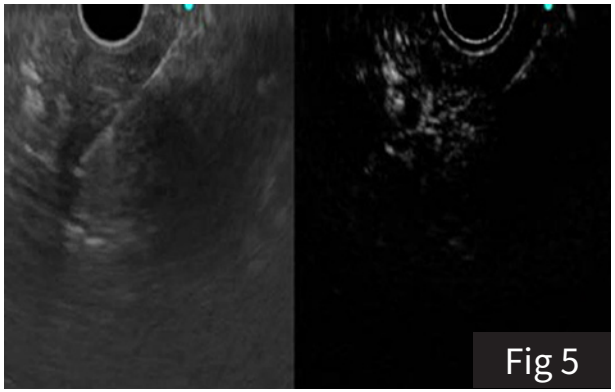
Fig 5

Pathology: Neuroendocrine Tumor, G2

Microscopically, it shows fragments of pancreatic tissue with aggregates of small blue round cells. The tumor cells are diffusely positive for synaptophysin and chromogranin. Ki-67 stains is up to 12% of tumor cell.

MEMO